

**DATE PRESENTING CLINICAL SIGNS**

8/3/23

Pet has a history of ITP of unknown origin. Did not respond well to pred alone. Addition of Atopica has helped once BID dosing was started and platelets now normal. Pet also has a history of idiopathic tail chewing and chewed of tip of tail about 2 months ago. Decreased appetite, Vomiting x 6 days. Symptoms seemed to start when pred was tapered down. Weight down 3 lb since last visit, No D/C/S, Not drinking,, hovering over water bowl, laying in tub. 5% dehydrated. QAR-depressed. Very tense on abdominal palpation. Only urinated twice yesterday and no bowel movements. Vomited 1 time despite being on Cerenia.

PATIENT

Snickers Altman

SPECIES

Feline

Current Medications: Cerenia 10mg-1 tablet by mouth once a day x 4 days, Atopica for cats 17 ml bottle-Give 0.2 ml by mouth every 12 hours for 3 months, Prednisolone 5mg-Give 2 tablets by mouth once a day since April, Fluoxetine 5mg sid x 6 months, Gabapentin 250mg/5ml 1 ml BID PRN
Lab Results: K+-3.3 (3.5-5.8), CL- 109 (112-129)

BREED

DSH

Date of Previous IntraPet Ultrasound: No previous.

Sedation: Not required to complete full diagnostic ultrasound.

Stat Report: Approved/Requested.

SEX

Imaging Performed By: Stephanie Warga RDCS, RVT.

Neutered Male

ULTRASONOGRAPHIC EXAMINATION OF THE ABDOMEN**AGE**

4/23/11

Urinary System

Urinary bladder is adequately distended. It has a normal uniform wall thickness. Contents include primarily anechoic fluid with a moderate to large amount of echogenic non-shadowing debris, which could be partially consistent with incidental suspended lipid in a cat, likely combined with exfoliated cells, mucous and/or small blood clots. Both sterile inflammation as well as urinary tract infection can also present with echogenic debris. No masses or cystoliths are observed. The trigone and visible pelvic urethra are normal in thickness with a smooth mucosal surface.

WEIGHT

12.52 Pounds

INTERPRETED BYBeth Johnson, DVM
DACVIM

The right kidney is normal in size (4.32 cm), shape and echogenicity. It has smooth peripheral margination. There is a normal 1:3 cortex to medulla ratio with appropriate corticomedullary distinction. There is no evidence of pyelectasia, mineral or infarcts observed.

HOSPITAL NAME

Fullerton AH

The left kidney is normal in size (4.45 cm), shape and echogenicity. It has smooth peripheral margination. There is a normal 1:3 cortex to medulla ratio with appropriate corticomedullary distinction. There is no evidence of pyelectasia, mineral or infarcts observed.

REFERRING VET

Dr. Unger

Adrenal Glands

The right adrenal gland is normal in size (0.47 cm), shape and contour. Corticomedullary structure is unremarkable. Visible surrounding vasculature appears normal.

INVOICE

44591

The left adrenal gland is normal in size (0.58 cm), shape and contour. Corticomedullary structure is unremarkable. Visible surrounding vasculature appears normal.

Spleen

The spleen is subjectively normal in size with a normal smooth capsular contour. Parenchyma is appropriately finely textured and homogenous with normal echogenicity relative to surrounding tissue (hyperechoic to liver). No focal nodules or masses are observed. Splenic vasculature appears normal.

Liver

The liver is subjectively normal in size with normal smooth curvilinear peripheral contour. Parenchyma is appropriately hypoechoic to the spleen in echogenicity and appropriately mildly coarse and homogenous in

echotexture. No focal lesions are observed. Visible vasculature and biliary tree appear normal without distension or congestion.

The gallbladder is non-distended in size. The wall is smooth without visible thickening. Luminal contents are primarily anechoic. There is no evidence of cystic or common bile duct dilation.

Gastrointestinal

The stomach wall is normal in thickness (canine < 0.5 cm and feline < 0.4 cm) and layering. The lumen of the stomach is mildly dilated with primarily fluid and echogenic non-shadowing luminal contents and gas, consistent with normal ingesta/chyme. However, there are small multifocal areas with some acoustic shadow that could represent foreign material.

The visible small intestines are normal in wall thickness and layering (canine duodenum < 0.5 cm and feline duodenum < 0.4 cm; other < 0.3 cm). Small intestinal motility appears adequate (1-3 contractions per min). The lumen of the cranial/proximal small bowel is mildly to moderately dilated with fluid and echogenic non-shadowing contents, consistent with ingesta/chyme leading up to a loop of presumably jejunum that contains a curvilinear echogenic density within the lumen and strong acoustic shadow. Beyond that, the lumen of the bowel returns to empty.

The visible colon is normal in wall thickness (< 0.2 cm) and layering. Contents are consistent with normal formed feces and gas.

Pancreas

The observed pancreas is prominent (enlarged) in size, hypoechoic to surrounding tissue and irregular in shape with a swollen undulating contour. Pancreatic duct dilation is noted. Enhanced hyperechoic ill-defined surrounding fat is noted. Both the left and right limbs appeared to be affected.

Free Abdomen

There is no evidence of free peritoneal effusion noted in these images.

The mesenteric lymph nodes are prominent in size with swollen capsular contour. Normal elongated shape (length to width ratio) is maintained. There is no loss of parenchymal detail.

ULTRASONOGRAPHIC FINDINGS

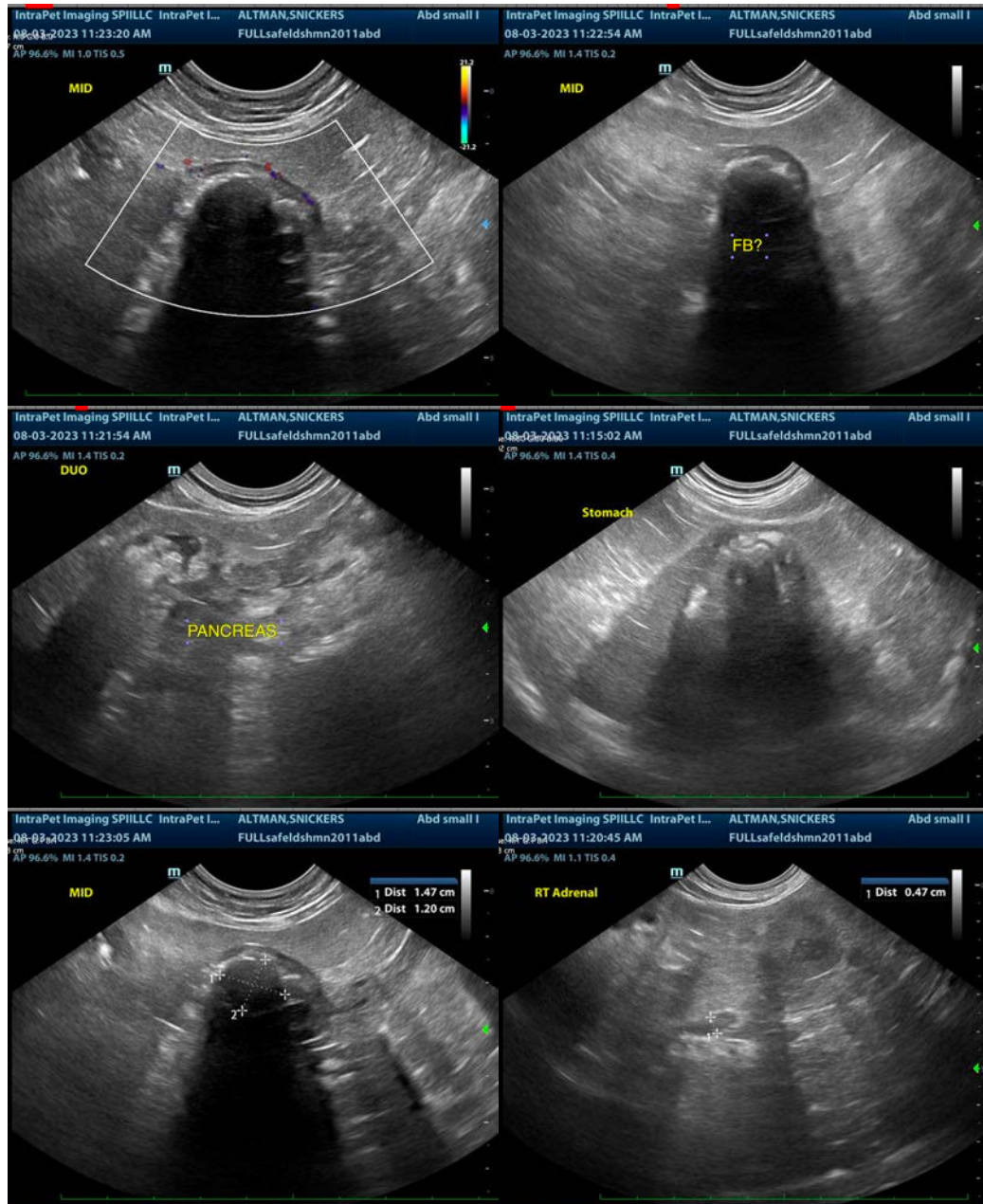
- Small bowel (suspect jejunal) foreign body with a classic obstructive pattern of dilated bowel leading up to the foreign body and empty normal bowel beyond it. Additionally, foreign material in the stomach can't be definitively ruled out.
- Mild or potentially emerging acute pancreatitis may be contributing to patient's clinical signs.
- Reactive mesenteric lymph nodes – infiltrative neoplastic disease cannot be ruled out but is considered less likely.
- Urinary bladder debris.

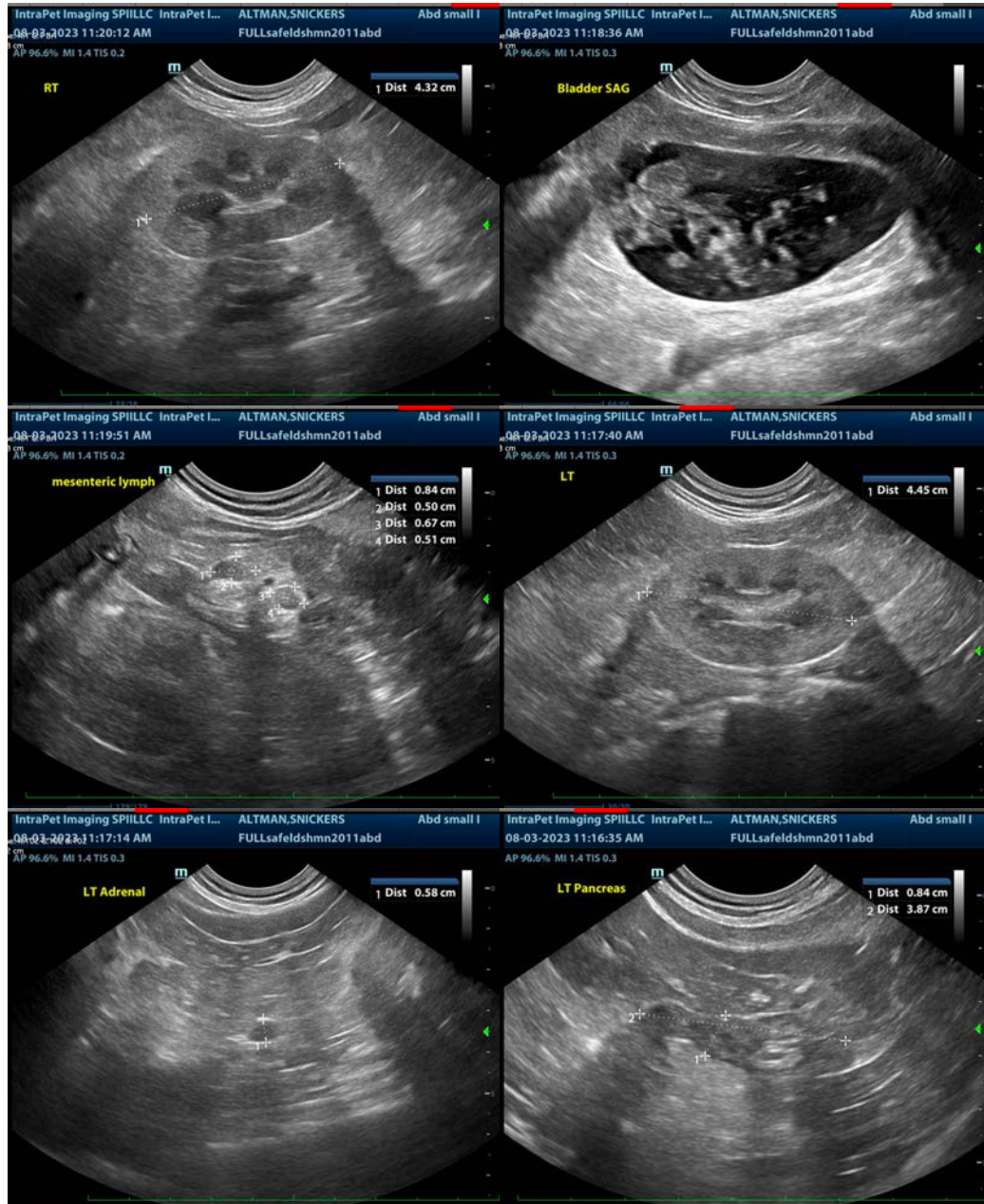
INTERPRETATION OF THE FINDINGS & FURTHER RECOMMENDATIONS

As soon as patient is stable enough to undergo surgery, an exploratory laparotomy for planned suspected foreign material localization and removal is recommended.

Following surgery, in addition to supportive normal routine post-op care, additionally supportive/symptomatic medical management for possible pancreatitis may be necessary.

If not recently evaluated, a urinalysis and, if indicated based on urinalysis results, urine culture are recommended. If protein is present in an otherwise quiet sediment, protein quantification with a urine protein to creatinine ratio is recommended.





The information and recommendations provided are based on the images presented by the referring veterinarian/sonographer. No evaluation can be communicated regarding pathology that was not visible in the image/video clips provided.

Thank you for this referral. If the clinical or image interpretation does not parallel your findings or if I can be of any further assistance please contact me.

Beth Johnson, DVM, DACVIM
 info@sonopath.com