**DATE PRESENTING CLINICAL SIGNS**

8/3/22

For the past month or so p has been leaking urine in his sleep. BW and Urine on 6/14/22 showed elevated creatine but not SDMA, urinary culture showed enterobacter. Treated w/enro but urinary problems did not resolve. BW/Urine sent out 7/18/22. Results pending.

**PATIENT**

Current Medications: None.

Indie Greb

Lab Results: 06/14/22 attached, creatine 1.8, USG 1.012, UA culture: Enterobacter with resistance.

Date of Previous IntraPet Ultrasound: No previous.

Sedation: Not required to complete full diagnostic ultrasound.

Stat Report: Not requested.

**SPECIES**

Imaging Performed By: Stephanie Warga RDCS, RVT.

Canine

**BREED**

Labrador

**SEX**

Neutered male

**AGE**

6/4/20

Prostate (neutered) is normal in size, echotexture and echogenicity for a neutered male.

**WEIGHT**

72.5 lbs

Left kidney is normal is size (6.81 cm), shape and echogenicity. It has smooth peripheral margination. There is a normal 1:3 cortex to medulla ratio with appropriate corticomedullary distinction. There is no evidence of pyelectasia, mineral or infarcts observed.

Right kidney is normal is size (6.01 cm), shape and echogenicity. It has smooth peripheral margination. There is a normal 1:3 cortex to medulla ratio with appropriate corticomedullary distinction. There is no evidence of pyelectasia, mineral or infarcts observed.

**INTERPRETED BY**

Beth Johnson, DVM  
DACVIM

**Adrenal Glands**

Left adrenal gland is normal in size (2.91 cm long, 0.47 cm at cranial pole and 0.59 cm at caudal pole), shape and overall architecture, echogenicity and echotexture. Visible surrounding vasculature appears normal.

Right adrenal gland is normal in size (3.04 cm long, 0.41 cm at cranial pole and 0.43 cm at caudal pole), shape and overall architecture, echogenicity and echotexture. Visible surrounding vasculature appears normal.

**HOSPITAL NAME**

Northwind AH

**REFERRING VET**

Dr. Jones

**Spleen**

Spleen is subjectively normal in size with a normal smooth capsular contour. Parenchyma is appropriately finely textured and homogenous with normal echogenicity relative to surrounding tissue (hyperechoic to liver). No focal nodules or masses are observed. Splenic vasculature appears normal.

**INVOICE**

32163

**Liver**

Liver is subjectively normal in size with normal smooth curvilinear peripheral contour. Parenchyma is appropriately hypoechoic to the spleen in echogenicity and appropriately mildly coarse and homogenous in echotexture. No focal lesions are observed. Visible vasculature and biliary tree appear normal without distension or congestion.

Gallbladder is non-distended in size. The wall is smooth without visible thickening. Luminal contents are primarily anechoic. There is no evidence of cystic or common bile duct dilation.

### ***Gastrointestinal***

The visible stomach wall is normal in thickness and layering. The lumen of the stomach is empty with no evidence of obstruction, foreign material or infiltrative disease. Pyloric outflow tract appears patent.

The visible small intestines are normal in wall thickness and layering. Small intestinal motility appears adequate (1-3 contractions per min). The lumen of the small intestine is empty with no evidence of obstruction, foreign material or infiltrative disease.

The visible colon is normal in wall thickness (< 0.2 cm) and layering. Contents are consistent with normal formed feces and gas.

### ***Pancreas***

The observed pancreas appears appropriately isoechoic to surrounding omental fat. Visible capsule is smooth and normal in contour. Visible pancreatic parenchyma is homogenous and unremarkable. There is no visible pancreatic duct dilation. There is no evidence of active peripancreatic inflammation.

### ***Free Abdomen***

There is no evidence of free peritoneal effusion noted in these images.

There is no apparent lymphadenopathy noted in these images.

## **ULTRASONOGRAPHIC FINDINGS**

### **Primary Findings**

- Unremarkable/normal abdomen with no ultrasonographically visible explanation for the reported urinary incontinence.

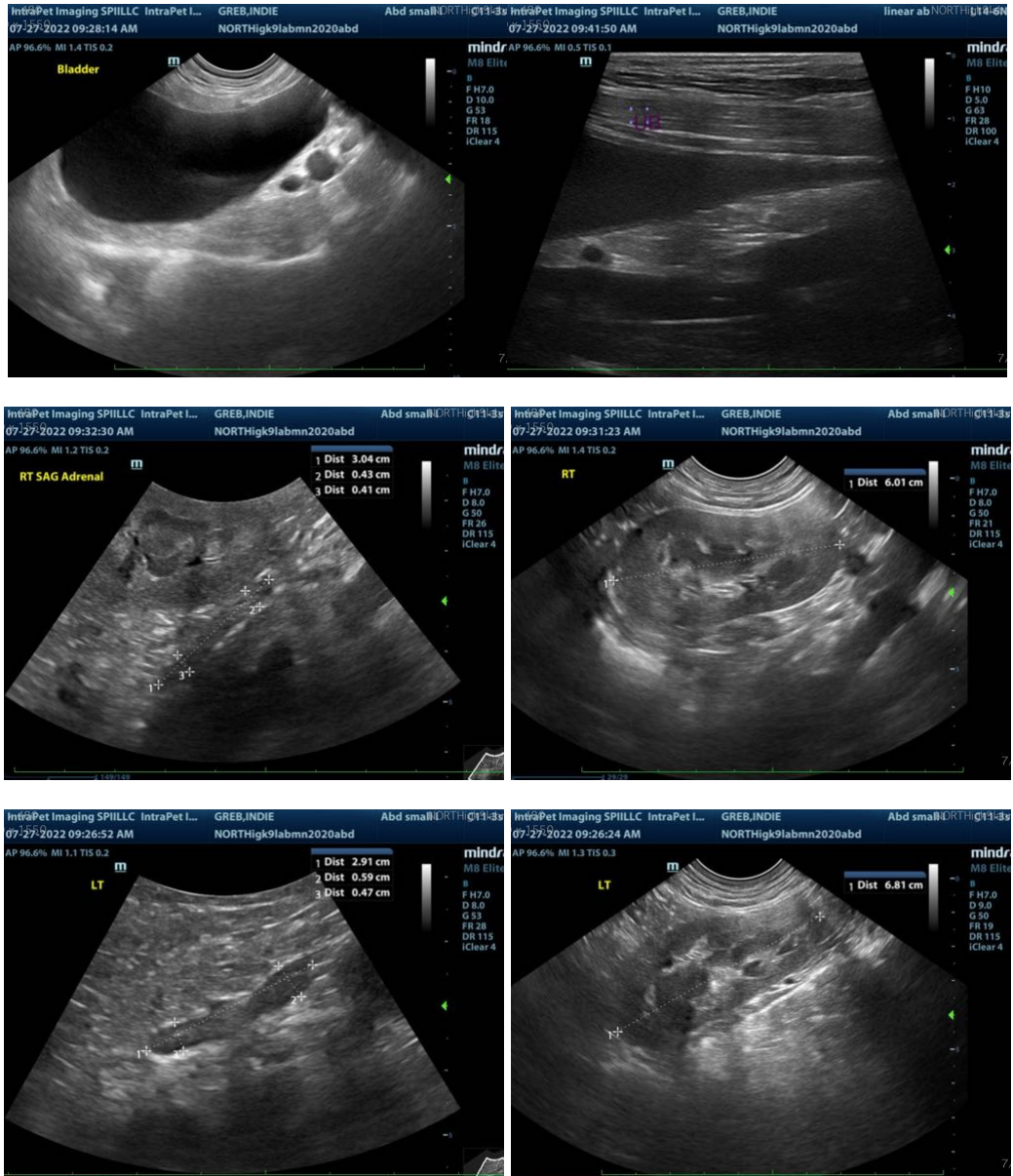
## **INTERPRETATION OF THE FINDINGS & FURTHER RECOMMENDATIONS**

There is no visible anatomical disorder in these images to describe the reported urinary incontinence. However, ectopic ureters cannot be definitively ruled out. Differentials for the urinary incontinence still include a non-visible, anatomic abnormality such as ectopic ureters versus bladder storage condition secondary to neurologic disease versus other or a urethral disorder such as urethral sphincter mechanism incompetence or detrusor urethral dyssynergy, etc. Given the patient's mildly increased creatinine and dilute urine the progression of previously subclinical urinary incontinence caused by new polyuria/polydipsia may also be present. Therefore, if PU/PD is present then I recommend a work-up of the PU/PD beginning with testing for Leptospirosis given the mildly increased creatinine.

A contrast abdominal CT scan or cystoscopy can be considered for further definitive rule out of ectopic ureters.

Pending results of the above recommendations a full neurologic evaluation/assessment is recommended at which time pending the results, medical management of either urethral sphincter mechanism incompetence or detrusor urethral dyssynergy could be considered.

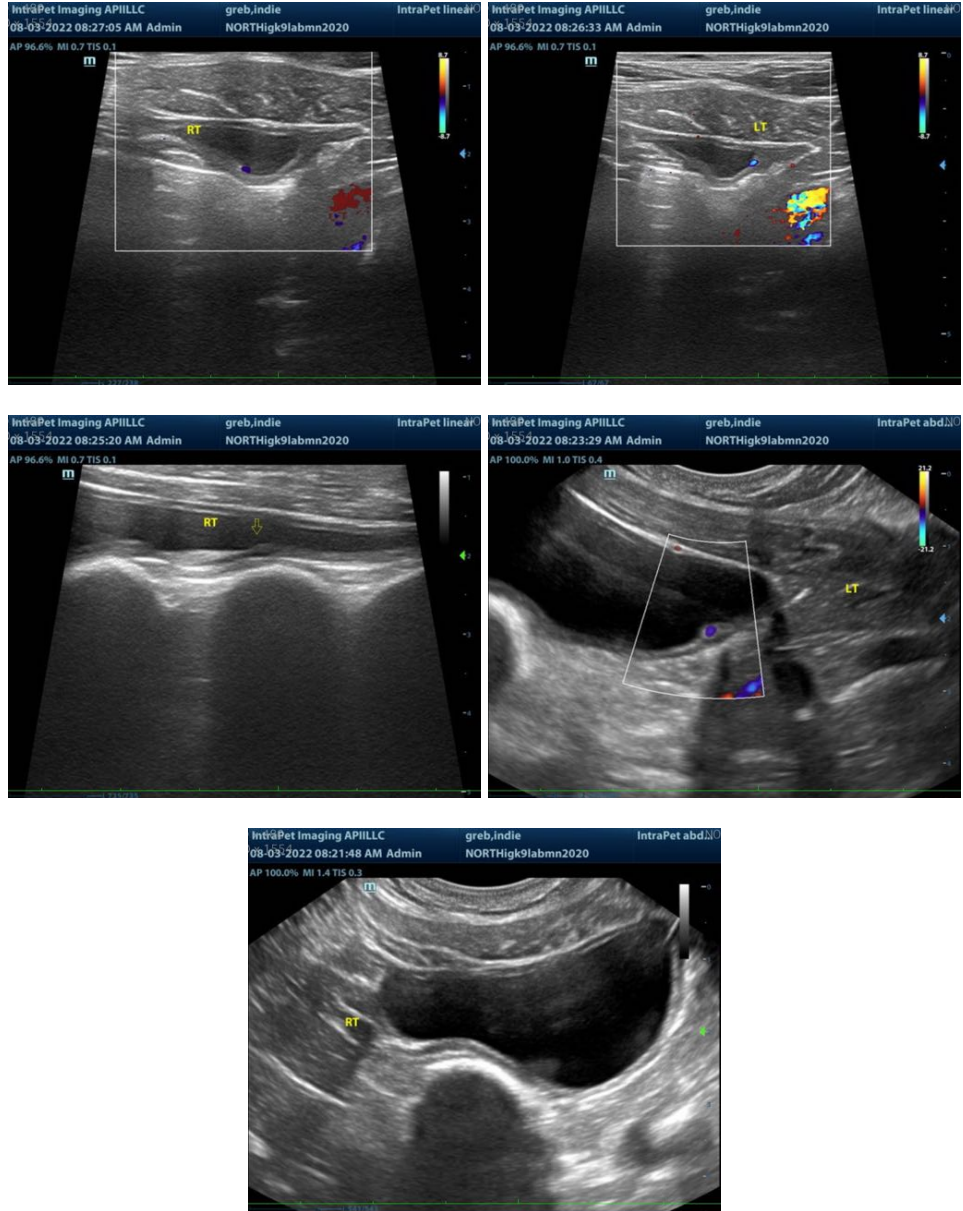
\*\*\*Sedation will be necessary to visualize the ureteral jet/ureteral papillae due to the patient's movement.



**Addendum 8/3/22**

The patient was fully sedated and both ureteral papilla were visualized and appear to be in the normal anatomic location. A right ureteral jet was not definitively visualized; however, left ureteral jet was visualized in the normal anatomic location. No ultrasonographically visible evidence of ectopic ureters present.

If ectopic ureters are still suspected clinically without another cause for the urinary incontinence advanced imaging in the form of a contrast abdominal CT scan is recommended to definitively rule out ectopic ureters. Alternatively cystoscopy could be considered.



The information and recommendations provided are based on the images presented by the referring veterinarian. No evaluation can be communicated regarding pathology that was not visible in the image/video clips provided.

Thank you for this referral. If the clinical or image interpretation does not parallel your findings or if I can be of any further assistance please contact me.

**Beth Johnson, DVM DACVIM**  
Beth.Johnson@SonoPath.com