

**PATIENT**

Abby Hieb

SPECIES

Canine

BREED

Lab

SEX

Spayed Female

AGE

4 Years

WEIGHT

77 Pounds

INTERPRETED BYBeth Johnson, DVM
DACVIM**IMAGING PERFORMED BY**

Amy Mayhew, LVT

HOSPITAL NAME

SVS Imaging MI

REFERRING VET

Briarwood VH

INVOICE

40151

DATE

8/3/22

PRESENTING CLINICAL SIGNS

Not eating/drinking, lethargic. Previously had surgery for ectopic ureters, on incurin - doesn't help
 Abnormal PE/Chem/CBC/UA Results: Fever of unknown origin, chest and abdominal radiographs wnl. Please see attached labs.

ULTRASONOGRAPHIC EXAMINATION OF THE ABDOMEN**Urinary System**

The urinary bladder is moderately distended with anechoic contents. No masses, inflammatory changes, echogenic sediment or cystoliths are observed. The urinary bladder, trigone and visible pelvic urethra are normal in thickness with a smooth mucosal surface.

The right kidney is normal in size (8.55 cm), shape and echogenicity. It has smooth peripheral margination. There is a normal 1:3 cortex to medulla ratio with appropriate corticomedullary distinction. There is no evidence of pyelectasia, mineral or infarcts observed.

The left kidney is normal in size (7.56 cm), shape and echogenicity. It has smooth peripheral margination. There is a normal 1:3 cortex to medulla ratio with appropriate corticomedullary distinction. There is no evidence of pyelectasia, mineral or infarcts observed.

Adrenal Glands

The right adrenal gland is normal in size (0.64 cm at the cranial pole and 0.73 cm at the caudal pole), shape and contour. Corticomedullary structure is unremarkable. Visible surrounding vasculature appears normal.

The left adrenal gland is normal in size (0.73 cm at the cranial pole and 0.83 cm at the caudal pole), shape and contour. Corticomedullary structure is unremarkable. Visible surrounding vasculature appears normal.

Spleen

The spleen is subjectively normal in size with a normal smooth capsular contour. Parenchyma is appropriately finely textured and homogenous with normal echogenicity relative to surrounding tissue (hyperechoic to liver). No focal nodules or masses are observed. Splenic vasculature appears normal.

Liver

The liver is subjectively normal in size with normal smooth curvilinear peripheral contour. Parenchyma is appropriately hypoechoic to the spleen in echogenicity and appropriately mildly coarse and homogenous in echotexture. In the left caudal liver, there is a discrete 7.0 cm, heterogeneous, partially cavitated mass. Visible vasculature and biliary tree appear normal without distension or congestion.

The gallbladder is non-distended in size. The wall is smooth without visible thickening. Luminal contents are primarily anechoic. There is no evidence of cystic or common bile duct dilation.

Gastrointestinal

The stomach wall is normal in thickness (canine < 0.5 cm and feline < 0.4 cm) and layering. The lumen of the stomach is empty with no evidence of obstruction, foreign material or infiltrative disease. Pyloric outflow tract appears patent.

The visible small intestines are normal in wall thickness and layering (canine duodenum < 0.5 cm and feline duodenum < 0.4 cm; other < 0.3 cm). Small intestinal motility appears adequate (1-3 contractions per min). The lumen of the small intestine is empty with no evidence of obstruction, foreign material or infiltrative disease.

IMAGING PERFORMED BY

SVS Mobile Imaging MI 734-637-7711
svsimagingmi@gmail.com



PATIENT

Abby Hieb

The visible colon is normal in wall thickness (< 0.2 cm) and layering. Contents are consistent with normal formed feces and gas.

SPECIES

Canine

Pancreas

The pancreatic parenchyma is appropriately isoechoic to surrounding tissue. Visible capsule is smooth and normal in contour. There is no visible pancreatic duct dilation. There is no evidence of active peripancreatic inflammation.

BREED

Lab

Free Abdomen

There is no evidence of free peritoneal effusion noted in these images.

SEX

Spayed Female

There is no apparent lymphadenopathy noted in these images.

ULTRASONOGRAPHIC FINDINGS

- Heterogeneous, partially cavitated liver mass – Differentials include both benign and malignant disease. Given this patient’s young age and reported fever, an abscessed or necrotic lesion is considered probable.

AGE

4 Years

INTERPRETATION OF THE FINDINGS & FURTHER RECOMMENDATIONS

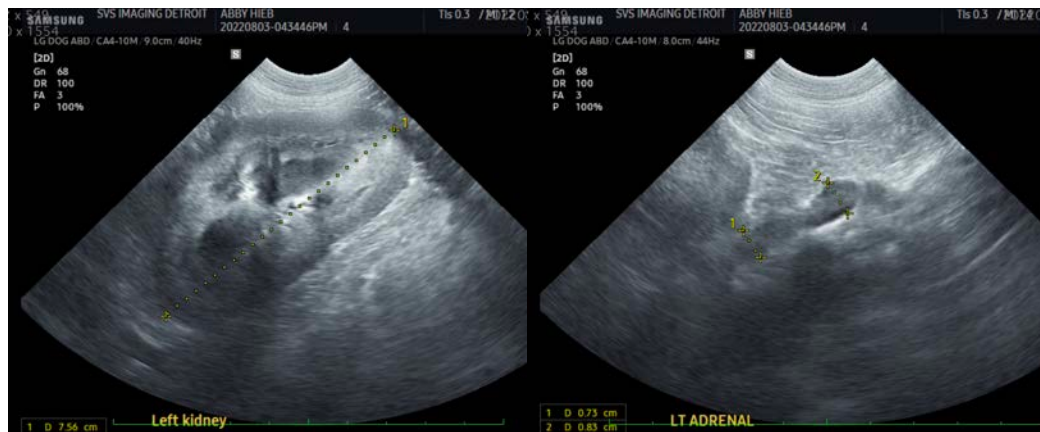
A fine needle aspirate of the liver mass for both cytology and culture is recommended if patient’s coagulation status is appropriate. In the meantime, supportive/symptomatic medical management is recommended with IV fluids, antiemetics, appetite stimulants if necessary, and broad-spectrum antibiotics.

WEIGHT

77 Pounds

INTERPRETED BY

Beth Johnson, DVM
DACVIM



IMAGING PERFORMED BY

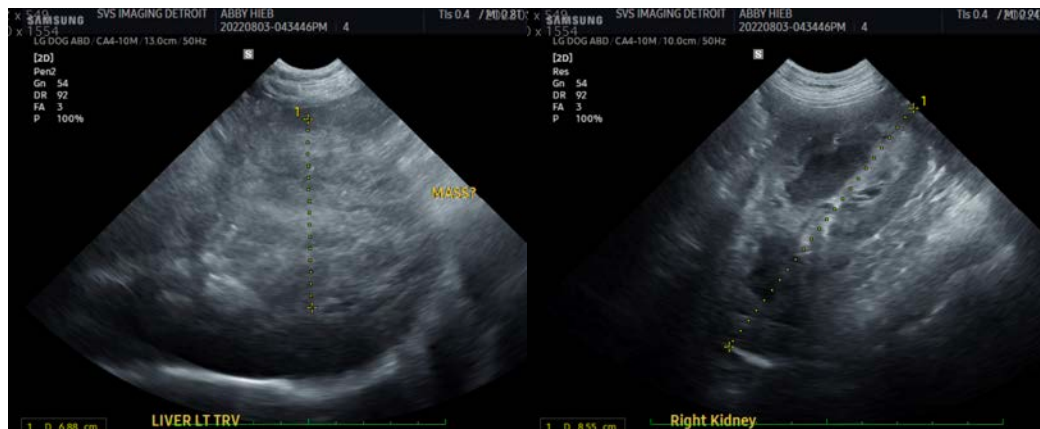
Amy Mayhew, LVT

HOSPITAL NAME

SVS Imaging MI

REFERRING VET

Briarwood VH



INVOICE

40151

DATE

8/3/22

IMAGING PERFORMED BY

SVS Mobile Imaging MI 734-637-7711
svsimagingmi@gmail.com



EDUCATIONAL TELECONSULTATION SERVICES™
1-800-838-4268 info@sonopath.com SonoPath.com

PATIENT

Abby Hieb

SPECIES

Canine

BREED

Lab

SEX

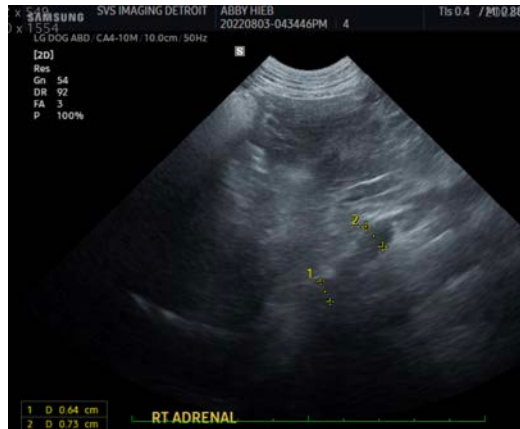Spayed Female

AGE

4 Years

WEIGHT

77 Pounds



The information and recommendations provided are based on the images presented by the referring veterinarian/sonographer. No evaluation can be communicated regarding pathology that was not visible in the image/video clips provided.

Thank you for this referral. If the clinical or image interpretation does not parallel your findings or if I can be of any further assistance please contact me.

Beth Johnson, DVM, DACVIM
Beth.Johnson@sonopath.com

INTERPRETED BY

Beth Johnson, DVM
DACVIM

IMAGING PERFORMED BY

Amy Mayhew, LVT

HOSPITAL NAME

SVS Imaging MI

REFERRING VET

Briarwood VH

INVOICE

40151

DATE

8/3/22