

PATIENT PRESENTING CLINICAL SIGNS

Roy Kuyenhoven-
Esseltine

weight loss (1.7kg in 2months) -hyporexia -one episode of vomiting and diarrhea on Saturday -pink, slightly tacky mucous membranes - Intermittent V/D since May 2023 Current Medications Mirtazapine 15mg SID

SPECIES

Canine

Abnormal PE/Chem/CBC/UA Results: Bloodwork from 05/12/2023: CBC,Electrolytes, Chem - elevated renal and hepatic values, elevated protein (dehydration), abnormal cPL Urine analysis - bacteria from table top with no signs UTI. Low Sp.G, few struvites. Radiographic Findings May 2023:

BREED

Cocker Spaniel X

Mild hepatomegaly but otherwise quite unremarkable, no obvious evidence of mass/obstructive pattern. See rads attached, radio-opacity cranial abdomen, liver appears enlarged. Poor detail in area of kidneys. Possible mass effect cranial abd but caudal to stomach on lateral

SEX

Neutered Male

ULTRASONOGRAPHIC EXAMINATION OF THE ABDOMEN

Urinary System

AGE

14 Years

Urinary bladder is adequately distended with primarily anechoic contents and occasional echogenic non-shadowing debris. Apical urinary bladder wall is diffusely thick (0.66 cm). Mucosa is hyperechoic and irregular. No masses or cystoliths are observed. The trigone and visible pelvic urethra are normal thickness with a smooth mucosal surface.

WEIGHT

15 kg

Prostate is normal in size, echotexture and echogenicity for a neutered male.

INTERPRETED BY

Beth Johnson, DVM
DACVIM

Kidneys are overall normal in size and shape with smooth peripheral margination. A normal 1:3 cortex to medulla ratio is maintained. The medulla and cortices are uniform in texture with some mild increased cortical echogenicity and mild loss of corticomedullary distinction, expected in this age patient. There is no evidence of mineral or infarcts observed. Trace pyelectasia is noted bilaterally. The left kidney measured 5.0 cm. The right kidney measures 4.47 cm.

IMAGING PERFORMED BY

Kelly Reschny

Adrenal Glands

The right adrenal gland is normal in size (1.5 cm at the cranial pole and 0.44 cm at the caudal pole), shape and contour. Corticomedullary structure is unremarkable. Visible surrounding vasculature appears normal.

HOSPITAL NAME

BPH Burlington

The left adrenal gland is normal in size (0.72 cm at the cranial pole and 0.76 cm at the caudal pole), shape and contour. Corticomedullary structure is unremarkable. Visible surrounding vasculature appears normal.

REFERRING VET

Dr. Avey

Spleen

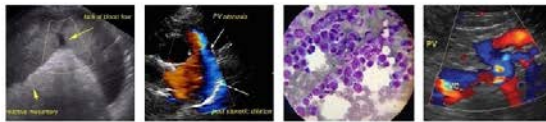
INVOICE

44928

The spleen is subjectively normal in size with a normal smooth capsular contour. Parenchyma is appropriately finely textured and homogenous with normal echogenicity relative to surrounding tissue (hyperechoic to liver). A 0.50 cm x 0.90 cm hypo- to anechoic non-capsule disrupting nodule is noted near the head of the spleen, as well as a discrete homogeneous hyperechoic nodule in the mid body. Splenic vasculature appears normal.

DATE

8/24/23



PATIENT

Liver

Roy Kuyenhoven-
Esseltine

Liver is subjectively enlarged (swollen contour). Mild parenchymal remodeling with diffusely mildly coarse architecture and increased portal markings is present. No focal nodules or masses are observed. Visible vasculature and biliary tree appear normal without distension or congestion.

SPECIES

Canine

Gallbladder is moderately distended with anechoic bile as well as suspended and gravity dependent echogenic debris. The wall is smooth without visible thickening. There is no evidence of cystic or CBD dilation. There is no evidence of effusion or inflammation.

BREED

Cocker Spaniel X

Gastrointestinal

SEX

Neutered Male

The stomach wall is normal in thickness (canine < 0.5 cm and feline < 0.4 cm) and layering. The lumen of the stomach is mildly distended with fluid, as well as echogenic nonshadowing luminal contents and gas consistent with normal ingesta/chyme. There is no evidence of obstruction, foreign material or infiltrative disease. Pyloric outflow tract appears patent.

AGE

14 Years

The visible small intestines are normal in wall thickness and layering (canine duodenum < 0.5 cm and feline duodenum < 0.4 cm; other < 0.3 cm). Small intestinal motility appears adequate (1-3 contractions per min). The lumen of the small intestine is empty with no evidence of obstruction, foreign material or infiltrative disease.

WEIGHT

15 kg

The visible colon is normal in wall thickness (< 0.2 cm) and layering. Contents are consistent with normal formed feces and gas.

INTERPRETED BY

Beth Johnson, DVM
DACVIM

Pancreas

The pancreatic parenchyma is appropriately isoechoic to surrounding tissue. Visible capsule is smooth and normal in contour. There is no visible pancreatic duct dilation. There is no evidence of active peripancreatic inflammation.

IMAGING PERFORMED BY

Kelly Reschny

Free Abdomen

There is no evidence of free peritoneal effusion noted in these images.

There is no apparent lymphadenopathy noted in these images.

HOSPITAL NAME

BPH Burlington

There is no evidence of heart base or pericardial pathology noted in these images at this time. If cardiac function evaluation is desired a full echocardiogram is recommended.

REFERRING VET

Dr. Avey

PRIMARY FINDINGS

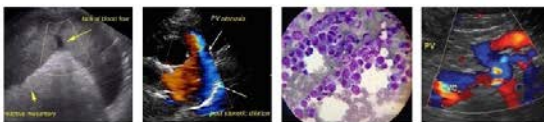
- **Hypoechoic hepatomegaly** – This appearance is consistent with an acute hepatopathy or acute cholangiohepatitis. Infiltrative neoplasia (round cell neoplasia) should also be considered.
- **Moderate gallbladder debris** - Cholecystic debris is of unknown clinical significance. It can be seen with biliary stasis from fasting or illness. Cholecystic debris is not necessarily related to hepatobiliary disease. Echogenic bile is most commonly an incidental finding in dogs and should be interpreted in combination with clinical signs such as nausea, inappetence, cranial abdominal discomfort and/or laboratory changes such as increased ALP and/or increased Tbili.
- **Hypo to anechoic splenic nodule with hyperechoic splenic nodule as well** – likely represents a benign lesion such as a cyst, hematoma, nodular hyperplasia, extramedullary hematopoiesis,

INVOICE

44928

DATE

8/24/23



PATIENT

Roy Kuyenhoven-Esseltine

SPECIES

Canine

BREED

Cocker Spaniel X

SEX

Neutered Male

AGE

14 Years

WEIGHT

15 kg

INTERPRETED BY

Beth Johnson, DVM
DACVIM

IMAGING PERFORMED BY

Kelly Reschny

HOSPITAL NAME

BPH Burlington

REFERRING VET

Dr. Avey

INVOICE

44928

DATE

8/24/23

etc., however while considered less likely, infiltrative neoplasia can mimic benign lesions, and cannot be ruled out.

- **Chronic Cystitis** - Urinary bladder wall changes are most consistent with chronic cystitis. Infiltrative neoplasia cannot be ruled out but is considered less likely give the location and diffuse nature of the changes.
- **Age related kidney changes with mild bilateral pyelectasia** - Differentials for pyelectasia include pyelonephritis, diuresis, congenital malformation or ureteral or lower urinary tract obstruction.

INTERPRETATION OF THE FINDINGS & FURTHER RECOMMENDATIONS

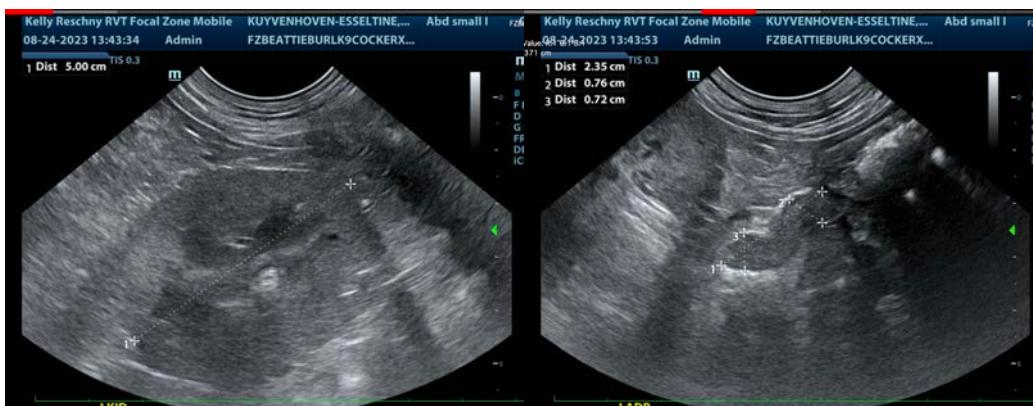
If possible, using a sterile obtained urine sample, a recheck urinalysis and, if indicated based on urinalysis results, urine culture are recommended. If protein is present in an otherwise quiet sediment, protein quantification with a urine protein to creatinine ration is recommended.

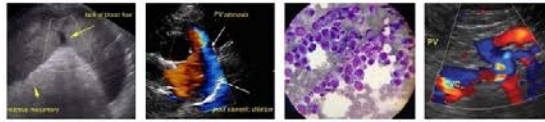
Further evaluation of the reportedly increased liver enzymes is partially dependent on the degree of pattern of increase. However, given concurrent reported azotemia, recommendations include an “antigen search” for sources of reactive hepatopathy (including testing for Leptospirosis), followed by a course of empirical antibiotics and hepatic nutraceuticals, with monitoring of ALT for improvement. If improvement is noted, antibiotics should be continued until liver enzymes either normalize or plateau (recheck every 2-3 weeks); however, if improvement is not noted and/or enzyme increase progresses, antibiotics should not be continued long term and sampling, beginning with a FNA of the liver if patient’s coagulation status is appropriate or progressing to a liver biopsy (including copper level assessment) may ultimately be warranted.

In addition, given the gastrointestinal signs, further evaluation of digestion and absorption is recommended, beginning with:

A gastrointestinal malabsorption panel (including cobalamin, folate, TLI and PLI) to Texas A&M GI Laboratory is recommended for further evaluation of GI and pancreatic function.

In addition to management of the unknown hepatopathy +/- emerging chronic kidney disease, gastrointestinal support is recommended in the form of antiemetics, gastroprotectants including sucralfate, a probiotic such as Visbiome or Provable and empirical deworming with a 5-day course of Panacur could be considered.





PATIENT

Roy Kuyenhoven-
Esseltine

SPECIES

Canine

BREED

Cocker Spaniel X

SEX

Neutered Male

AGE

14 Years

WEIGHT

15 kg

INTERPRETED BY

Beth Johnson, DVM
DACVIM

**IMAGING
PERFORMED BY**

Kelly Reschny

HOSPITAL NAME

BPH Burlington

REFERRING VET

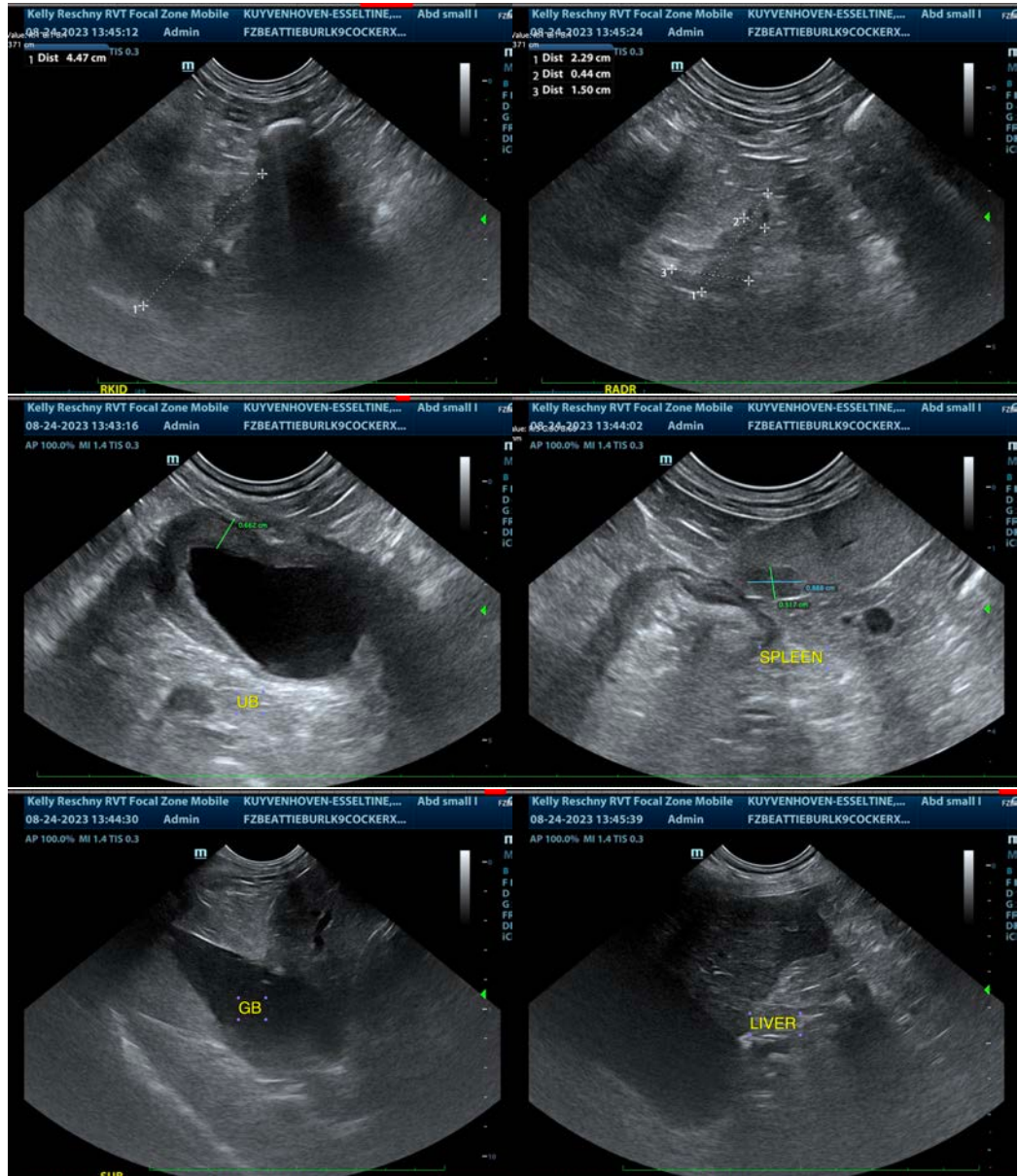
Dr. Avey

INVOICE

44928

DATE

8/24/23



The information and recommendations provided are based on the images presented by the referring veterinarian/sonographer. No evaluation can be communicated regarding pathology that was not visible in the image/video clips provided.

Thank you for this referral. If the clinical or image interpretation does not parallel your findings or if I can be of any further assistance please contact me.

Beth Johnson, DVM, DACVIM
info@sonopath.com