

**PATIENT PRESENTING CLINICAL SIGNS**

Bosco Gibbons

Chronic history of vomiting, frequency of which worsened earlier this year. Senior workup performed and T4 at that time was high normal. Started on Tapazole and T4 levels stabilized but vomiting has continued. Owner agreed to abdominal US to rule out other cause of vomiting and weight loss.

**SPECIES**

Feline

Abnormal PE/Chem/CBC/UA Results: Bloodwork performed in Mar 2023-noted elevated BUN but Cre wnl at that time. Otherwise bloodwork was unremarkable

**BREED**

DSH

**ULTRASONOGRAPHIC EXAMINATION OF THE ABDOMEN**

**Urinary System**

**SEX**

Spayed Female

The urinary bladder is moderately distended with anechoic contents. No masses, inflammatory changes, echogenic sediment or cystoliths are observed. The urinary bladder, trigone and visible pelvic urethra are normal in thickness with a smooth mucosal surface.

**AGE**

14 Years

The right kidney is normal in size (3.26 cm), shape and echogenicity. It has smooth peripheral margination. There is a normal 1:3 cortex to medulla ratio with appropriate corticomedullary distinction. There is no evidence of pyelectasia, mineral or infarcts observed.

**WEIGHT**

2.76

The left kidney is normal in size (3.18 cm), shape and echogenicity. It has smooth peripheral margination. There is a normal 1:3 cortex to medulla ratio with appropriate corticomedullary distinction. There is no evidence of pyelectasia, mineral or infarcts observed.

**INTERPRETED BY**

Beth Johnson, DVM  
DACVIM

**Adrenal Glands**

The right adrenal gland is normal in size (0.38 cm), shape and contour. Corticomedullary structure is unremarkable. Visible surrounding vasculature appears normal.

The left adrenal gland is normal in size (0.43 cm), shape and contour. Corticomedullary structure is unremarkable. Visible surrounding vasculature appears normal.

**IMAGING PERFORMED BY**

Dr. Antonopoulos

**Spleen**

The spleen is subjectively normal in size with a normal smooth capsular contour. Parenchyma is appropriately finely textured and homogenous with normal echogenicity relative to surrounding tissue (hyperechoic to liver). No focal nodules or masses are observed. Splenic vasculature appears normal.

**HOSPITAL NAME**

Orchard Vet Care

**Liver**

The liver is subjectively normal in size with normal smooth curvilinear peripheral contour. Parenchyma is appropriately hypoechoic to the spleen in echogenicity and appropriately mildly coarse and homogenous in echotexture. No focal lesions are observed. Visible vasculature and biliary tree appear normal without distension or congestion.

**REFERRING VET**

Dr. Antonopoulos

**INVOICE**

44936

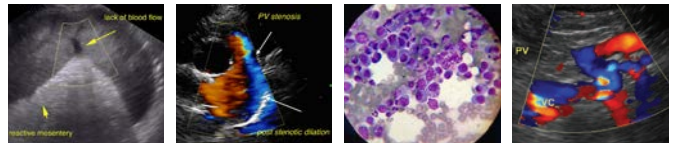
The gallbladder is non-distended in size. The wall is smooth without visible thickening. Luminal contents are primarily anechoic. There is no evidence of cystic or common bile duct dilation.

**DATE**

8/24/23

**Gastrointestinal**

The stomach wall is normal in thickness (canine < 0.5 cm and feline < 0.4 cm) and layering. The lumen of the stomach is empty with no evidence of obstruction, foreign material or infiltrative disease. Pyloric outflow tract appears patent.



**PATIENT**

Bosco Gibbons

The visible small intestine demonstrates areas of mildly thick muscularis layer relative to mucosa (disruption of the normal 1:3 muscularis:mucosa ratio). Small intestinal submucosa is slightly irregular, thick and hyperechoic, without evident loss of layering appreciated. The lumen is empty with no evidence of obstruction or foreign material.

**SPECIES**

Feline

The visible colon is normal in wall thickness (< 0.2 cm) and layering. Contents are consistent with normal formed feces and gas.

**BREED**

***Pancreas***

DSH

The pancreatic parenchyma is appropriately isoechoic to surrounding tissue. Visible capsule is smooth and normal in contour. There is no visible pancreatic duct dilation. There is no evidence of active peripancreatic inflammation.

**SEX**

Spayed Female

***Free Abdomen***

**AGE**

14 Years

There is no evidence of free peritoneal effusion noted in these images.

There is no apparent lymphadenopathy noted in these images.

**ULTRASONOGRAPHIC FINDINGS**

**WEIGHT**

2.76

- **Subtle/suspect emerging inflammatory bowel disease (IBD) pattern** – Thick muscularis has been reported with infiltrative bowel disease including both benign inflammatory disease as well as infiltrative neoplasia such as lymphoma. No aggressive lymphadenopathy, loss of layering, etc. is noted to make lymphoma more probable, but lymphoma cannot be definitively ruled out without tissue sampling.

**INTERPRETED BY**

Beth Johnson, DVM  
DACVIM

**INTERPRETATION OF THE FINDINGS & FURTHER RECOMMENDATIONS**

A gastrointestinal malabsorption panel (including cobalamin, folate, TLI and PLI) to Texas A&M GI Laboratory is recommended for further evaluation of GI and pancreatic function.

**IMAGING PERFORMED BY**

Dr. Antonopoulos

Ideally, biopsies of the GI tract, being sure to include ileum if possible, are recommended to definitively diagnose and therefore manage the infiltrative bowel disease.

**HOSPITAL NAME**

Orchard Vet Care

If biopsies cannot be obtained, empirical therapies could include a probiotic (if diarrhea is present, such as visbiome or proviable), empirical deworming with a 5-day course of Panacur and, if tolerated, a transition in diet, based on trial-and-error response, beginning with a hydrolyzed protein diet. Some patients respond to one brand/version of a hydrolyzed protein diet better than another brand, so several trials may be required.

**REFERRING VET**

Dr. Antonopoulos

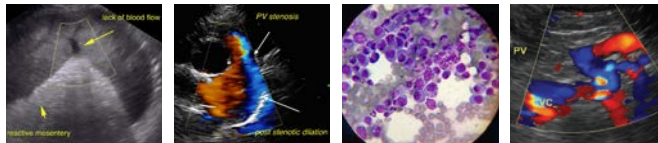
Additional considerations could include cobalamin supplementation (unless cobalamin level is evaluated and supplementation is not warranted) and prednisolone (if not contraindicated based on patient contraindications, co-morbidities, etc.).

**INVOICE**

44936

**DATE**

8/24/23



**PATIENT**

Bosco Gibbons

**SPECIES**

Feline

**BREED**

DSH

**SEX**

Spayed Female

**AGE**

14 Years

**WEIGHT**

2.76

**INTERPRETED BY**

Beth Johnson, DVM  
DACVIM

**IMAGING PERFORMED BY**

Dr. Antonopoulos

**HOSPITAL NAME**

Orchard Vet Care

**REFERRING VET**

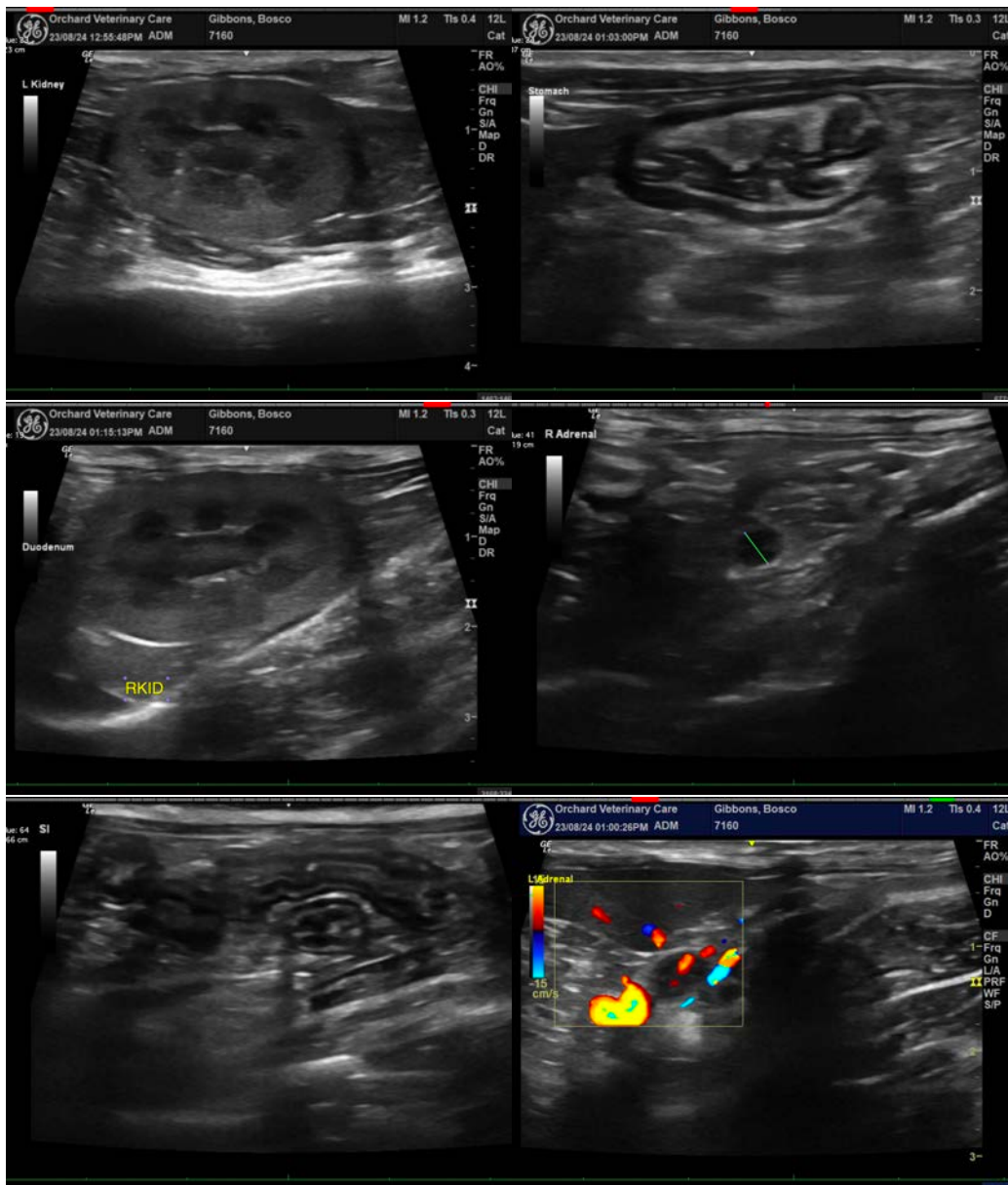
Dr. Antonopoulos

**INVOICE**

44936

**DATE**

8/24/23



The information and recommendations provided are based on the images presented by the referring veterinarian/sonographer. No evaluation can be communicated regarding pathology that was not visible in the image/video clips provided.

Thank you for this referral. If the clinical or image interpretation does not parallel your findings or if I can be of any further assistance please contact me.

**Beth Johnson, DVM, DACVIM**  
info@sonopath.com