

IMAGING PERFORMED BY

IntraPet.com



SonoPath

Clinical Sonography & Telecytology

EDUCATIONAL TELECONSULTATION SERVICES™

1-800-838-4268 info@sonopath.com SonoPath.com

DATE PRESENTING CLINICAL SIGNS

8/24/22 Hx of hyperthyroidism--well controlled on methimazole. Recent wt loss and decreased appetite. Has lost 2 lb since 4/2022 and labwork on 8/19/2022 shows T4 is low and no other significant changes. O noticed 1 episode of non specific straining--could not determine if to defecate or urinate. Non productive at that time. No V reported. Has been eating better last 3 days on mirtazipine. PE concern for thickened GI loops but no discrete mass palpable at that time. No evidence of constipation on PE.

PATIENT
Smokey Jankowski

SPECIES
Feline

BREED
DSH

SEX
Spayed Female

AGE
10/1/08

WEIGHT
8.8 Pounds

INTERPRETED BY
Beth Johnson, DVM
DACVIM

IMAGING PERFORMED BY
Rachel Brillhart RDMS

HOSPITAL NAME
Paradise AH

REFERRING VET
Dr. Kats

INVOICE
40712

Current Medications: Methimazole 5 mg--Was on 2.5 mg po bid until 8/19/2022, since then have dropped to 2.5 mg po sid. Mirtazipine transdermal gel q 24 hrs to stimulate appetite since 8/19/2022
Date of Previous IntraPet Ultrasound: No previous.
Sedation: Not required to complete full diagnostic ultrasound.
Stat Report: Not requested.

ULTRASONOGRAPHIC EXAMINATION OF THE ABDOMEN

Urinary System

The urinary bladder is moderately distended with anechoic contents. No masses, inflammatory changes, echogenic sediment or cystoliths are observed. The urinary bladder, trigone and visible pelvic urethra are normal in thickness with a smooth mucosal surface.

The right kidney is normal in size (3.69 cm), shape and echogenicity. It has smooth peripheral margination. There is a normal 1:3 cortex to medulla ratio with appropriate corticomedullary distinction. There is no evidence of pyelectasia, mineral or infarcts observed.

The left kidney is normal in size (3.8 cm), shape and echogenicity. It has smooth peripheral margination. There is a normal 1:3 cortex to medulla ratio with appropriate corticomedullary distinction. There is no evidence of pyelectasia, mineral or infarcts observed.

Adrenal Glands

The right adrenal gland is normal in size (0.44 cm), shape and contour. Corticomedullary structure is unremarkable. Visible surrounding vasculature appears normal.

The left adrenal gland is normal in size (0.47 cm), shape and contour. Corticomedullary structure is unremarkable. Visible surrounding vasculature appears normal.

Spleen

The spleen is subjectively normal in size with a normal smooth capsular contour. Parenchyma is appropriately finely textured and homogenous with normal echogenicity relative to surrounding tissue (hyperechoic to liver). No focal nodules or masses are observed. Splenic vasculature appears normal.

Liver

Liver is subjectively enlarged (swollen contour) without disruption of architecture. It has a normal homogenous echotexture. Parenchyma is diffusely hyperechoic characterized by less prominent than normal portal vein walls and increased echogenicity relative to the spleen and falciform fat. No focal lesions are observed. Visible vasculature and biliary tree appear normal without distension or congestion.

The gallbladder is non-distended in size. The wall is smooth without visible thickening. Luminal contents are primarily anechoic. There is no evidence of cystic or common bile duct dilation.

Gastrointestinal

The visible stomach wall is normal in thickness and layering. The lumen of the stomach is mildly distended with echogenic non-shadowing luminal contents and gas consistent with normal ingesta. There is no evidence of obstruction, foreign material or infiltrative disease. Pyloric outflow tract appears patent.

The visible small intestine demonstrates areas of thick muscularis layer relative to mucosa (disruption of the normal 1:3 muscularis:mucosa ratio). Small intestinal submucosa is slightly irregular, thick and hyperechoic, without evident loss of layering appreciated. The lumen is empty with no evidence of obstruction or foreign material.

The visible colon is normal in wall thickness (< 0.2 cm) and layering. Contents are consistent with normal formed feces and gas.

Pancreas

The pancreatic parenchyma is appropriately isoechoic to surrounding tissue. Visible capsule is smooth and normal in contour. There is no visible pancreatic duct dilation. There is no evidence of active peripancreatic inflammation.

Free Abdomen

There is no evidence of free peritoneal effusion noted in these images.

There is no apparent lymphadenopathy noted in these images.

Enhanced hyperechoic fat and mesentery noted, primarily around the ileocecal junction and in the caudal abdomen, cranial to the urinary bladder and colon.

ULTRASONOGRAPHIC FINDINGS

- **Inflammatory bowel disease (IBD) pattern** – Thick muscularis has been reported with infiltrative bowel disease including both benign inflammatory disease as well as infiltrative neoplasia such as lymphoma. No aggressive lymphadenopathy, loss of layering, etc. is noted to make lymphoma more probable, but lymphoma cannot be definitively ruled out without tissue sampling.
- **Hyperechoic hepatomegaly** – This appearance is most consistent with benign hepatic lipidosis. Infiltrative disease such as amyloidosis or round cell neoplasia, such as mast cell tumor or less likely, lymphoma, is also possible.

INTERPRETATION OF THE FINDINGS & FURTHER RECOMMENDATIONS

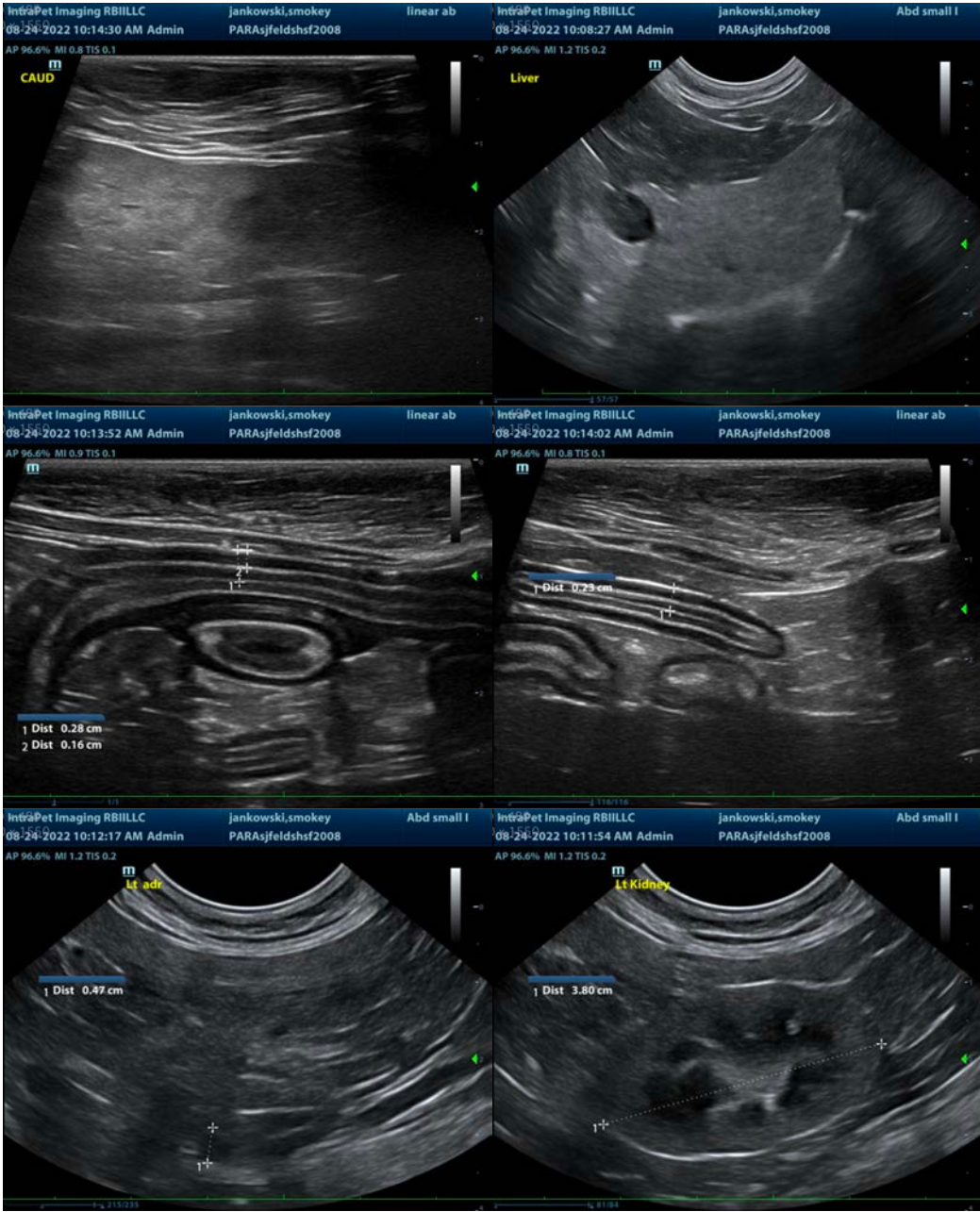
There is no ultrasonographically definitive reason for this patient's reported episode of straining. However, the changes in the caudal abdomen do suggest inflammation, potentially associated with the suspected bowel disease or potentially secondary to a cystitis or colitis without obvious visible changes to the bladder or colon in these images.

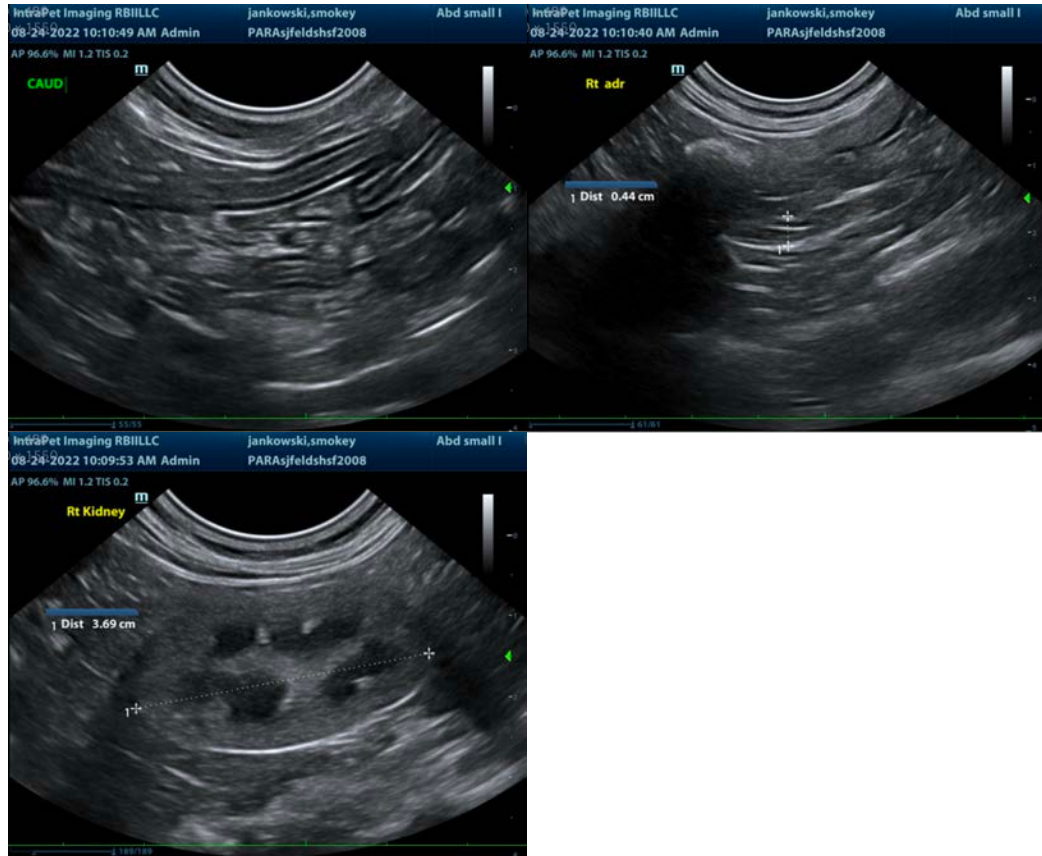
Given the reported episode of straining and the changes described above, a urinalysis and, if indicated based on urinalysis results, urine culture are recommended. If protein is present in an otherwise quiet sediment, protein quantification with a urine protein to creatinine ration is recommended.

A gastrointestinal malabsorption panel (including cobalamin, folate, TLI and PLI) to Texas A&M GI Laboratory is recommended for further evaluation of GI and pancreatic function.

Ideally, biopsies of the GI tract, being sure to include ileum if possible, are recommended to definitively diagnose and therefore manage the infiltrative bowel disease.

If biopsies cannot be obtained, empirical therapies could include diet change, empirical deworming with a 5 day course of Panacur, cobalamin supplementation (unless cobalamin level is evaluated and supplementation is not warranted) and prednisolone (if not contraindicated based on patient contraindications, co-morbidities, etc.).





The information and recommendations provided are based on the images presented by the referring veterinarian/sonographer. No evaluation can be communicated regarding pathology that was not visible in the image/video clips provided.

Thank you for this referral. If the clinical or image interpretation does not parallel your findings or if I can be of any further assistance please contact me.

Beth Johnson, DVM, DACVIM
Beth.Johnson@sonopath.com