



**PATIENT**

Blizzard Perez-Ramos

**SPECIES**

Canine

**BREED**

Husky

**SEX**

Neutered Male

**AGE**

12 Years

**WEIGHT**

28 kg

**INTERPRETED BY**

Beth Johnson, DVM  
DACVIM

**IMAGING PERFORMED BY**

Dr. Matthew Olcha

**HOSPITAL NAME**

East Meadow Vet  
Center

**REFERRING VET**

Dr. Matthew Olcha

**INVOICE**

40707

**DATE**

8/24/22

**PRESENTING CLINICAL SIGNS**

Presented for dental. Noted to have lost 3kg since January. Procedure postponed due to hypercalcemia on pre-op labs. Samples sent to reference lab for ionized calcium, PTH, PTHrP testing. Chest x-rays unremarkable.

Abnormal PE/Chem/CBC/UA Results: Hypercalcemia (12.3) and hypophosphatemia (1.8). CBC unremarkable. Small nodular structure palpable in vicinity of left anal sac, otherwise age-appropriate findings on exam.

**ULTRASONOGRAPHIC EXAMINATION OF THE ABDOMEN**

**Urinary System**

Urinary bladder is adequately distended. It has a normal uniform wall thickness. Contents include primarily anechoic fluid with occasional echogenic non-shadowing debris, most consistent with exfoliated cells, mucous and/or small blood clots. Both sterile inflammation as well as urinary tract infection can also present with echogenic debris. Several cystoliths are noted measuring approximately 0.3-0.4 cm in diameter each. The trigone and visible pelvic urethra are normal in thickness with a smooth mucosal surface.

The right kidney is normal in size (6.9 cm), shape and echogenicity. It has smooth peripheral margination. There is a normal 1:3 cortex to medulla ratio with appropriate corticomedullary distinction. There is no evidence of pyelectasia or infarcts observed. Non-obstructive areas of mineralization/nephroliths are noted.

The left kidney is normal in size (7.0 cm), shape and echogenicity. It has smooth peripheral margination. There is a normal 1:3 cortex to medulla ratio with appropriate corticomedullary distinction. There is no evidence of pyelectasia or infarcts observed. Non-obstructive areas of mineralization/nephroliths are noted.

**Adrenal Glands**

The area of the right adrenal gland is examined without evident pathology.

The left adrenal gland is normal in size (1.0 cm thick at the caudal pole, cranial pole is unable to be well visualized in these images), shape and contour. Corticomedullary structure is unremarkable. Visible surrounding vasculature appears normal.

**Spleen**

The spleen is subjectively normal in size with a normal smooth capsular contour. Parenchyma is appropriately finely textured and homogenous with normal echogenicity relative to surrounding tissue (hyperechoic to liver). An approximately 2.0 cm in diameter, round, hypoechoic nodule is noted in the mid body on the medial aspect of the spleen. Splenic vasculature appears normal.

**Liver**

The liver is subjectively normal in size with normal smooth curvilinear peripheral contour. Parenchyma is appropriately hypoechoic to the spleen in echogenicity and appropriately mildly coarse and homogenous in echotexture. No focal lesions are observed. Visible vasculature and biliary tree appear normal without distension or congestion.

Gallbladder is moderately distended with anechoic bile as well as suspended and gravity dependent echogenic debris. Mineral is adhered to the inner wall. The wall is smooth without visible thickening. There is no evidence of cystic or CBD dilation. There is no evidence of effusion or inflammation.



**PATIENT**

Blizzard Perez-Ramos

**SPECIES**

Canine

**BREED**

Husky

**SEX**

Neutered Male

**AGE**

12 Years

**WEIGHT**

28 kg

**INTERPRETED BY**

Beth Johnson, DVM  
DACVIM

**IMAGING PERFORMED BY**

Dr. Matthew Olcha

**HOSPITAL NAME**

East Meadow Vet  
Center

**REFERRING VET**

Dr. Matthew Olcha

**INVOICE**

40707

**DATE**

8/24/22

**Gastrointestinal**

The stomach wall is normal in thickness (canine < 0.5 cm and feline < 0.4 cm) and layering. The lumen of the stomach is empty with no evidence of obstruction, foreign material or infiltrative disease. Pyloric outflow tract appears patent.

The visible small intestines are normal in wall thickness and layering (canine duodenum < 0.5 cm and feline duodenum < 0.4 cm; other < 0.3 cm). Small intestinal motility appears adequate (1-3 contractions per min). The lumen of the small intestine is empty with no evidence of obstruction, foreign material or infiltrative disease.

The visible colon is normal in wall thickness (< 0.2 cm) and layering. Contents are consistent with normal formed feces and gas.

**Pancreas**

The pancreatic parenchyma is appropriately isoechoic to surrounding tissue. Visible capsule is smooth and normal in contour. There is no visible pancreatic duct dilation. There is no evidence of active peripancreatic inflammation.

**Free Abdomen**

There is no evidence of free peritoneal effusion noted in these images.

There is no apparent lymphadenopathy noted in these images.

**ULTRASONOGRAPHIC FINDINGS**

- **Hyperechoic splenic nodule** – most consistent (especially given this patient’s hypercalcemia) with a calcified lipogranuloma or calcification of an old hematoma or infarct. Metastatic disease cannot be ruled out but is considered less likely.
- **Chronic Cystitis with cystoliths** - Urinary bladder wall changes are most consistent with chronic cystitis. Infiltrative neoplasia cannot be ruled out but is considered less likely given the location and diffuse nature of the changes.
- **Gallbladder debris with cholecystoliths** - Cholecystic debris is of unknown clinical significance. It can be seen with biliary stasis from fasting or illness. Cholecystic debris is not necessarily related to hepatobiliary disease. Echogenic bile is most commonly an incidental finding in dogs and should be interpreted in combination with clinical signs such as nausea, inappetence, cranial abdominal discomfort and/or laboratory changes such as increased ALP and/or increased Tbili.
- Non-obstructive nephrolithiasis bilaterally

**INTERPRETATION OF THE FINDINGS & FURTHER RECOMMENDATIONS**

The majority of the changes present in this ultrasound are consistent with this patient’s reported hypercalcemia. Given this patient’s history, top differentials include hypercalcemia of malignancy secondary to an anal gland tumor versus hyperparathyroidism. Therefore, a PTH/PTHrP, ionized calcium/malignancy panel, as is reportedly pending, is recommended to further dictate treatment.



**PATIENT**

Blizzard Perez-Ramos

**SPECIES**

Canine

**BREED**

Husky

**SEX**

Neutered Male

**AGE**

12 Years

**WEIGHT**

28 kg

**INTERPRETED BY**

Beth Johnson, DVM  
DACVIM

**IMAGING PERFORMED BY**

Dr. Matthew Olcha

**HOSPITAL NAME**

East Meadow Vet  
Center

**REFERRING VET**

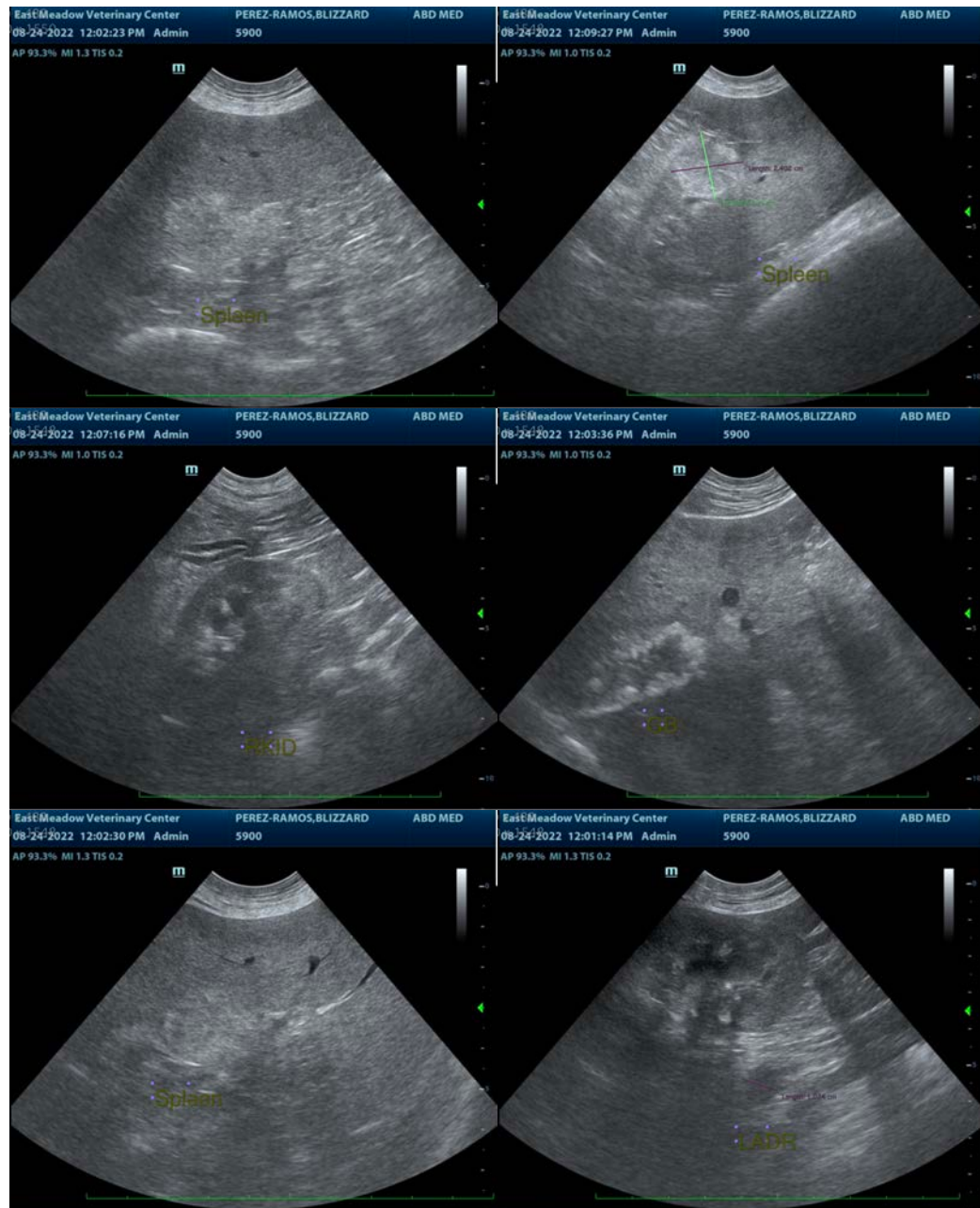
Dr. Matthew Olcha

**INVOICE**

40707

**DATE**

8/24/22





**PATIENT**

Blizzard Perez-Ramos

**SPECIES**

Canine

**BREED**

Husky

**SEX**

Neutered Male

**AGE**

12 Years

**WEIGHT**

28 kg

**INTERPRETED BY**

Beth Johnson, DVM  
DACVIM

**IMAGING PERFORMED BY**

Dr. Matthew Olcha

**HOSPITAL NAME**

East Meadow Vet  
Center

**REFERRING VET**

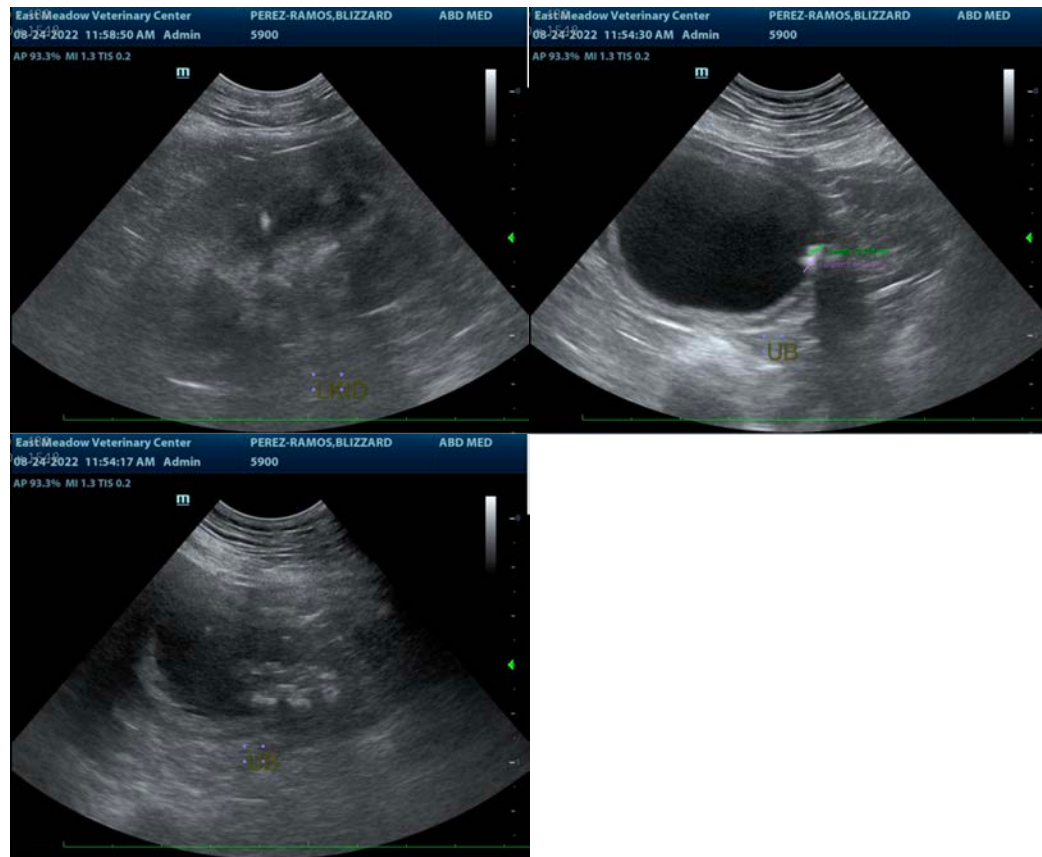
Dr. Matthew Olcha

**INVOICE**

40707

**DATE**

8/24/22



The information and recommendations provided are based on the images presented by the referring veterinarian/sonographer. No evaluation can be communicated regarding pathology that was not visible in the image/video clips provided.

Thank you for this referral. If the clinical or image interpretation does not parallel your findings or if I can be of any further assistance please contact me.

**Beth Johnson, DVM, DACVIM**  
Beth.Johnson@sonopath.com