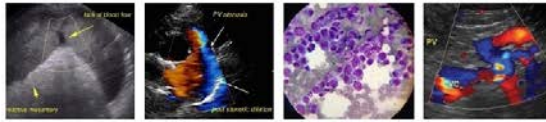
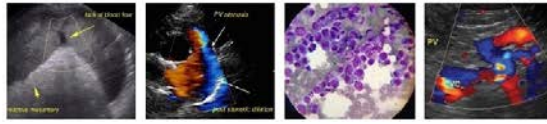


PATIENT	PRESENTING CLINICAL SIGNS
Snowflake Johnson	Not herself for the past week-has been off her food a bit. Has been vomiting a few times a week which is new. Had previous US done Sept 22 (report attached)
SPECIES	Abnormal PE/Chem/CBC/UA Results: FPL consistent with pancreatitis
Feline	
BREED	ULTRASONOGRAPHIC EXAMINATION OF THE ABDOMEN
DSH	Urinary System
SEX	The urinary bladder is moderately distended with anechoic contents. No masses, inflammatory changes, echogenic sediment or cystoliths are observed. The urinary bladder, trigone and visible pelvic urethra are normal in thickness with a smooth mucosal surface.
Spayed Female	The right kidney is normal in size (4.1 cm), shape and echogenicity. It has smooth peripheral margination. There is a normal 1:3 cortex to medulla ratio with appropriate corticomedullary distinction. There is no evidence of pyelectasia, mineral or infarcts observed.
AGE	The left kidney is normal in size (4.28 cm), shape and echogenicity. It has smooth peripheral margination. There is a normal 1:3 cortex to medulla ratio with appropriate corticomedullary distinction. There is no evidence of pyelectasia, mineral or infarcts observed.
12 Years	
WEIGHT	Adrenal Glands
5.8 kg	The right adrenal gland is normal in size (0.30 cm), shape and contour. Corticomedullary structure is unremarkable. Visible surrounding vasculature appears normal.
INTERPRETED BY	The left adrenal gland is normal in size (0.30 cm), shape and contour. Corticomedullary structure is unremarkable. Visible surrounding vasculature appears normal.
Beth Johnson, DVM DACVIM	
IMAGING PERFORMED BY	Spleen
Kelly Reschny	Spleen is subjectively large in size with subtly scalloped or undulating capsular contour. Parenchyma is normal in echogenicity with a markedly coarse/heterogenous echotexture. No focal nodules or masses are observed. Splenic vasculature appears normal.
HOSPITAL NAME	Liver
Headon Forest AH	The liver is subjectively normal in size with normal smooth curvilinear peripheral contour. Parenchyma is appropriately hypoechoic to the spleen in echogenicity and appropriately mildly coarse and homogenous in echotexture. No focal lesions are observed. Visible vasculature and biliary tree appear normal without distension or congestion.
REFERRING VET	The gallbladder is non-distended in size. The wall is smooth without visible thickening. Luminal contents are primarily anechoic. There is no evidence of cystic or common bile duct dilation.
Dr. Van Monsjou	
INVOICE	Gastrointestinal
44905	In the cranial abdomen there is a markedly dilated loop of the gastrointestinal tract that contains a large amount of gas and a 2.5 cm in diameter echogenic interface with strong acoustic shadow that is making differentiation of cranial abdominal structures difficult. The shadowing object appears to be in the
DATE	
8/23/23	



PATIENT	stomach, as the structure that contains it can be followed to the pylorus. However, colon mimicking a gastric foreign body cannot be definitively ruled out.
Snowflake Johnson	
SPECIES	The visible small intestines are normal in wall thickness and layering (canine duodenum < 0.5 cm and feline duodenum < 0.4 cm; other < 0.3 cm). Small intestinal motility appears adequate (1-3 contractions per min). The lumen of the small intestine is empty with no evidence of obstruction, foreign material or infiltrative disease.
Feline	
BREED	The visible colon is normal in wall thickness (< 0.2 cm) and layering. Contents are consistent with normal formed feces and gas.
DSH	
SEX	Pancreas The pancreatic parenchyma is appropriately isoechoic to surrounding tissue. Visible capsule is smooth and normal in contour. There is no visible pancreatic duct dilation. There is no evidence of active peripancreatic inflammation.
Spayed Female	
AGE	Free Abdomen There is no evidence of free peritoneal effusion noted in these images.
12 Years	
WEIGHT	There is no apparent lymphadenopathy noted in these images.
5.8 kg	
INTERPRETED BY	ULTRASONOGRAPHIC FINDINGS
Beth Johnson, DVM DACVIM	<ul style="list-style-type: none"> Scalloped spleen – can be associated with benign or malignant infiltrative disease. Common causes include a reactive spleen secondary to immune stimulus or early infiltrative round cell neoplasia such as lymphoma or mast cell tumor. There is concern based on these images for a gastric foreign body, possibly a hairball versus other. However, given the gas and shadow artifact in the cranial abdomen, it is difficult to say definitively, and a dilated colon could be mimicking a distended stomach.
IMAGING PERFORMED BY	INTERPRETATION OF THE FINDINGS & FURTHER RECOMMENDATIONS
Kelly Reschny	Further differentiation of the stomach from the colon could be obtained potentially with abdominal radiographs if not already evaluated +/- contrast radiography of the stomach and/or colon. If this patient has a clinical history of constipation, the chances that the colon is “tricking me” are more likely. If not, there is more concern for a gastric foreign body, in which case an exploratory laparotomy may ultimately be necessary.
HOSPITAL NAME	In the meantime, supportive/symptomatic medical management with potential follow up imaging based on patient's clinical status could be considered as well.
Headon Forest AH	
REFERRING VET	INVOICE
Dr. Van Monsjou	Additionally in the meantime, a fine needle aspirate of the spleen could be considered if patient's coagulation status is appropriate.
	44905
	DATE
	8/23/23



PATIENT

Snowflake Johnson

SPECIES

Feline

BREED

DSH

SEX

Spayed Female

AGE

12 Years

WEIGHT

5.8 kg

INTERPRETED BY

Beth Johnson, DVM
DACVIM

IMAGING PERFORMED BY

Kelly Reschny

HOSPITAL NAME

Headon Forest AH

REFERRING VET

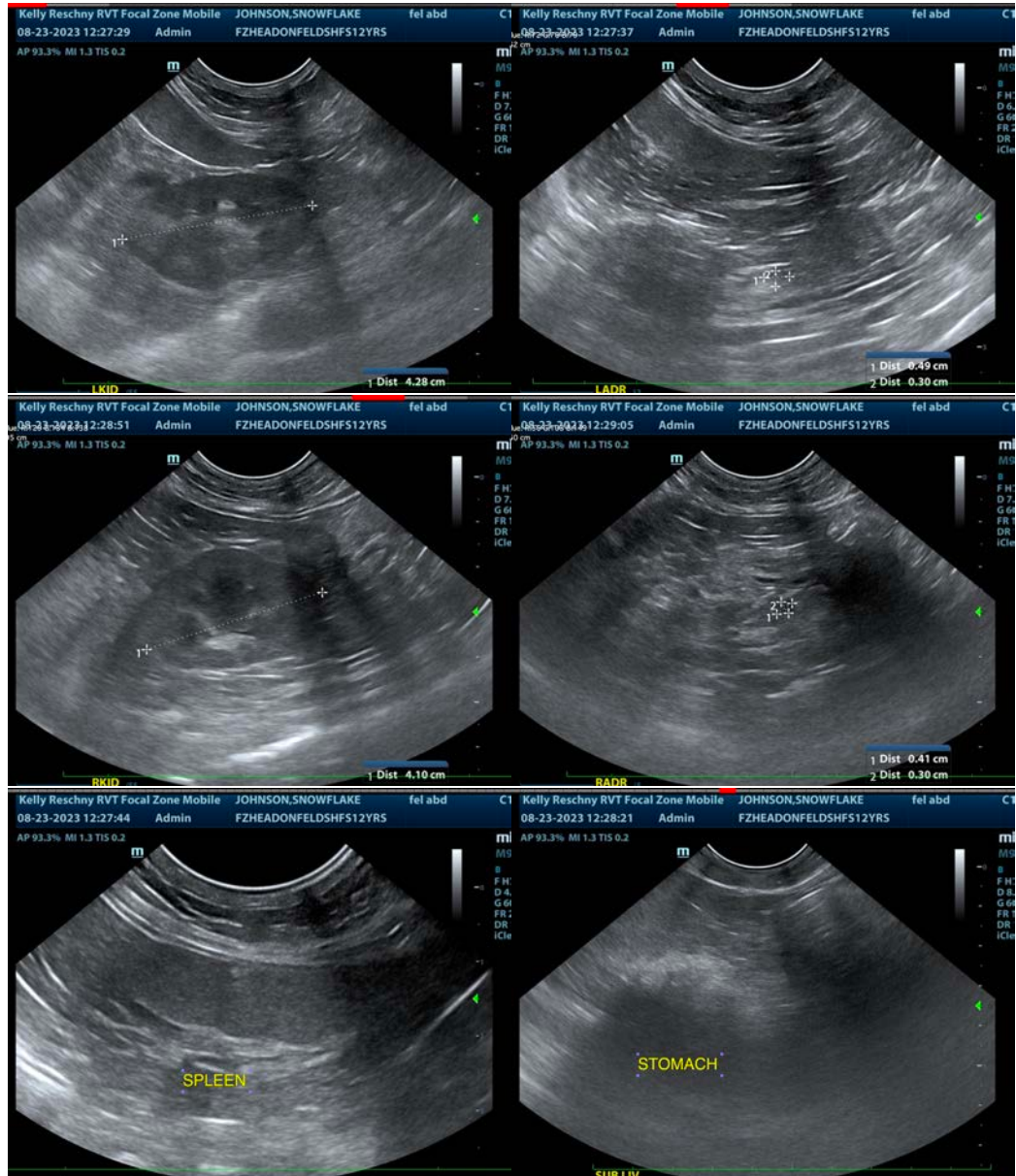
Dr. Van Monsjou

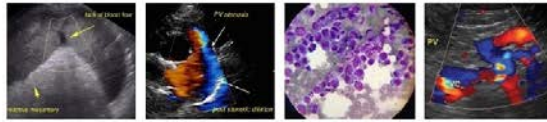
INVOICE

44905

DATE

8/23/23





PATIENT

Snowflake Johnson

SPECIES

Feline

BREED

DSH

SEX

Spayed Female

AGE

12 Years

WEIGHT

5.8 kg

INTERPRETED BY

Beth Johnson, DVM
DACVIM

IMAGING PERFORMED BY

Kelly Reschny

HOSPITAL NAME

Headon Forest AH

REFERRING VET

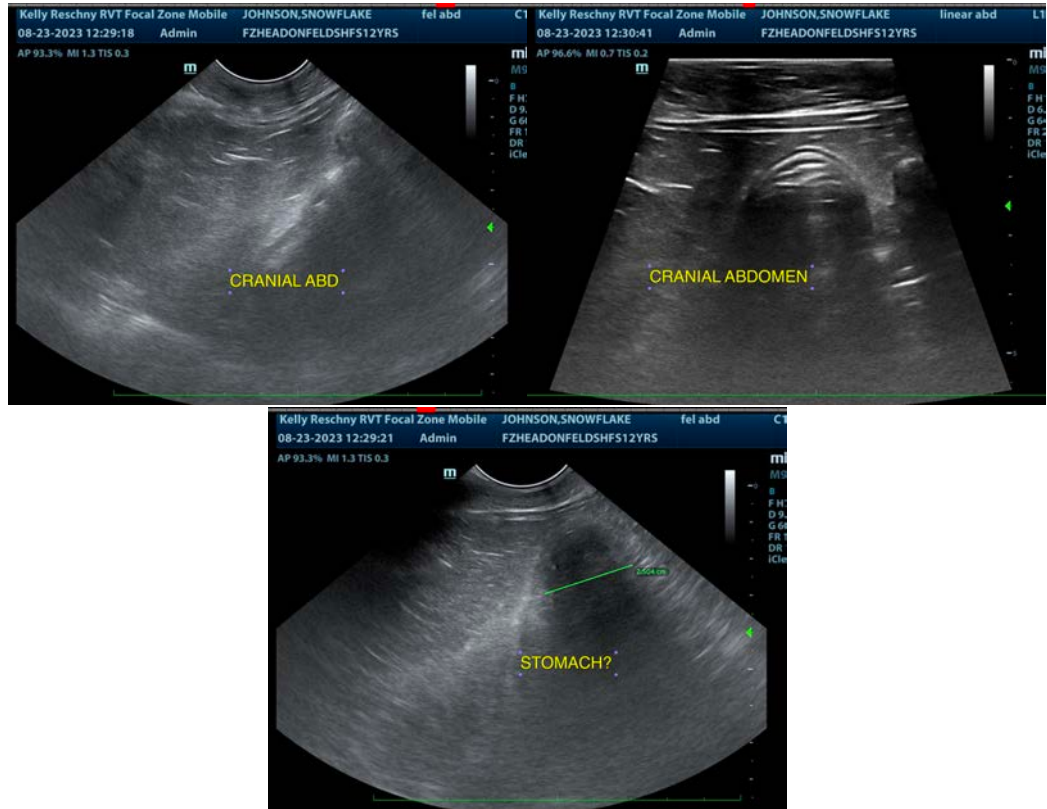Dr. Van Monsjou

INVOICE

44905

DATE

8/23/23



The information and recommendations provided are based on the images presented by the referring veterinarian/sonographer. No evaluation can be communicated regarding pathology that was not visible in the image/video clips provided.

Thank you for this referral. If the clinical or image interpretation does not parallel your findings or if I can be of any further assistance please contact me.

Beth Johnson, DVM, DACVIM
info@sonopath.com