

**PATIENT PRESENTING CLINICAL SIGNS**

Ben Davies Vomiting for the last week hyporexic and liver mass suspected on x rays  
Abnormal PE/Chem/CBC/UA Results: Moderate elevation ALT ALPK.

**SPECIES**

Canine

**BREED**

Schnauzer

**SEX**

Neutered Male

**AGE**

12

**WEIGHT**

13 kg

**INTERPRETED BY**

Beth Johnson, DVM  
DACVIM

**IMAGING PERFORMED BY**

Dr. Belan

**HOSPITAL NAME**

Signal Hill AH

**REFERRING VET**

Dr. Devall

**INVOICE**

44899

**DATE**

8/23/23

**ULTRASONOGRAPHIC EXAMINATION OF THE ABDOMEN**

**Urinary System**

Urinary bladder is adequately distended with primarily anechoic contents and occasional echogenic non-shadowing debris. Apical urinary bladder wall is diffusely thick (0.32 cm thick). Mucosa is hyperechoic and irregular. One cystolith measuring 0.39 cm in diameter is noted along the dependent wall. No masses are observed. The trigone and visible pelvic urethra are normal thickness with a smooth mucosal surface.

Prostate is normal in size, echotexture and echogenicity for a neutered male.

Kidneys are overall normal in size and shape with smooth peripheral margination. A normal 1:3 cortex to medulla ratio is maintained. The medulla and cortices are uniform in texture with some mild increased cortical echogenicity and mild loss of corticomedullary distinction, expected in this age patient. There is no evidence of pyelectasia or infarcts observed. Punctate non-obstructive nephroliths are noted bilaterally. The left kidney measures 5.43 cm. The right kidney measures 4.42 cm.

**Adrenal Glands**

The right adrenal gland is normal in size (0.74 cm at the cranial pole and 0.49 cm at the caudal pole), shape and contour. Corticomedullary structure is unremarkable. Visible surrounding vasculature appears normal.

The left adrenal gland is normal in size (0.69 cm at the cranial pole and 0.56 cm at the caudal pole), shape and contour. Corticomedullary structure is unremarkable. Visible surrounding vasculature appears normal.

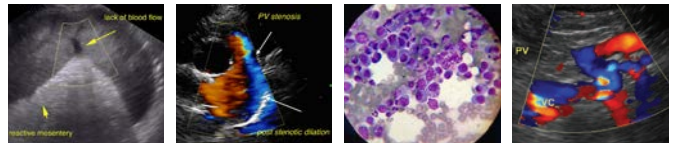
**Spleen**

Spleen is subjectively normal in size with a normal smooth capsular contour. Parenchyma is appropriately finely textured and homogenous with normal echogenicity relative to surrounding tissue (hyperechoic to liver). Multifocal well-demarcated hyperechoic homogenous nodules are noted. Splenic vasculature appears normal.

**Liver**

The liver is subjectively normal in size with normal smooth curvilinear peripheral contour. Parenchyma is appropriately hypoechoic to the spleen in echogenicity and appropriately mildly coarse and homogenous in echotexture. An approximately 7.5 cm in diameter, markedly heterogeneous, cavitated, and visibly vascular mass is noted in the left caudal liver. Visible vasculature and biliary tree appear normal without distension or congestion.

Gallbladder is mildly overdistended with a moderate amount of non-dependent, mildly aggregated/inspissated sludge. Hypo to anechoic cystic areas are noted between the gallbladder sludge and luminal wall. The wall is otherwise smooth without visible thickening. There is no evidence of cystic or CBD dilation. There is no evidence of effusion.



**PATIENT**

***Gastrointestinal***

Ben Davies

The stomach wall is normal in thickness (canine < 0.5 cm and feline < 0.4 cm) and layering. The lumen of the stomach is empty with no evidence of obstruction, foreign material or infiltrative disease. Pyloric outflow tract appears patent.

**SPECIES**

Canine

The visible small intestines are normal in wall thickness and layering (canine duodenum < 0.5 cm and feline duodenum < 0.4 cm; other < 0.3 cm). Small intestinal motility appears adequate (1-3 contractions per min). The lumen of the small intestine is empty with no evidence of obstruction, foreign material or infiltrative disease.

**BREED**

Schnauzer

The visible colon is normal in wall thickness (< 0.2 cm) and layering. Contents are consistent with normal formed feces and gas.

**SEX**

Neutered Male

***Pancreas***

The pancreatic parenchyma is appropriately isoechoic to surrounding tissue. Visible capsule is smooth and normal in contour. There is no visible pancreatic duct dilation. There is no evidence of active peripancreatic inflammation.

**AGE**

12

***Free Abdomen***

**WEIGHT**

13 kg

There is no evidence of free peritoneal effusion noted in these images.

Caudal to the right liver, there is a 1.6 cm x 2.7 cm ovoid cystic structure consistent with a cystic hepatic lymph node.

**INTERPRETED BY**

Beth Johnson, DVM  
DACVIM

There is no evidence of heart base or pericardial pathology noted in these images at this time. If cardiac function evaluation is desired a full echocardiogram is recommended.

**PRIMARY FINDINGS**

**IMAGING PERFORMED BY**

Dr. Belan

- Cavitated heterogeneous liver mass – Concerning for infiltrative neoplasia such as sarcoma versus other. A benign cyst, hematoma, even abscess, etc. is possible and cannot be ruled out without tissue sampling but is considered less likely.

**HOSPITAL NAME**

Signal Hill AH

- The cystic lymph node in the area is concerning for metastatic disease. However, a reactive node can't be ruled out without tissue sampling.

**REFERRING VET**

Dr. Devall

- Emerging mucocele – Cholecystic debris is of unknown clinical significance. It can be seen with biliary stasis from fasting or illness. Cholecystic debris is not necessarily related to hepatobiliary disease. The non-dependent nature of this sludge combined with the cystic areas are suggestive, however, of possible emerging cystic mucosal hyperplasia or early gallbladder mucocele.

**INVOICE**

44899

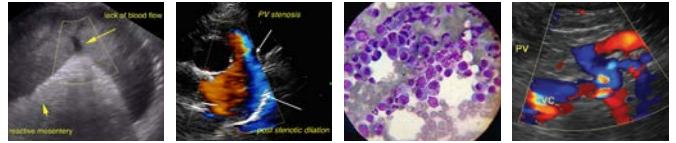
**SECONDARY FINDINGS**

**DATE**

8/23/23

- Chronic Cystitis with one cystolith - Urinary bladder wall changes are most consistent with chronic cystitis. Infiltrative neoplasia cannot be ruled out but is considered less likely given the location and diffuse nature of the changes. The cystolith is likely small enough to pass on its own, although it is of a size considered borderline passable in a small neutered male dog.

- Age related kidney changes with non-obstructive nephroliths bilaterally



**PATIENT**

Ben Davies

- Hyperechoic splenic nodules – most consistent with benign myelolipomas. Other differentials such as fibrosis or calcification caused by old hematomas or infarcts, chronic inflammation, granulomatous disease or metastatic disease cannot be ruled out, but are considered less likely.

**SPECIES**

Canine

**BREED**

Schnauzer

**SEX**

Neutered Male

**AGE**

12

**WEIGHT**

13 kg

**INTERPRETATION OF THE FINDINGS & FURTHER RECOMMENDATIONS**

As is reportedly already pending, three view thoracic radiographs are recommended for further assessment of cardio-pulmonary status as well as to further evaluate for any evidence of metastatic disease, if not recently evaluated.

Sampling of the liver mass +/- the hepatic node could be considered, beginning with a fine needle aspirate if the patient's coagulation status is appropriate. Having said that, given the cavitated nature, hemorrhage is a risk, therefore alternatively an exploratory laparotomy for planned liver lobectomy/excisional biopsy may be considered instead. The liver mass appears resectable. However, the enlarged lymph node is a concern for possible metastatic disease. Having said that, ultrasound alone cannot definitively guarantee resectability, and if surgery is elected, a pre-surgical planning abdominal CT scan could be considered.

If surgery is elected, assessment of the gallbladder and potential cholecystectomy is recommended as well to rule out future progression of the emerging mucocele.

**INTERPRETED BY**

Beth Johnson, DVM  
DACVIM

**IMAGING PERFORMED BY**

Dr. Belan

**HOSPITAL NAME**

Signal Hill AH

**REFERRING VET**

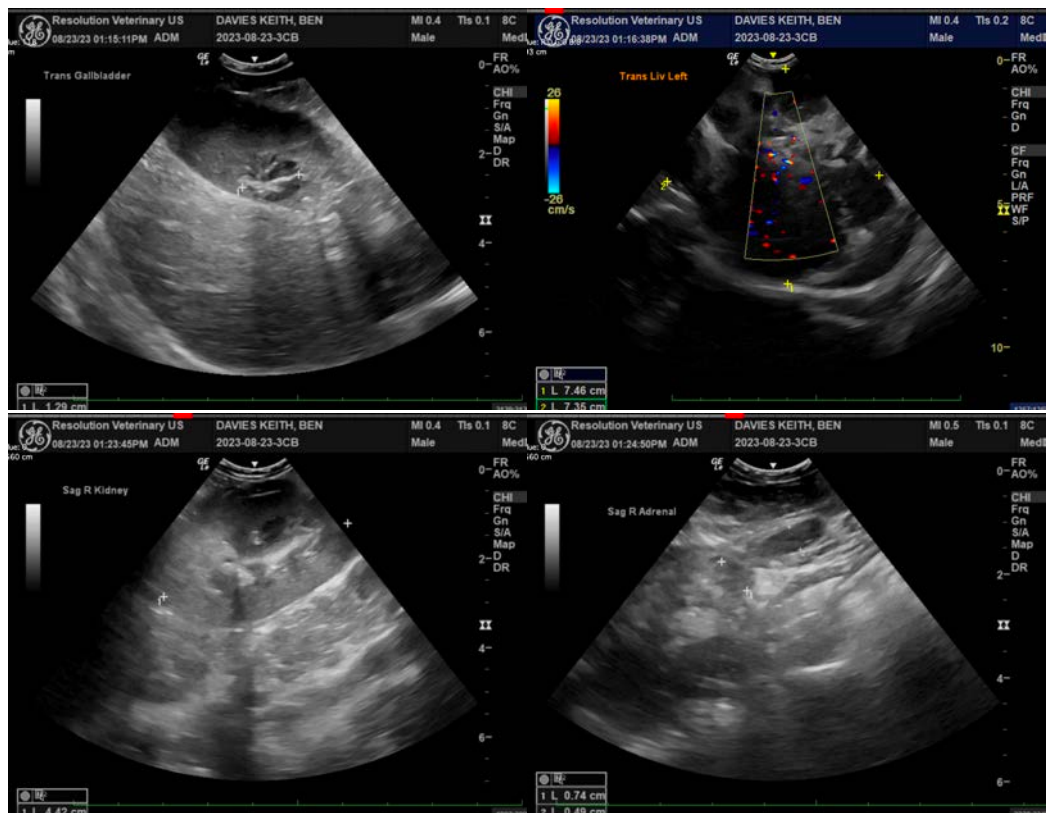
Dr. Devall

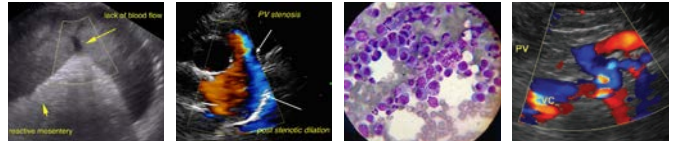
**INVOICE**

44899

**DATE**

8/23/23





**PATIENT**

Ben Davies

**SPECIES**

Canine

**BREED**

Schnauzer

**SEX**

Neutered Male

**AGE**

12

**WEIGHT**

13 kg

**INTERPRETED BY**

Beth Johnson, DVM  
DACVIM

**IMAGING PERFORMED BY**

Dr. Belan

**HOSPITAL NAME**

Signal Hill AH

**REFERRING VET**

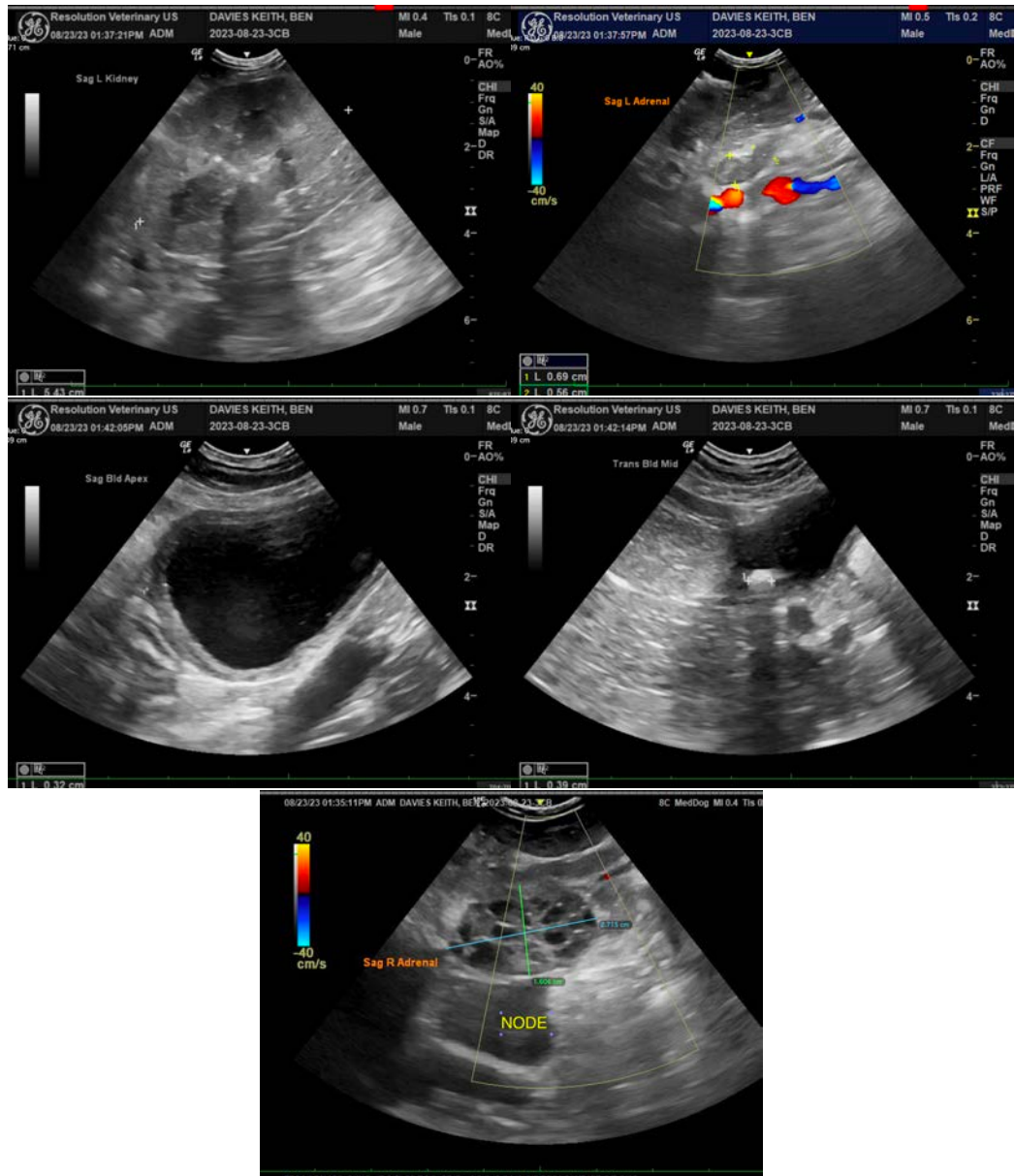
Dr. Devall

**INVOICE**

44899

**DATE**

8/23/23



The information and recommendations provided are based on the images presented by the referring veterinarian/sonographer. No evaluation can be communicated regarding pathology that was not visible in the image/video clips provided.

Thank you for this referral. If the clinical or image interpretation does not parallel your findings or if I can be of any further assistance please contact me.

**Beth Johnson, DVM, DACVIM**  
info@sonopath.com