



**PATIENT**

Lucero Santiago

**SPECIES**

Canine

**BREED**

Shih Tzu

**SEX**

Spayed Female

**AGE**

7 Years

**WEIGHT**

27.4 Pounds

**INTERPRETED BY**

Beth Johnson, DVM  
DACVIM

**IMAGING PERFORMED BY**

Dr. Ferrer

**HOSPITAL NAME**

Paseos Vet Center

**REFERRING VET**

Dr. Denisse De Moya

**INVOICE**

40671

**DATE**

8/23/22

**PRESENTING CLINICAL SIGNS**

Presented as a referral for an abdominal ultrasound. No history or reason was provided. Patient is currently taking Vetmedin 1.25mg SID, Furosemide 12.5mg SID, Enalapril 2.5mg SID, Epakitin 1 scoop SID, Mirtazapine 1.25 SID.

Abnormal PE/Chem/CBC/UA Results: No PE or Lab results were provided.

**ULTRASONOGRAPHIC EXAMINATION OF THE ABDOMEN**

**Urinary System**

Urinary bladder is adequately distended. It has a normal uniform wall thickness. Contents include primarily anechoic fluid with occasional echogenic non-shadowing debris, most consistent with exfoliated cells, mucous and/or small blood clots. Both sterile inflammation as well as urinary tract infection can also present with echogenic debris. No masses or cystoliths are observed. The trigone and visible pelvic urethra are normal in thickness with a smooth mucosal surface.

The right kidney is normal in size (5.24 cm), shape and echogenicity. It has smooth peripheral margination. There is a normal 1:3 cortex to medulla ratio with appropriate corticomedullary distinction. There is no evidence of pyelectasia, mineral or infarcts observed.

The left kidney is normal in size (4.82 cm), shape and echogenicity. It has smooth peripheral margination. There is a normal 1:3 cortex to medulla ratio with appropriate corticomedullary distinction. There is no evidence of pyelectasia or infarcts observed. Non-obstructive linear multifocal hyperechoic diverticular foci with acoustic shadowing are noted.

**Adrenal Glands**

The right adrenal gland is enlarged (2.5 cm long x 1.8 cm wide), involving primarily the cranial pole, with mild heterogenous parenchymal changes. Swollen capsular expansion is noted without evident capsular escape or vascular invasion.

The left adrenal gland is normal in size (0.39 cm at the cranial pole and 0.48 cm at the caudal pole), shape and contour. Corticomedullary structure is unremarkable. Visible surrounding vasculature appears normal.

**Spleen**

Spleen is subjectively normal in size with a normal smooth capsular contour. Parenchyma is appropriately finely textured and homogenous with normal echogenicity relative to surrounding tissue (hyperechoic to liver). Multifocal well-demarcated hyperechoic homogenous nodules are noted. Splenic vasculature appears normal.

**Liver**

Liver is subjectively enlarged with mildly irregular margins. Parenchyma is heterogenous characterized by multiple poorly defined hypoechoic nodules within otherwise hyperechoic liver parenchyma. Visible vasculature and biliary tree appear normal without distension or congestion.

Gallbladder is moderately distended with anechoic bile as well as suspended and gravity dependent echogenic debris. The wall is smooth without visible thickening. There is no evidence of cystic or CBD dilation. There is no evidence of effusion or inflammation.

**Gastrointestinal**



**PATIENT**

Lucero Santiago

The visible stomach wall is normal in thickness and layering. The lumen of the stomach is mildly distended with echogenic non-shadowing luminal contents and gas consistent with normal ingesta. There is no evidence of obstruction, foreign material or infiltrative disease. Pyloric outflow tract appears patent.

**SPECIES**

Canine

The visible small intestines are normal in wall thickness and layering (canine duodenum < 0.5 cm and feline duodenum < 0.4 cm; other < 0.3 cm). Small intestinal motility appears adequate (1-3 contractions per min). The lumen of the small intestine is empty with no evidence of obstruction, foreign material or infiltrative disease.

**BREED**

Shih Tzu

The visible colon is normal in wall thickness (< 0.2 cm) and layering. Contents are consistent with normal formed feces and gas.

**SEX**

Spayed Female

**Pancreas**

The pancreas (primarily the right limb) is prominent (enlarged) in size, hypoechoic to surrounding tissue and irregular in shape with a swollen undulating contour. Enhanced hyperechoic ill-defined surrounding fat is noted.

**AGE**

7 Years

**Free Abdomen**

There is no evidence of free peritoneal effusion noted in these images.

There is no apparent lymphadenopathy noted in these images.

**WEIGHT**

27.4 Pounds

**PRIMARY FINDINGS**

- Acute pancreatitis
- **Right adrenal mass** – consistent with adenoma or possibly hyperplasia. Early pheochromocytoma cannot be ruled out. Interpret in combination with clinical signs of hyperadrenocorticism or other adrenal disease.
- **Heterogenous Liver** – These changes are most consistent with benign processes such as nodular hyperplasia, steroid (vacuolar) hepatopathy, extramedullary hematopoiesis or possibly chronic inflammatory disease and less commonly infiltrative round cell or metastatic neoplasia.
- **Gallbladder debris** - Cholecystic debris is of unknown clinical significance. It can be seen with biliary stasis from fasting or illness. Cholecystic debris is not necessarily related to hepatobiliary disease. Echogenic bile is most commonly an incidental finding in dogs and should be interpreted in combination with clinical signs such as nausea, inappetence, cranial abdominal discomfort and/or laboratory changes such as increased ALP and/or increased Tbili.

**INTERPRETED BY**

Beth Johnson, DVM  
DACVIM

**IMAGING PERFORMED BY**

Dr. Ferrer

**HOSPITAL NAME**

Paseos Vet Center

**REFERRING VET**

Dr. Denisse De Moya

**SECONDARY FINDINGS**

- **Hyperechoic splenic nodules** – most consistent with benign myelolipomas. Other differentials such as fibrosis or calcification caused by old hematomas or infarcts, chronic inflammation, granulomatous disease or metastatic disease cannot be ruled out, but are considered less likely.
- Urinary bladder debris

**INVOICE**

40671

**INTERPRETATION OF THE FINDINGS & FURTHER RECOMMENDATIONS**

**DATE**

8/23/22

It would be helpful to know this patient's history, clinical signs, laboratory changes, etc. to offer appropriate recommendations. However, given the appearance of the ultrasound images, acute pancreatitis is suspected, and recommendations include a quantitative PLI (if not recently evaluated), as



**PATIENT**

Lucero Santiago

well as medical management of pancreatitis with anti-emetics, gastroprotectants, appetite stimulants or nutritional support as needed, pain management, broad spectrum antibiotics, and fluid therapy is recommended. If possible, a fresh frozen plasma transfusion and hyperbaric oxygen therapy (HBOT) could be beneficial. Monitoring of the pancreas with power doppler is recommended to identify possible necrosis as well as other potential sequelae such as abscesses, etc.

**SPECIES**

Canine

The described adrenal gland, liver and gallbladder changes are all suggestive of hyperadrenocorticism. If clinical signs of hyperadrenocorticism, such as polyuria, polydipsia, polyphagia, panting, hair loss, hypertension, etc. are present, testing for hyperadrenocorticism with a LDDS test is warranted. If clinical signs are not present, monitoring is recommended with testing pursued when/if clinical signs develop. If not recently evaluated, blood pressure is recommended. If not recently evaluated, a urinalysis and, if indicated based on urinalysis results, urine culture are also recommended. If protein is present in an otherwise quiet sediment, protein quantification with a urine protein to creatinine ratio is recommended.

**BREED**

Shih Tzu

**SEX**

Spayed Female

**AGE**

7 Years

**WEIGHT**

27.4 Pounds

**INTERPRETED BY**

Beth Johnson, DVM  
DACVIM

**IMAGING PERFORMED BY**

Dr. Ferrer

**HOSPITAL NAME**

Paseos Vet Center

**REFERRING VET**

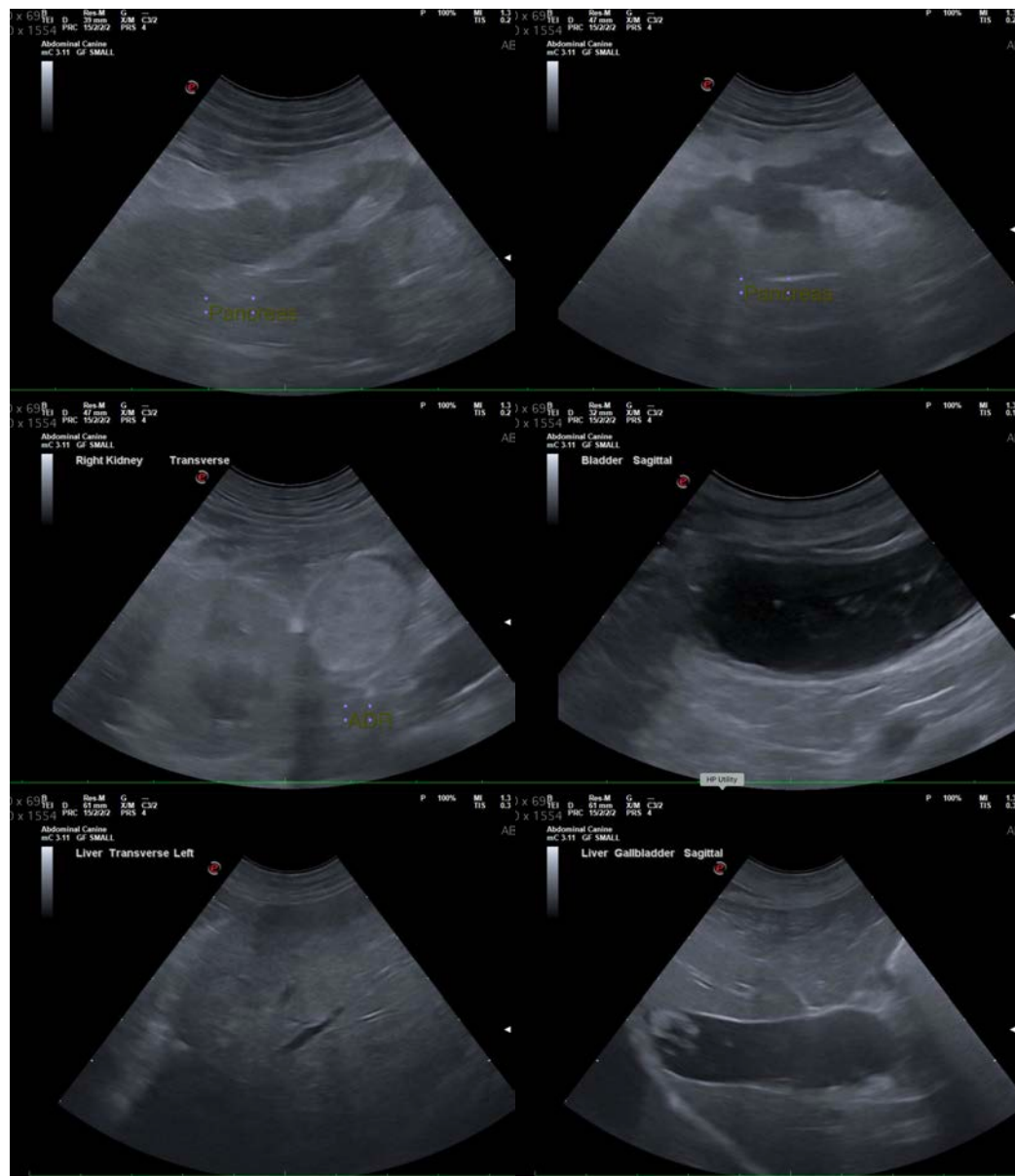
Dr. Denisse De Moya

**INVOICE**

40671

**DATE**

8/23/22





**PATIENT**

Lucero Santiago

**SPECIES**

Canine

**BREED**

Shih Tzu

**SEX**

Spayed Female

**AGE**

7 Years

**WEIGHT**

27.4 Pounds

**INTERPRETED BY**

Beth Johnson, DVM  
DACVIM

**IMAGING PERFORMED BY**

Dr. Ferrer

**HOSPITAL NAME**

Paseos Vet Center

**REFERRING VET**

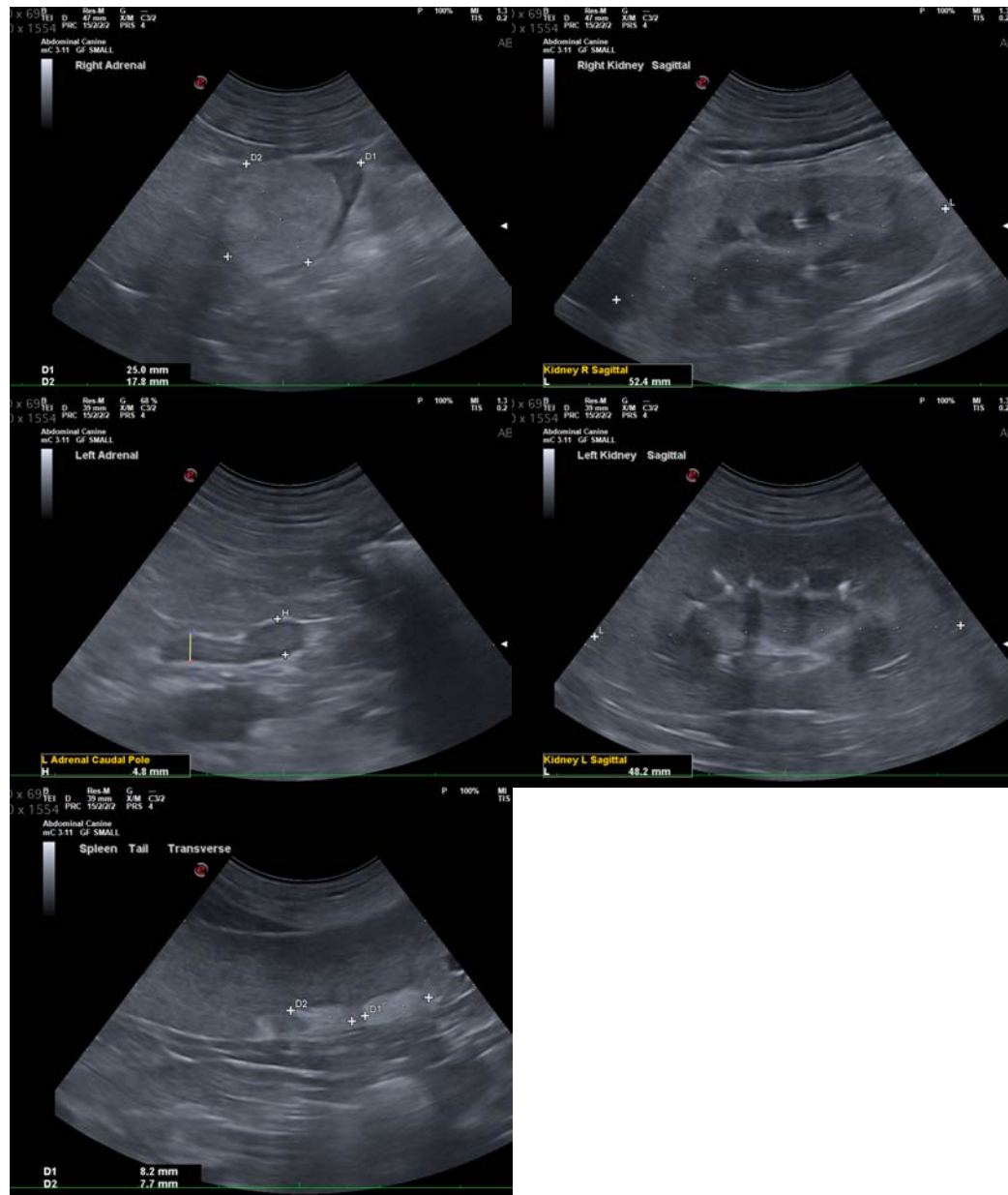
Dr. Denisse De Moya

**INVOICE**

40671

**DATE**

8/23/22



The information and recommendations provided are based on the images presented by the referring veterinarian/sonographer. No evaluation can be communicated regarding pathology that was not visible in the image/video clips provided.

Thank you for this referral. If the clinical or image interpretation does not parallel your findings or if I can be of any further assistance please contact me.

**Beth Johnson, DVM, DACVIM**  
Beth.Johnson@sonopath.com