

IMAGING PERFORMED BY

SVS Mobile Imaging MI 734-637-7711
svsimagingmi@gmail.com



EDUCATIONAL TELECONSULTATION SERVICES™
1-800-838-4268 info@sonopath.com SonoPath.com

PATIENT

Nova Baydoun

SPECIES

Canine

BREED

German Shepherd

SEX

Spayed Female

AGE

5 Years 3 Months

WEIGHT

85.4 Pounds

INTERPRETED BY

Beth Johnson, DVM
DACVIM

IMAGING PERFORMED BY

Amy Mayhew, LVT

HOSPITAL NAME

SVS Imaging MI

REFERRING VET

Dr. Craig

INVOICE

44823

DATE

8/22/23

PRESENTING CLINICAL SIGNS

Urinary incontinence off and on for past 10-12 months. Symptoms resolved after October visit but have started back up again and have been consistent for past 5 months. P will urinate while laying down and does not seem to be aware that she is urinating. No increase in frequency of urination or thirst. No vomiting but o did mention that p has been salivating a lot recently. P is on hydrolyzed protein diet.

Abnormal PE/Chem/CBC/UA Results: Urinalysis and urine culture were unremarkable in October 2022. Urinalysis and bloodwork unremarkable again on 8/18/23. Soft abdomen, non-reactive on palpation over bladder, skin fold around vulva clean/dry.

ULTRASONOGRAPHIC EXAMINATION OF THE ABDOMEN**Urinary System**

The urinary bladder is moderately distended with anechoic contents. No masses, inflammatory changes, echogenic sediment or cystoliths are observed. The urinary bladder, trigone and visible pelvic urethra are normal in thickness with a smooth mucosal surface.

The right kidney is normal in size (7.07 cm), shape and echogenicity. It has smooth peripheral margination. There is a normal 1:3 cortex to medulla ratio with appropriate corticomedullary distinction. There is no evidence of pyelectasia, mineral or infarcts observed.

The left kidney is normal in size (6.88 cm), shape and echogenicity. It has smooth peripheral margination. There is a normal 1:3 cortex to medulla ratio with appropriate corticomedullary distinction. There is no evidence of pyelectasia, mineral or infarcts observed.

Adrenal Glands

The right adrenal gland is normal in size (0.52 cm at the cranial pole and 0.43 cm at the caudal pole), shape and contour. Corticomedullary structure is unremarkable. Visible surrounding vasculature appears normal.

The left adrenal gland is normal in size (0.48 cm at the cranial pole and 0.58 cm at the caudal pole), shape and contour. Corticomedullary structure is unremarkable. Visible surrounding vasculature appears normal.

Spleen

The spleen is subjectively normal in size with a normal smooth capsular contour. Parenchyma is appropriately finely textured and homogenous with normal echogenicity relative to surrounding tissue (hyperechoic to liver). No focal nodules or masses are observed. Splenic vasculature appears normal.

Liver

The liver is subjectively normal in size with normal smooth curvilinear peripheral contour. Parenchyma is appropriately hypoechoic to the spleen in echogenicity and appropriately mildly coarse and homogenous in echotexture. No focal lesions are observed. Visible vasculature and biliary tree appear normal without distension or congestion.

The gallbladder is non-distended in size. The wall is smooth without visible thickening. Luminal contents are primarily anechoic. There is no evidence of cystic or common bile duct dilation.

IMAGING PERFORMED BYSVS Mobile Imaging MI 734-637-7711
svsimagingmi@gmail.com**PATIENT**

Nova Baydoun

SPECIES

Canine

BREED

German Shepherd

SEX

Spayed Female

AGE

5 Years 3 Months

WEIGHT

85.4 Pounds

INTERPRETED BYBeth Johnson, DVM
DACVIM**IMAGING PERFORMED BY**

Amy Mayhew, LVT

HOSPITAL NAME

SVS Imaging MI

REFERRING VET

Dr. Craig

INVOICE

44823

DATE

8/22/23

Gastrointestinal

The stomach wall is normal in thickness (canine < 0.5 cm and feline < 0.4 cm) and layering. The lumen of the stomach is empty with no evidence of obstruction, foreign material or infiltrative disease. Pyloric outflow tract appears patent.

The visible small intestines are normal in wall thickness and layering (canine duodenum < 0.5 cm and feline duodenum < 0.4 cm; other < 0.3 cm). Small intestinal motility appears adequate (1-3 contractions per min). The lumen of the small intestine is empty with no evidence of obstruction, foreign material or infiltrative disease.

The visible colon is normal in wall thickness (< 0.2 cm) and layering. Contents are consistent with normal formed feces and gas.

Pancreas

The pancreatic parenchyma is appropriately isoechoic to surrounding tissue. Visible capsule is smooth and normal in contour. There is no visible pancreatic duct dilation. There is no evidence of active peripancreatic inflammation.

Free Abdomen

There is no evidence of free peritoneal effusion noted in these images.

There is no apparent lymphadenopathy noted in these images.

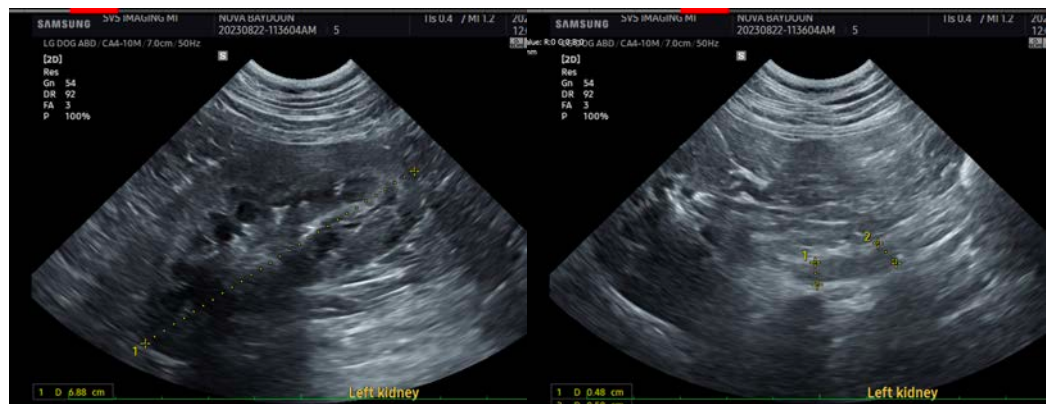
ULTRASONOGRAPHIC FINDINGS

- Relatively unremarkable/normal abdomen without an ultrasonographically visible explanation for this patient's reported urinary incontinence.

INTERPRETATION OF THE FINDINGS & FURTHER RECOMMENDATIONS

There is no structural visible abnormality of the urinary tract in these images currently to help explain this patient's reported incontinence. Differentials include ureteral sphincter mechanism incompetence "spay incontinence" versus underlying neurologic disease versus other.

Empirical medical management of potential "spay incontinence" could be considered with monitoring for improvement.



IMAGING PERFORMED BY

SVS Mobile Imaging MI 734-637-7711
svsimagingmi@gmail.com



EDUCATIONAL TELECONSULTATION SERVICES™
1-800-838-4268 info@sonopath.com SonoPath.com

PATIENT

Nova Baydoun

SPECIES

Canine

BREED

German Shepherd

SEX

Spayed Female

AGE

5 Years 3 Months

WEIGHT

85.4 Pounds

INTERPRETED BY

Beth Johnson, DVM
DACVIM

IMAGING PERFORMED BY

Amy Mayhew, LVT

HOSPITAL NAME

SVS Imaging MI

REFERRING VET

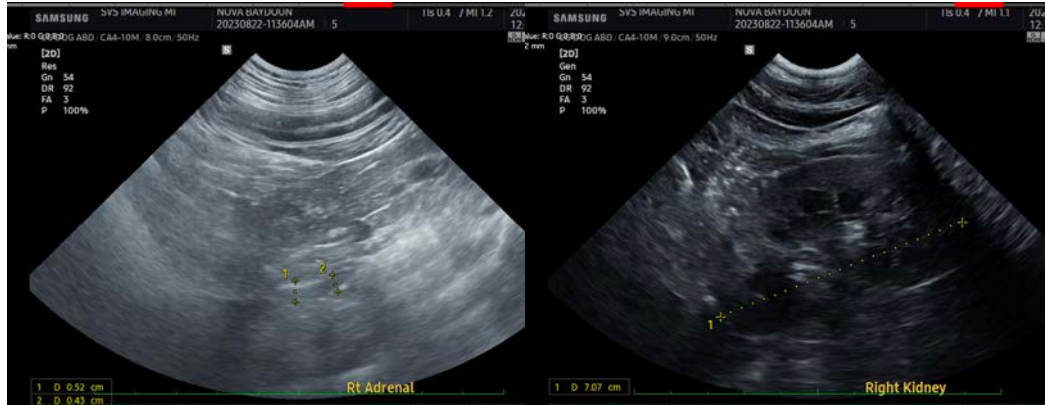
Dr. Craig

INVOICE

44823

DATE

8/22/23



The information and recommendations provided are based on the images presented by the referring veterinarian/sonographer. No evaluation can be communicated regarding pathology that was not visible in the image/video clips provided.

Thank you for this referral. If the clinical or image interpretation does not parallel your findings or if I can be of any further assistance please contact me.

Beth Johnson, DVM, DACVIM
info@sonopath.com