

**PATIENT**

Ellie Smith

**SPECIES**

Canine

**BREED**

Pug X

**SEX**

Spayed Female

**AGE**

10 Years 9 Months

**WEIGHT**

52.4 Pounds

**INTERPRETED BY**Beth Johnson, DVM  
DACVIM**IMAGING PERFORMED BY**

Amy Mayhew, LVT

**HOSPITAL NAME**

SVS Imaging MI

**REFERRING VET**

Dr. Richards

**INVOICE**

44819

**DATE**

8/22/23

**PRESENTING CLINICAL SIGNS**

Last exam done July 2023 - at that time, hx of nonproductive cough/gag for past 1-2 months. Panting, stertor noted (brachycephalic). Poss secondary to obesity and hepatomegaly based on chest rads at that time. Did trial with omeprazole for poss GERD/reflux at that time.

Abnormal PE/Chem/CBC/UA Results: Patient is severely obese which limits abdominal palpation. Recently noted hepatomegaly on chest rads obtained July 2023 for gag/cough. Hx of moderately high Alkaline Phosphatase (886 U/l). Ellie has had this elevation in the past before. Values have doubled in 3 years (470 U/l in 2020). Patient also has history of recurrent interdigital cysts, has improved with Apoquel and occasionally needs abx therapy.

**ULTRASONOGRAPHIC EXAMINATION OF THE ABDOMEN****Urinary System**

The urinary bladder is moderately distended with anechoic contents. No masses, inflammatory changes, echogenic sediment or cystoliths are observed. The urinary bladder, trigone and visible pelvic urethra are normal in thickness with a smooth mucosal surface.

The right kidney is normal in size (6.45 cm), shape and echogenicity. It has smooth peripheral margination. There is a normal 1:3 cortex to medulla ratio with appropriate corticomedullary distinction. There is no evidence of pyelectasia, mineral or infarcts observed.

The left kidney is normal in size (6.13 cm), shape and echogenicity. It has smooth peripheral margination. There is a normal 1:3 cortex to medulla ratio with appropriate corticomedullary distinction. There is no evidence of pyelectasia, mineral or infarcts observed.

**Adrenal Glands**

The right adrenal gland is normal in size (0.75 cm at the cranial pole and 0.63 cm at the caudal pole), shape and contour. A hyperechoic nodule is noted in the mid adrenal gland. Nodule does not disrupt normal shape and/or architecture. Visible surrounding vasculature appears normal.

The left adrenal gland is normal in size (0.61 cm at the cranial pole and 0.71 cm at the caudal pole), shape and contour. A hyperechoic nodule is noted in the cranial pole. Nodule does not disrupt normal shape and/or architecture. Visible surrounding vasculature appears normal.

**Spleen**

The spleen is subjectively normal in size with a normal smooth capsular contour. Parenchyma is appropriately finely textured and homogenous with normal echogenicity relative to surrounding tissue (hyperechoic to liver). No focal nodules or masses are observed. Splenic vasculature appears normal.

**Liver**

Liver is subjectively enlarged (swollen contour) without disruption of architecture. It has a normal homogenous echotexture. Parenchyma is diffusely hyperechoic characterized by less prominent than normal portal vein walls and increased echogenicity relative to the spleen and falciform fat. No focal lesions are observed. Visible vasculature and biliary tree appear normal without distension or congestion.

## IMAGING PERFORMED BY

SVS Mobile Imaging MI 734-637-7711  
svsimagingmi@gmail.com



### PATIENT

Ellie Smith

The gallbladder is non-distended in size. The wall is smooth without visible thickening. Luminal contents are primarily anechoic. There is no evidence of cystic or common bile duct dilation.

### *Gastrointestinal*

### SPECIES

Canine

The visible stomach wall is normal in thickness and layering. The lumen of the stomach is mildly distended with very echogenic reverberation artifact from intraluminal gas. There is no evidence of obstruction, foreign material or infiltrative disease; however, complete visualization of far wall is partially inhibited by gas. Pyloric outflow tract appears patent.

### BREED

Pug X

The visible small intestines are normal in wall thickness and layering. Hyperechoic mucosal fogging or speckling is noted. Small intestinal motility appears adequate (1-3 contractions per min). The lumen is empty with no evidence of obstruction or foreign material.

### SEX

Spayed Female

The visible colon is normal in wall thickness (< 0.2 cm) and layering. Contents are consistent with normal formed feces and gas.

### AGE

10 Years 9 Months

### *Pancreas*

The pancreatic parenchyma is appropriately isoechoic to surrounding tissue. Visible capsule is smooth and normal in contour. There is no visible pancreatic duct dilation. There is no evidence of active peripancreatic inflammation.

### WEIGHT

52.4 Pounds

### *Free Abdomen*

There is no evidence of free peritoneal effusion noted in these images.

### INTERPRETED BY

Beth Johnson, DVM  
DACVIM

There is no apparent lymphadenopathy noted in these images.

### ULTRASONOGRAPHIC FINDINGS

### IMAGING PERFORMED BY

Amy Mayhew, LVT

- **Subtle/mild mucosal speckling** – Mucosal speckling is often present with inflammatory bowel disease (IBD). It is not specific for type or severity of disease. Mild speckling change can occur as a normal patient variant in the post-prandial state.
- **Hyperechoic hepatomegaly** - This appearance is non-specific and most consistent with a benign steroid (endocrine) or vacuolar hepatopathy or reactive or idiopathic hepatopathy. Inflammatory and/or infiltrative disease (such as round cell neoplasia) are also possible, but considered less likely.
- **Bilateral hyperechoic adrenal nodule** – Differentials include primary adrenal cortical adenoma or adenocarcinoma, pheochromocytoma, myelolipoma, adrenal hyperplasia secondary to pituitary disease or metastatic disease. Ultrasound alone cannot differentiate between functional and non-functional nodules and/or between benign and malignant disease. Small nodules without other evidence of abdominal disease (to suggest metastatic disease) and/or clinical signs (to suggest adrenal disease) are most often incidental and should be monitored.

### HOSPITAL NAME

SVS Imaging MI

### REFERRING VET

Dr. Richards

### INVOICE

44819

### INTERPRETATION OF THE FINDINGS & FURTHER RECOMMENDATIONS

### DATE

8/22/23

**Given this patient's history of subtle gastrointestinal signs combined with the mucosal speckling,** a gastrointestinal malabsorption panel (including cobalamin, folate, TLI and PLI) to Texas A&M GI Laboratory is recommended for further evaluation of GI and pancreatic function.

**IMAGING PERFORMED BY**

SVS Mobile Imaging MI SVS - 734 - 637 - 7711  
svsimagingmi@gmail.com



**PATIENT**

Ellie Smith

**SPECIES**

Canine

**BREED**

Pug X

**SEX**

Spayed Female

**AGE**

10 Years 9 Months

**WEIGHT**

52.4 Pounds

**INTERPRETED BY**

Beth Johnson, DVM  
DACVIM

**IMAGING PERFORMED BY**

Amy Mayhew, LVT

**HOSPITAL NAME**

SVS Imaging MI

**REFERRING VET**

Dr. Richards

**INVOICE**

44819

**DATE**

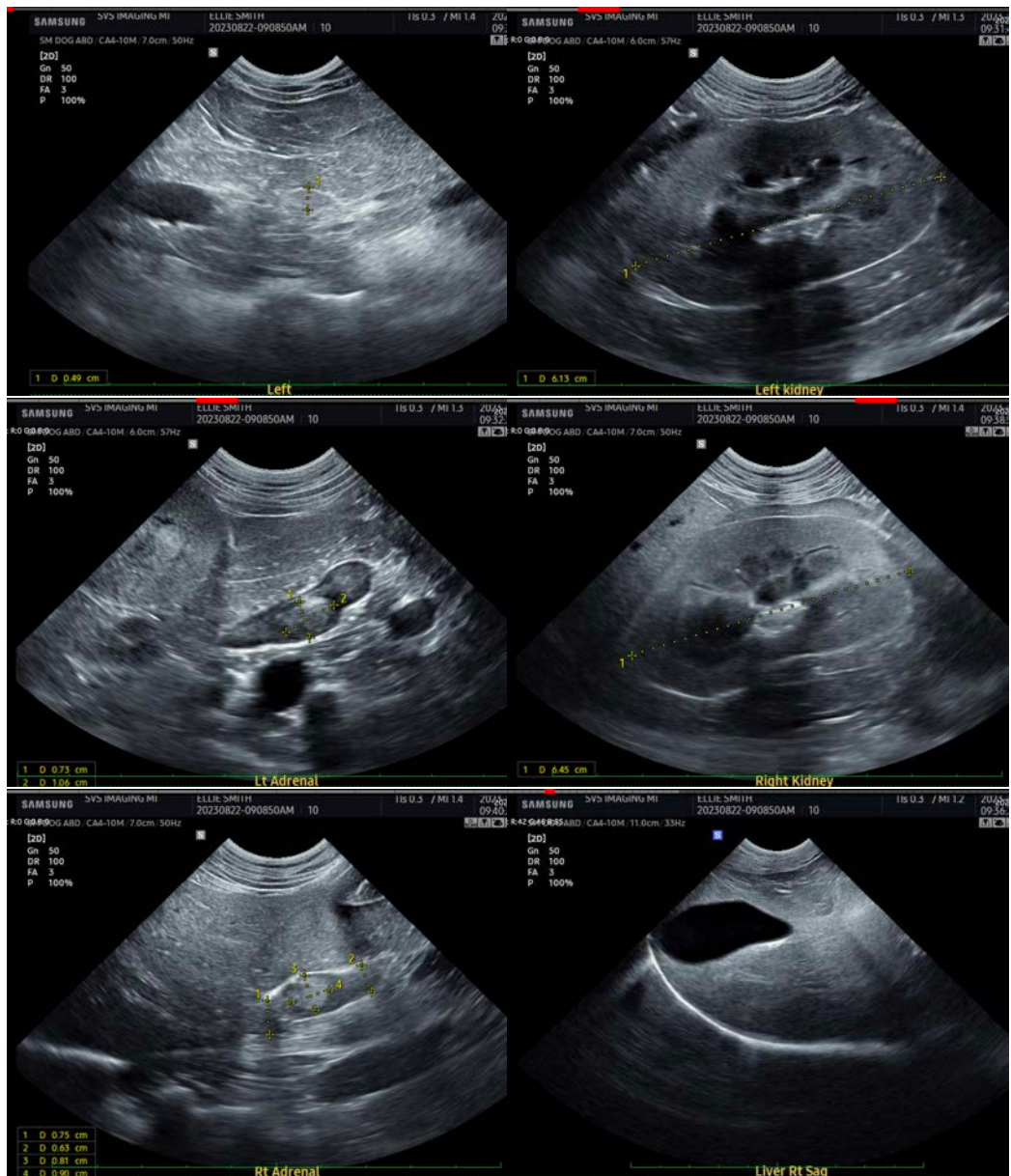
8/22/23

If this patient is exhibiting any clinical signs of hyperadrenocorticism, testing for hyperadrenocorticism could be considered, beginning with a low-dose Dexamethasone suppression test.

If not recently evaluated, a blood pressure is recommended.

In the meantime, if tolerated, transition to a low-fat diet could be considered with monitoring for improvements, in case of chronic smoldering pancreatitis, hypertriglyceridemia, etc. contributing to the clinical signs.

Additionally, empirical deworming with a 5-day course of Panacur is recommended.



**IMAGING PERFORMED BY**

SVS Mobile Imaging MI 734-637-7711  
svsimagingmi@gmail.com



**PATIENT**

Ellie Smith

**SPECIES**

Canine

**BREED**

Pug X

**SEX**

Spayed Female

**AGE**

10 Years 9 Months

**WEIGHT**

52.4 Pounds

**INTERPRETED BY**

Beth Johnson, DVM  
DACVIM

**IMAGING PERFORMED BY**

Amy Mayhew, LVT

**HOSPITAL NAME**

SVS Imaging MI

**REFERRING VET**

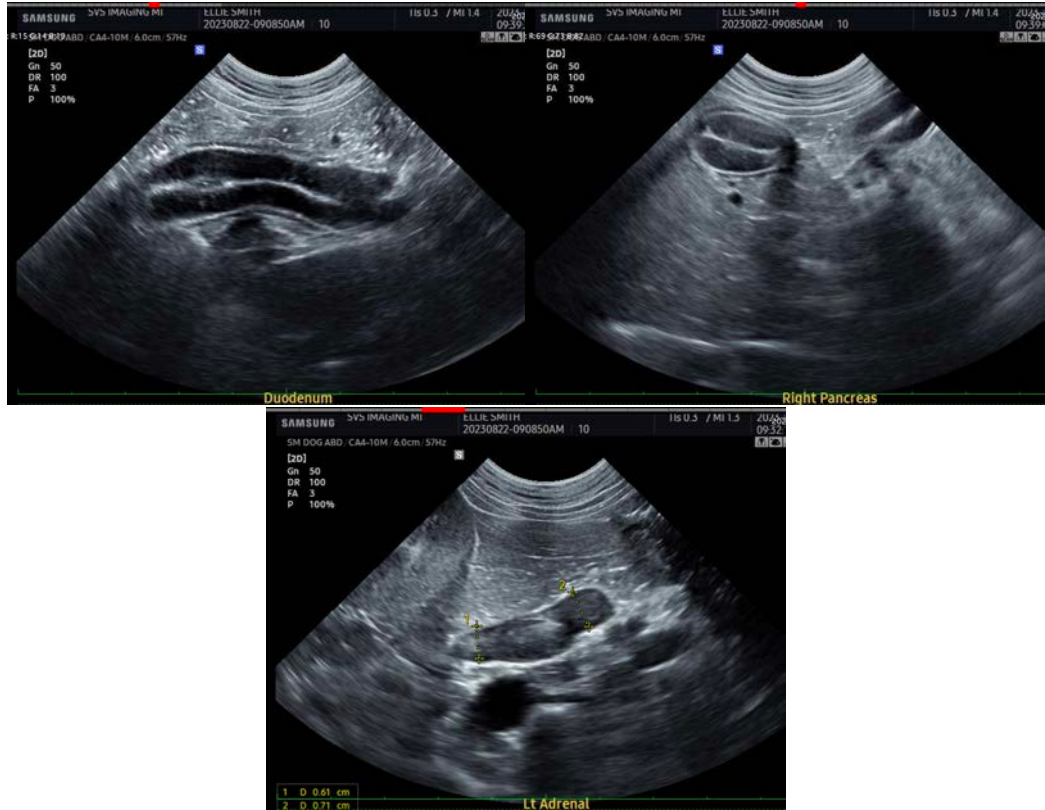Dr. Richards

**INVOICE**

44819

**DATE**

8/22/23



The information and recommendations provided are based on the images presented by the referring veterinarian/sonographer. No evaluation can be communicated regarding pathology that was not visible in the image/video clips provided.

Thank you for this referral. If the clinical or image interpretation does not parallel your findings or if I can be of any further assistance please contact me.

**Beth Johnson, DVM, DACVIM**  
info@sonopath.com