**DATE PRESENTING CLINICAL SIGNS**

8/22/23

Dillon moved to the area and was 1st seen in April 2023. He was previously diagnosed with diabetes which was managed by diet. A senior profile was performed in April and Dillon was diagnosed with hyperthyroidism. He did not respond well to methimazole. GI signs occurred. Several months went by with changes in medication determined by blood work and conversation. Finally, decided Dillon needed to be seen in person.

PATIENT

Dillon Hull

SPECIES

Feline

Current Medications: Erythromycin O/O 1/8oz-Instill a strip of ointment into the right eye every 12 hours until resolved.

Lab Results: Controlled hyperthyroidism?? Anemia. Stopped methimazole 8.2.23

Date of Previous IntraPet Ultrasound: No previous.

Sedation: Not required to complete full diagnostic ultrasound.

Stat Report: Declined.

Imaging Performed By: Stephanie Warga RDCS, RVT.

BREED

DSH

SEX

Neutered Male

ULTRASONOGRAPHIC EXAMINATION OF THE ABDOMEN**Urinary System**

Urinary bladder is adequately distended. It has a normal uniform wall thickness. Contents include primarily anechoic fluid with occasional echogenic non-shadowing debris, most consistent with incidental suspended lipid in a cat, possibly combined with exfoliated cells, mucous and/or small blood clots. Both sterile inflammation as well as urinary tract infection can also present with echogenic debris. No masses or cystoliths are observed. The trigone and visible pelvic urethra are normal in thickness with a smooth mucosal surface.

AGE

6/1/06

WEIGHT

10 Pounds

INTERPRETED BYBeth Johnson, DVM
DACVIM

Kidneys are overall normal in size and shape with smooth peripheral margination. A normal 1:3 cortex to medulla ratio is maintained. The medulla and cortices are uniform in texture with some mild increased cortical echogenicity and mild loss of corticomedullary distinction, expected in this age patient. There is no evidence of pyelectasia or infarcts observed. The left kidney measures 4.06 cm. Several non-obstructive nephroliths are noted in the kidney between 0.60-0.70 cm in size. The right kidney measures 3.38 cm.

HOSPITAL NAME

Festival Vet Clinic

Adrenal Glands

The right adrenal gland is normal in size (0.33 cm), shape and contour. Corticomedullary structure is unremarkable. Visible surrounding vasculature appears normal.

REFERRING VET

Dr. Cianelli

The left adrenal gland is normal in size (0.51 cm), shape and contour. Corticomedullary structure is unremarkable. Visible surrounding vasculature appears normal.

Spleen

The spleen is subjectively normal in size with a normal smooth capsular contour. Parenchyma is appropriately finely textured and homogenous with normal echogenicity relative to surrounding tissue (hyperechoic to liver). No focal nodules or masses are observed. Splenic vasculature appears normal.

INVOICE

44833

Liver

The liver is subjectively normal in size with normal smooth curvilinear peripheral contour. Parenchyma is appropriately hypoechoic to the spleen in echogenicity and appropriately mildly coarse and homogenous in echotexture. No focal lesions are observed. Visible vasculature and biliary tree appear normal without distension or congestion.

The gallbladder is non-distended in size. The wall is smooth without visible thickening. Luminal contents are primarily anechoic. There is no evidence of cystic or common bile duct dilation.

Gastrointestinal

The stomach wall is normal in thickness (canine < 0.5 cm and feline < 0.4 cm) and layering. The lumen of the stomach is empty with no evidence of obstruction, foreign material or infiltrative disease. Pyloric outflow tract appears patent.

Diffusely, the visible small intestines are normal in wall thickness and layering (canine duodenum < 0.5 cm and feline duodenum < 0.4 cm; other < 0.3 cm). However, in the mid to cranial abdomen there is a large, almost 10.0 cm long bowel mass characterized by a thick (measuring between 1.0-1.5 cm thick) concentrically hypoechoic wall and complete loss of mural detail. The mass is surrounded by enhanced mesenteric fat and a trace amount of anechoic free fluid. Small intestinal motility appears adequate (1-3 contractions per min). The lumen of the small intestine is empty with no evidence of obstruction, foreign material or infiltrative disease.

The visible colon is normal in wall thickness (< 0.2 cm) and layering. Contents are consistent with normal formed feces and gas.

Pancreas

The observed pancreas is prominent (enlarged) in size, hypoechoic to surrounding tissue and irregular in shape with a swollen undulating contour. Enhanced hyperechoic ill-defined surrounding fat is noted.

Free Abdomen

There is a trace amount of anechoic free fluid and enhanced hyperechoic mesenteric fat surrounding the bowel mass. Mesenteric lymphadenopathy is also observed.

PRIMARY FINDINGS

- Large, almost 10.0 cm long small bowel mass – concerning for infiltrative neoplasia such as lymphoma versus carcinoma versus other. A benign inflammatory lesion is possible but considered exceedingly less likely.
- Focal peritonitis characterized by a trace amount of free fluid and enhanced mesenteric fat surrounds the bowel mass.
- Lymphadenopathy in the area could be reactive. However, infiltrative neoplasia (i.e., lymphoma) can't be ruled out without tissue sampling.
- Concurrent mild or emerging acute pancreatitis is also possible. However, some of the inflammatory changes surrounding the pancreas are likely from the bowel mass versus pancreatitis.

SECONDARY FINDINGS

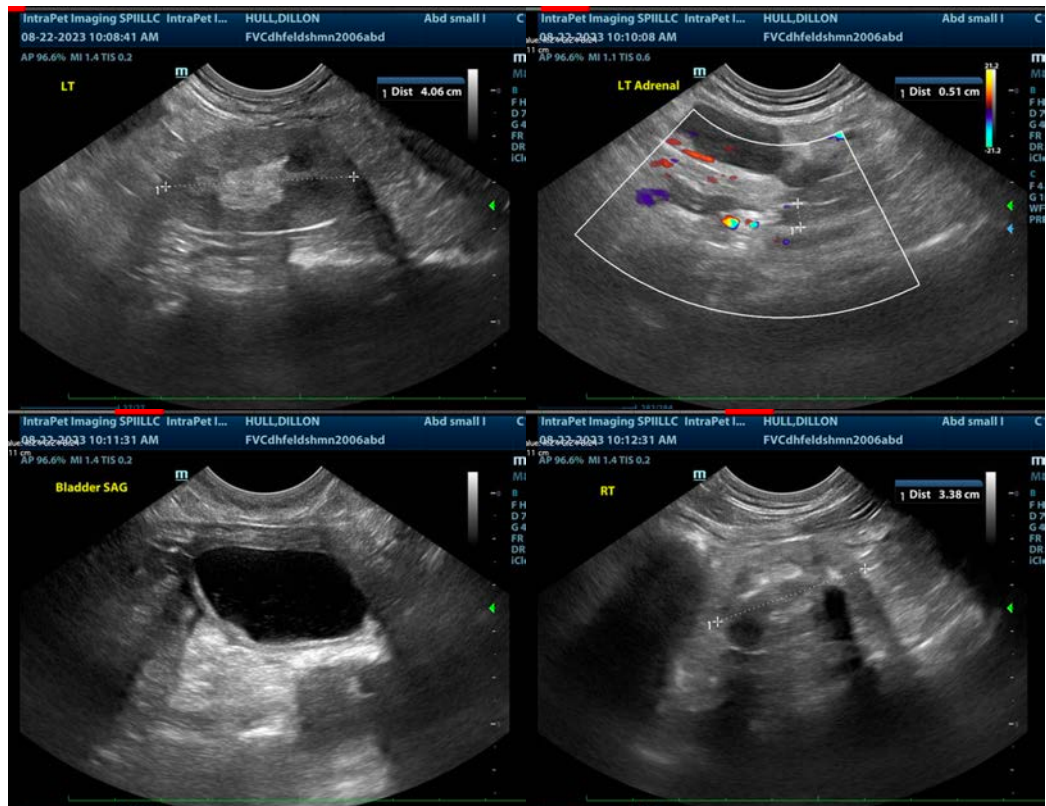
- Age related kidney changes
- Urinary bladder debris

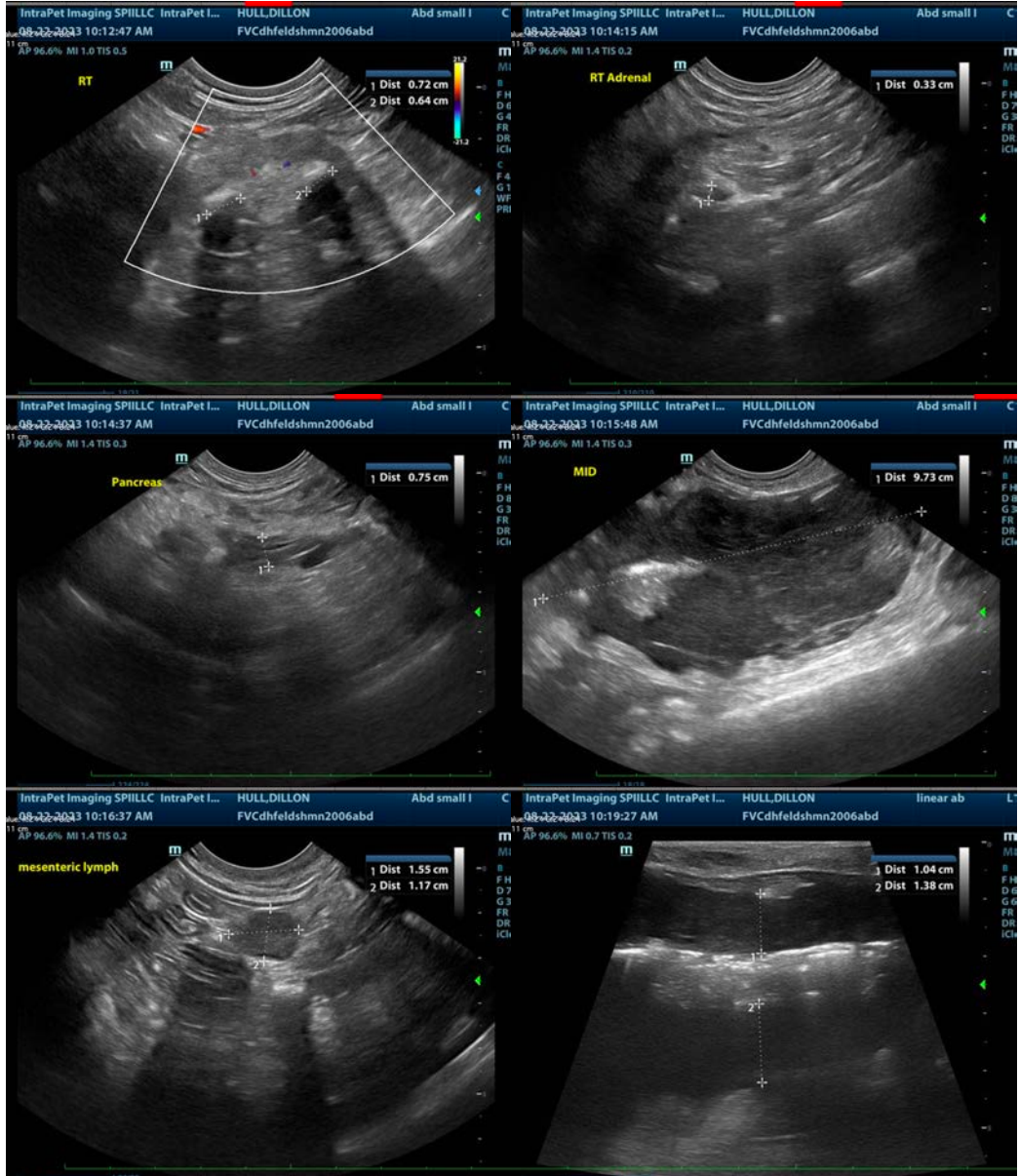
INTERPRETATION OF THE FINDINGS & FURTHER RECOMMENDATIONS

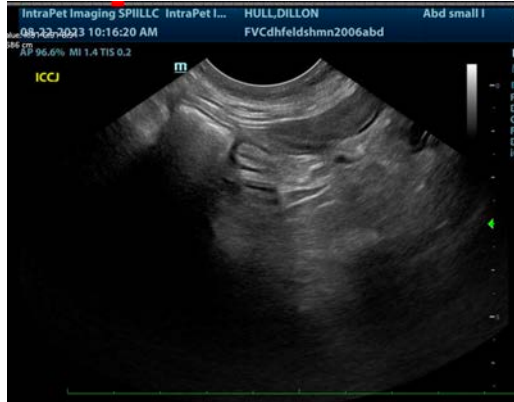Three view thoracic radiographs are recommended for further assessment of cardio-pulmonary status as well as to further evaluate for any evidence of metastatic disease, if not recently evaluated.

A fine needle aspirate of the bowel mass could be considered if patient's coagulation status is appropriate in case the mass is round cell neoplasia (i.e., lymphoma) and could potentially be managed medically.

If a diagnosis cannot be obtained cytologically, however, and/or there is any evidence of a septic abdomen resulting in the free fluid and enhanced mesentery, based on sampling, an exploratory laparotomy may be indicated for an excisional biopsy/resection and anastomosis. The mass is focal and does not appear to involve the ileoceccocolic junction, lending toward resectability. However, given the large size, resectability success is difficult to definitively guarantee ultrasonographically. Consultation with a veterinary surgeon could be considered.







The information and recommendations provided are based on the images presented by the referring veterinarian/sonographer. No evaluation can be communicated regarding pathology that was not visible in the image/video clips provided.

Thank you for this referral. If the clinical or image interpretation does not parallel your findings or if I can be of any further assistance please contact me.

Beth Johnson, DVM, DACVIM
info@sonopath.com