

DATE

8/22/22

PATIENT

Rogue Fleming

SPECIES

Canine

BREED

Pitbull mix

SEX

Spayed female

AGE

5/14/12

WEIGHT

64.6 lbs

INTERPRETED BY

Beth Johnson, DVM
DACVIM

HOSPITAL NAME

Animal Emergency
Hospital

REFERRING VET

Dr. Thomson

INVOICE

32437

PRESENTING CLINICAL SIGNS

Rogue is a 10 y/o FS pit bull who was referred for elevated kidney values - was doing well had annual on Aug 1st - last few days was not acting like her usual self, did not do her usual eating routine - did not eat yesterday morning, vomited once - ate this am, bland diet, no kibble - no further vomiting since yesterday - no diarrhea/bm - drinking more - hx allergies - UTD on vx ALB 1.3, BUN 75, Creat 3.2, P 6.2, SDMA 25, UA suspected bacteria USG 1.017 Medications: - amoxicillin - proviable - apoquel - F/T monthly Current Medications: Gabapentin, Metronidazole. Ondansetron, Amoxicillin, Protonix.

Lab Results: See attached.

Radiographs: Stomach full of food or foreign material, mild gas pattern throughout GIT, no overt FB or obstructive pattern.

Date of Previous IntraPet Ultrasound: No previous.

Sedation: Not required to complete full diagnostic ultrasound.

Stat Report: Not requested.

Imaging Performed By: Rachel Brillhart, RDMS.

ULTRASONOGRAPHIC EXAMINATION OF THE ABDOMEN

Urinary System

Urinary bladder is only mildly distended (empty). Visible contents are anechoic. Urinary bladder wall is unable to be fully assessed for pathology without further distension. No visible masses or cystoliths are observed. The trigone and visible pelvic urethra are normal thickness with a smooth mucosal surface. If there are urinary signs and/or concern for urinary bladder pathology, reassessment after complete filling is recommended.

Left kidney is normal is size (6.23 cm), shape and echogenicity. It has smooth peripheral margination. There is a normal 1:3 cortex to medulla ratio with appropriate corticomedullary distinction. There is no evidence of pyelectasia, mineral or infarcts observed.

Right kidney is normal is size (6.38 cm), shape and echogenicity. It has smooth peripheral margination. There is a normal 1:3 cortex to medulla ratio with appropriate corticomedullary distinction. There is no evidence of pyelectasia, mineral or infarcts observed.

Adrenal Glands

Left adrenal gland is normal in size (2.77 cm long, 0.74 cm at cranial pole and 0.77 cm at caudal pole), shape and overall architecture, echogenicity and echotexture. Visible surrounding vasculature appears normal.

Right adrenal gland is normal in size (3.15 cm long, 0.89 at cranial pole and 0.97 cm at caudal pole), shape and overall architecture, echogenicity and echotexture. Visible surrounding vasculature appears normal.

Spleen

Spleen is subjectively normal in size with a normal smooth capsular contour. Parenchyma is appropriately finely textured and homogenous with normal echogenicity relative to surrounding tissue (hyperechoic to liver). No focal nodules or masses are observed. Splenic vasculature appears normal.

Liver

Liver is subjectively enlarged with mildly irregular margins. Parenchyma is heterogenous characterized by multiple poorly defined hypoechoic nodules within otherwise hyperechoic liver parenchyma. Visible vasculature and biliary tree appear normal without distension or congestion.

Gallbladder is non-distended in size. The wall is edematous. Luminal contents are primarily anechoic. There is no evidence of cystic or common bile duct dilation.

Gastrointestinal

The visible stomach wall is increased in thickness measuring up to 1.5 cm thick with a diffusely hypoechoic appearance to the wall and mild/slight loss of mural detail is appreciated. The lumen of the stomach is mildly distended with echogenic non-shadowing luminal contents and gas consistent with normal ingesta. There is no evidence of obstruction, foreign material or infiltrative disease. Pyloric outflow tract appears patent.

The visible small intestines are normal in wall thickness and layering. Small intestinal motility appears adequate (1-3 contractions per min). The lumen of the small intestine is empty with no evidence of obstruction, foreign material or infiltrative disease.

The visible colon is normal in wall thickness (< 0.2 cm) and layering. Contents are consistent with normal formed feces and gas.

Pancreas

The observed pancreas is markedly prominent (enlarged) in size, hypoechoic to the surrounding tissue and irregular in shape with a swollen, undulating contour. Parenchyma is coarse with mixed, echogenic remodeling. Enhanced, hyperechoic, ill-defined, surrounding fat is noted. Decreased blood flow is suspected based on power Doppler images.

Free Abdomen

There is a small amount of anechoic free fluid as well.

There is no apparent lymphadenopathy noted in these images.

ULTRASONOGRAPHIC FINDINGS

Primary Findings

- **Severe, acute pancreatitis** with early pancreatic necrosis unable to be definitively ruled out.
- **Diffusely thick gastric** wall with some loss of mural detail. Differentials include both severe edematous change/gastritis secondary to pancreatitis as well as infiltrative inflammatory or even less likely neoplastic disease can be ruled out.
- **Heterogenous Liver** – These changes are most consistent with benign processes such as nodular hyperplasia, steroid (vacuolar) hepatopathy, extramedullary hematopoiesis or possibly chronic inflammatory disease and less commonly infiltrative round cell or metastatic neoplasia.
- **Edematous gallbladder wall**, likely due to free abdominal fluid and surrounding inflammation; however, concurrent cholangitis cannot be ruled out.

INTERPRETATION OF THE FINDINGS & FURTHER RECOMMENDATIONS

The cause of the patient's acute change in clinical signs appears most likely secondary to severe pancreatitis and gastritis versus the reported chronic renal disease. Therefore, recommendations include medical management of pancreatitis with anti-emetics, gastroprotectants, appetite stimulants or nutritional support as needed, pain management, broad spectrum antibiotics, and fluid therapy is recommended. If possible, a fresh frozen plasma transfusion and hyperbaric oxygen therapy (HBOT) could be beneficial. Monitoring of

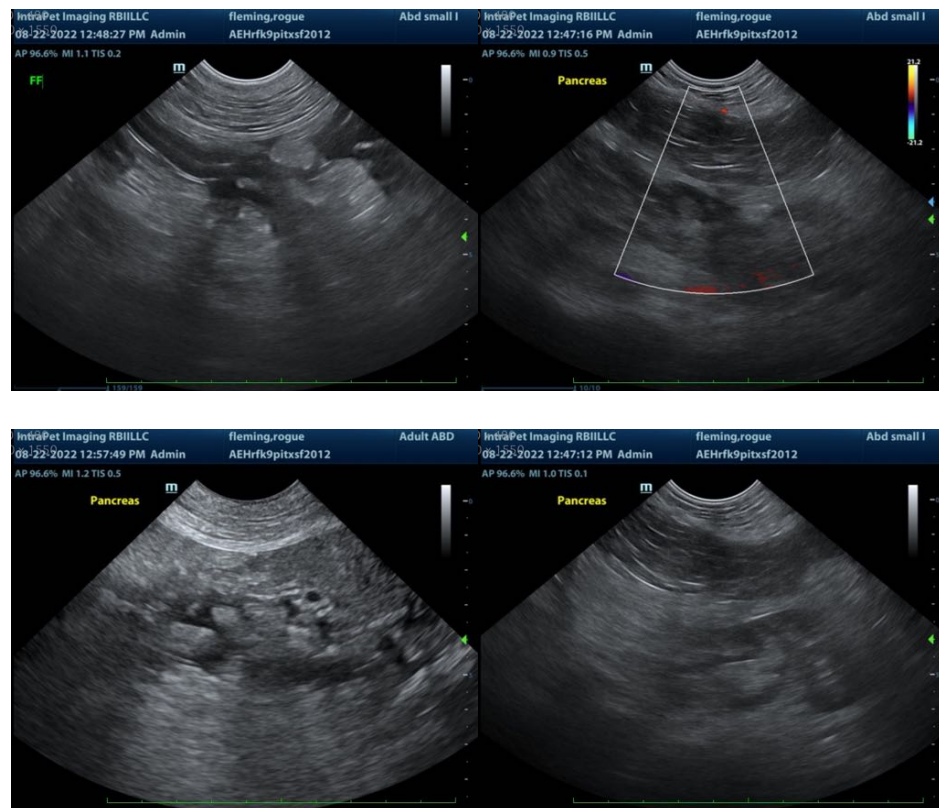
the pancreas with power doppler is recommended to identify possible necrosis as well as other potential sequelae such as abscesses, etc.

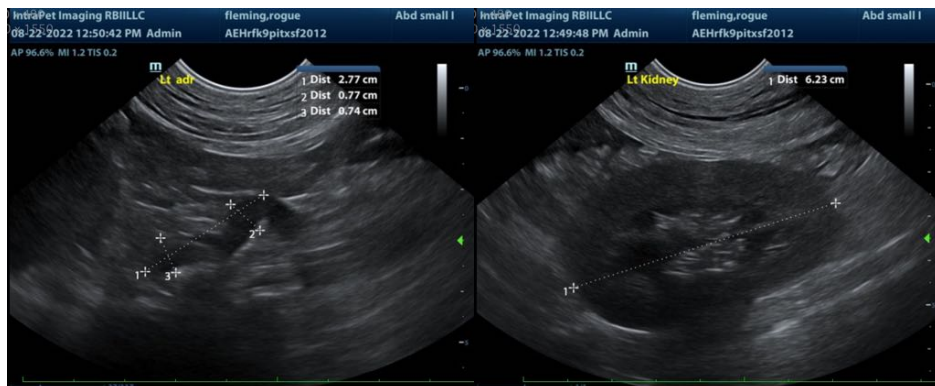
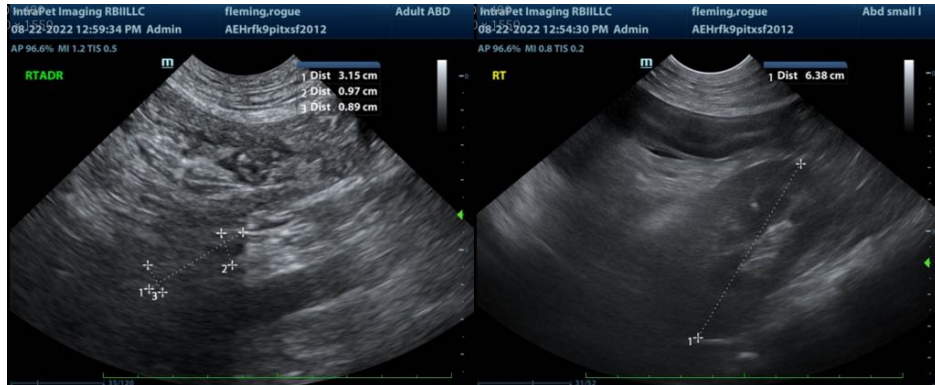
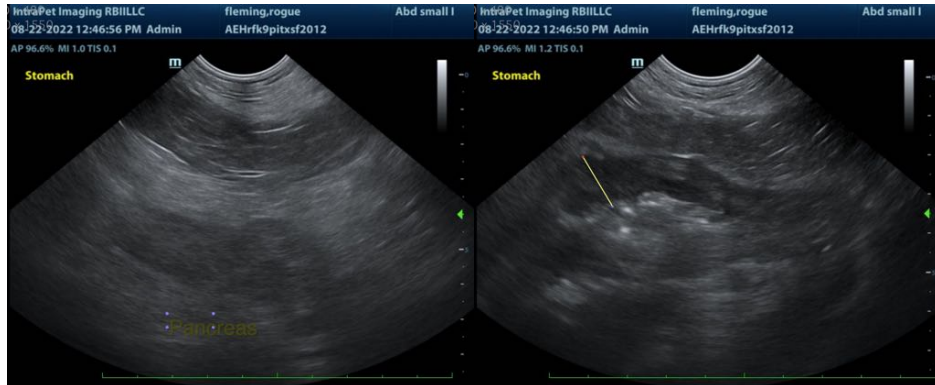
Quantitative PLI is recommended if not already evaluated.

Given the new hypoalbuminemia which is most likely secondary to the pancreatitis, if proteinuria is present with an otherwise quiet sediment a urine protein to creatinine ratio is recommended to quantify the protein loss.

Blood pressure is also recommended if not recently evaluated. Testing for Leptospirosis is also warranted for further evaluation of the renal disease.

Following management of this patient's pancreatitis and resolution of the clinical signs recheck imaging of the gastric wall can be considered and if the thickness is still present a FNA can be considered at that time if the patient's coagulation status is appropriate.





The information and recommendations provided are based on the images presented by the referring veterinarian. No evaluation can be communicated regarding pathology that was not visible in the image/video clips provided.

Thank you for this referral. If the clinical or image interpretation does not parallel your findings or if I can be of any further assistance please contact me.

Beth Johnson, DVM DACVIM
Beth.Johnson@SonoPath.com