**DATE**

8/22/22

**PRESENTING CLINICAL SIGNS**

History: Complaint: Excessive panting, weight loss. Pale pink mm, harsh lung sounds, multiple subq masses, absent CPs in hind legs, abdominal mass effect in right cranial abdomen

**PATIENT**

Achilles Gunther

**SPECIES**

Canine

**BREED**

American Bulldog

**SEX**

Neutered Male

**AGE**

6/15/10

**WEIGHT**

73 Pounds

**INTERPRETED BY**Beth Johnson, DVM  
DACVIM**HOSPITAL NAME**

Eastern AH

**REFERRING VET**

Dr. Cusack

**INVOICE**

16981

Current Medications: Dasuquin advanced, To start enalapril 15mg PO BID.

Lab Results: 6/25/22 CBC/Chem: ALT 396, ALP 6-2, globulins 3.7, amylase 1851, psl 260, platelets 509, remainder wnl. 6/25/22: mineralization of tracheal rings, pulmonary osteomas. 7/19/22 UA: SG 1.025, ph 7.5, prot 4+, bilirubin 1+, wbc 0-1, rbc 0-1, amorphous phosphate crystals 2-3. 7/19/22: Negative urine culture. 7/19/22: UPC 3.9. 7/23/22 LDDS: Pre: 4.2, 4 hrs: 0.4, 8.0 hrs: 1.0

Date of Previous IntraPet Ultrasound: No previous.

Sedation: Not required to complete full diagnostic ultrasound.

Stat Report: Not requested.

Imaging Performed By: Rachel Brillhart, RDMS.

**ULTRASONOGRAPHIC EXAMINATION OF THE ABDOMEN****Urinary System**

Urinary bladder is adequately distended with anechoic contents. No masses, inflammatory changes, echogenic sediment or cystoliths are observed. The urinary bladder, trigone and visible pelvic urethra are normal in thickness with a smooth mucosal surface.

The area of the prostate is examined without evident pathology.

Left kidney is normal in size (9.07 cm long), shape and echogenicity. It has smooth peripheral margination. There is a normal 1:3 cortex to medulla ratio with appropriate corticomedullary distinction. There is no evidence of pyelectasia, mineral or infarcts observed. Several small cortical cysts are present.

Right kidney is almost completely displaced by a 9.0 cm x 11.0 cm walled off structure filled with echogenic fluid encompassing the cranial pole of the right kidney. A small amount of solid tissue is present at the caudal pole of the right kidney but there is no normal architecture appreciated. The structure does not appear to have blood flow.

**Adrenal Glands**

Left adrenal gland is normal in size (3.0 cm long x 0.94 cm at cranial pole and 0.93 cm at caudal pole), shape and overall architecture, echogenicity and echotexture. Visible surrounding vasculature appears normal.

Right adrenal gland is normal in size (3.87 cm long x 0.87 cm at cranial pole and 0.78 cm at caudal pole), shape and overall architecture, echogenicity and echotexture. Visible surrounding vasculature appears normal.

**Spleen**

Spleen is subjectively large in size with normal smooth margins. Parenchyma is normal in echogenicity with a coarse/heterogenous echotexture. An approximately 2.0 cm x 2.5 cm hypoechoic partially cavitated nodule is noted in the mid body. Splenic vasculature appears normal.

**Liver**

The liver contains a very large (at least 20 cm in diameter) mixed heterogeneous irregular mass in the mid caudal liver, just caudal to the gallbladder. There is some more normal appearing liver architecture cranially along the diaphragm.

Gallbladder is non-distended in size. The wall is smooth without visible thickening. Luminal contents are primarily anechoic. There is no evidence of cystic or common bile duct dilation.

### ***Gastrointestinal***

The visible stomach wall is normal in thickness and layering. The lumen of the stomach is empty with no evidence of obstruction, foreign material or infiltrative disease. Pyloric outflow tract appears patent.

The visible small intestines are normal in wall thickness and layering. Small intestinal motility appears adequate (1-3 contractions per min). The lumen of the small intestine is empty with no evidence of obstruction, foreign material or infiltrative disease.

The visible colon is normal in wall thickness and layering. Contents are consistent with normal formed feces and gas.

### ***Pancreas***

The observed pancreas appears appropriately isoechoic to surrounding omental fat. Visible capsule is smooth and normal in contour. Visible pancreatic parenchyma is homogenous and unremarkable. There is no visible pancreatic duct dilation. There is no evidence of active peripancreatic inflammation.

### ***Free Abdomen***

There is a scant amount of anechoic free fluid around the spleen. No appreciable lymphadenopathy. No evidence of pericardial effusion or visual evidence of macroscopic metastatic disease of the heart present in these images.

## **ULTRASONOGRAPHIC FINDINGS**

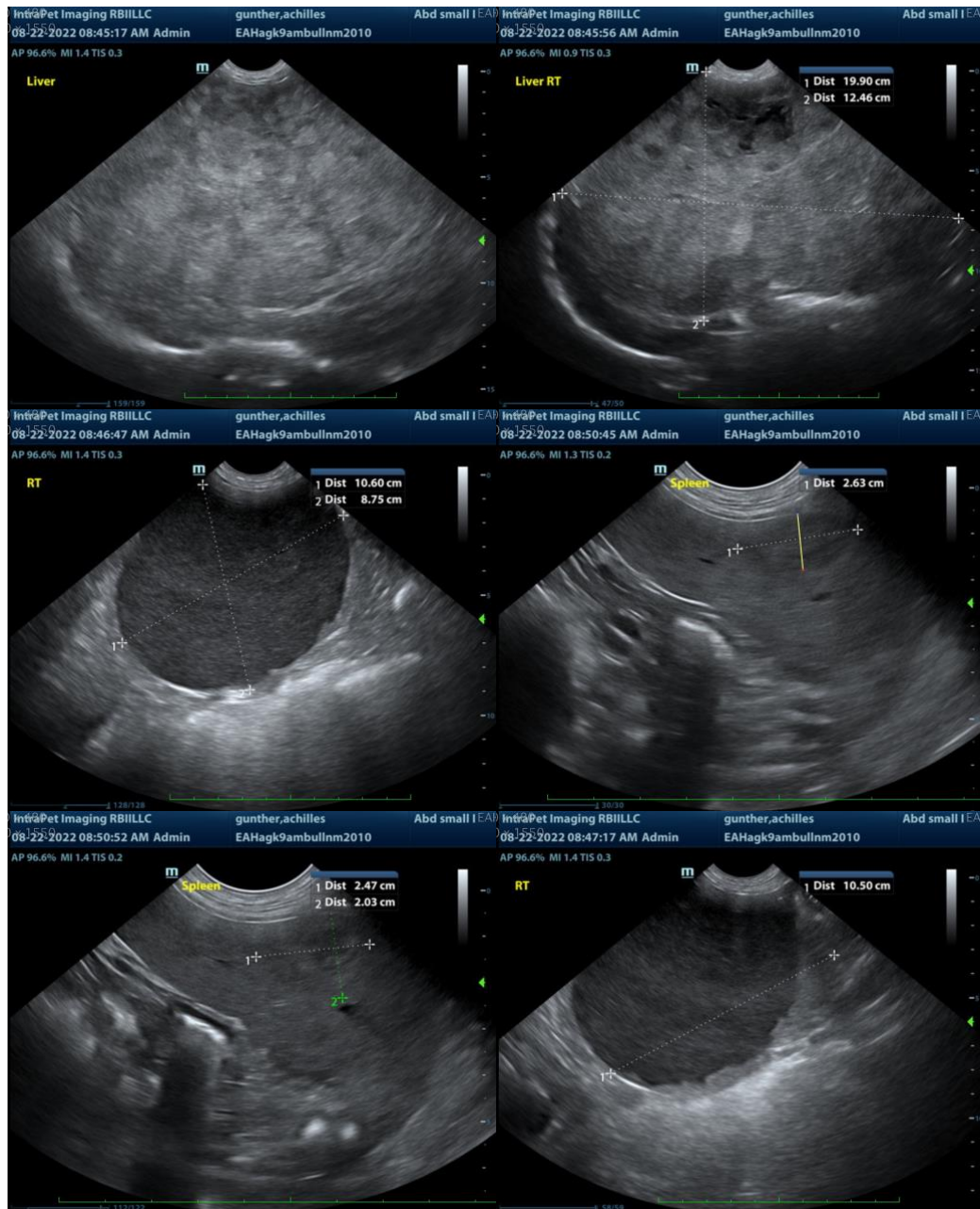
- A large heterogeneous liver mass, most concerning for infiltrative neoplasia, such as primary hepatic neoplasia like a hepatocellular carcinoma versus sarcoma versus infiltrative round cell neoplasia. Benign disease is possible but considered much less likely.
- Coarse splenomegaly – can be associated with congestion caused by sedation (if sedated) but can also be associated with diffuse infiltrative disease. Both benign conditions such as extramedullary hematopoiesis, lymphoid hyperplasia, as well as infiltrative neoplastic diseases such as round cell neoplasia should be considered. Given the discreet hypoechoic partially cavitated splenic nodule, metastatic disease has to be considered possible.
- The lesion associated with the right kidney is most consistent with a large renal cortical cyst, complicated in appearance given the echogenic nature of the fluid. An abscess is also possible. A tumor or metastatic lesion cannot be definitively ruled out but are considered much less likely.

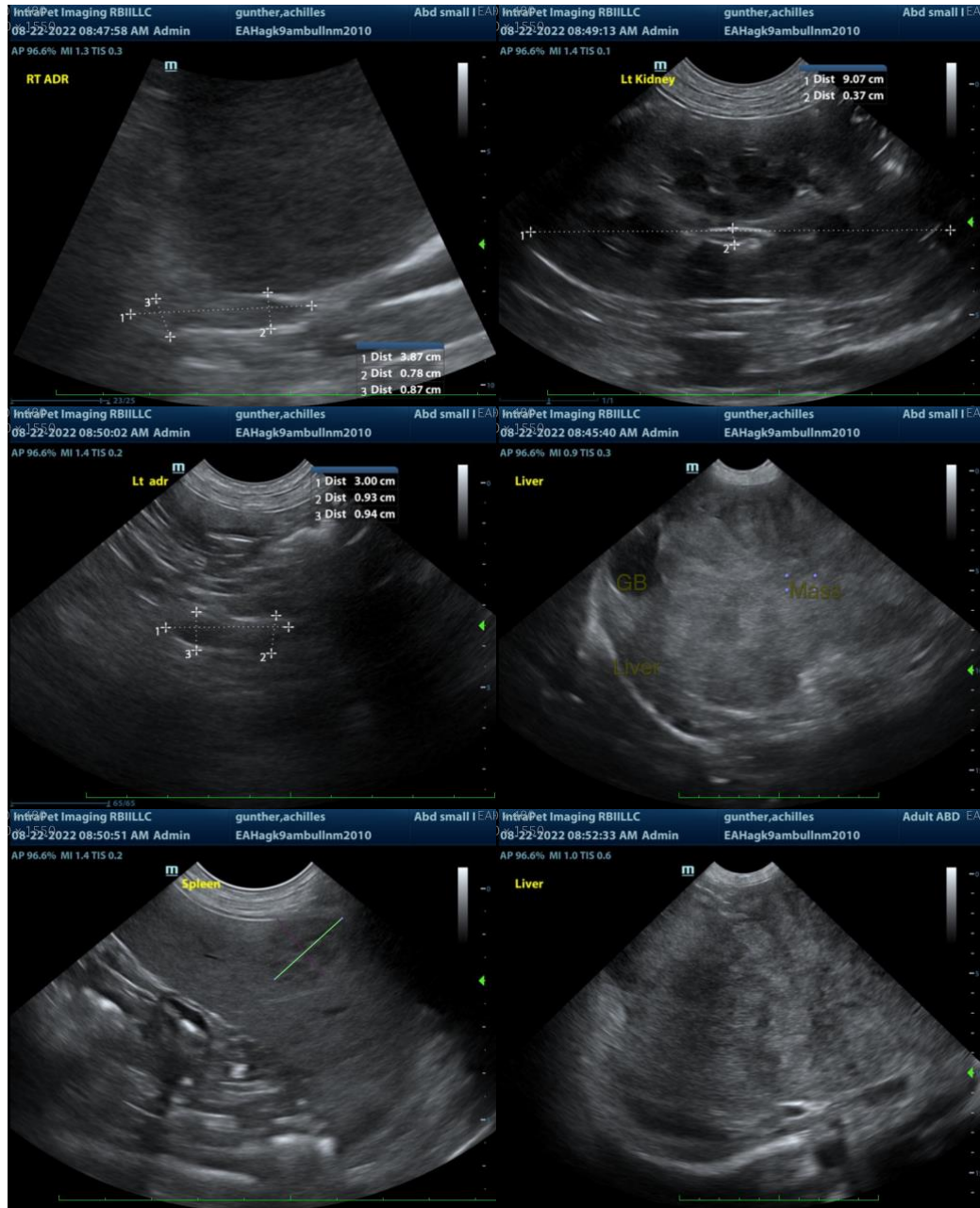
## **INTERPRETATION OF THE FINDINGS & FURTHER RECOMMENDATIONS**

Three view thoracic radiographs are recommended for further assessment of cardio-pulmonary status as well as to further evaluate for any evidence of metastatic disease, if not recently evaluated.

A fine needle aspirate of the liver mass +/- the splenic nodule is recommended, if patient coagulation status is appropriate. The suspected renal cyst could also be drained with submission of the fluid for cytology and culture, if indicated, based on cytology results. Alternatively, an exploratory laparotomy for planned liver

lobectomy/mass removal and splenic nodule biopsy, as well as further assessment of the suspected renal cortical cyst could be performed given the risk of future hemorrhage, necrosis, etc. of the liver mass, however, full resectability of the visual disease is questionable based on these images. A presurgical staging abdominal CT scan could be considered for more information regarding resectability.





The information and recommendations provided are based on the images presented by the referring veterinarian. No evaluation can be communicated regarding pathology that was not visible in the image/video clips provided.

Thank you for this referral. If the clinical or image interpretation does not parallel your findings or if I can be of any further assistance please contact me.

**Beth Johnson, DVM DACVIM**

Beth.Johnson@SonoPath.com