

**DATE PRESENTING CLINICAL SIGNS**

8/21/23

History: Chronic intermittent Hyporexia, lethargy, V+ hairballs (accompanies episodes of hyporexia and lethargy, resolves when they do). Hx of overgrooming, responds well to steroids and Atopica (not at the same time). PE unremarkable

PATIENT

Tony Rossi

SPECIES

Feline

Current Medications: Atopica 40mg q48h x 5 weeks.

Lab Results: CBC unremarkable, Chem: BUN 67, Glob 5.3, GGT 6 (<4), Amylase 1765, hyponatremia (144), hypokalemia (3.3) and hypochloremia (103) GI losses?

Date of Previous IntraPet Ultrasound: No previous.

BREED

DSH

Sedation: Not required to complete full diagnostic ultrasound.

Stat Report: Not requested.

Imaging Performed By: Stephanie Warga RDCS, RVT.

SEX

Neutered Male

ULTRASONOGRAPHIC EXAMINATION OF THE ABDOMEN**AGE**

2/26/21

Urinary System

Urinary bladder is adequately distended. It has a normal uniform wall thickness. Contents include primarily anechoic fluid with a moderate to large amount of echogenic non-shadowing debris, which could be partially consistent with incidental suspended lipid in a cat, likely combined with exfoliated cells, mucous and/or small blood clots. Both sterile inflammation as well as urinary tract infection can also present with echogenic debris. No masses or cystoliths are observed. The trigone and visible pelvic urethra are normal in thickness with a smooth mucosal surface.

WEIGHT

12.25 Pounds

Left kidney is normal in size (4.17 cm), shape and echogenicity. It has smooth peripheral margination. There is a normal 1:3 cortex to medulla ratio with appropriate corticomedullary distinction. There is no evidence of pyelectasia, mineral or infarcts observed.

INTERPRETED BYBeth Johnson, DVM
DACVIM

Right kidney is normal in size (4.03 cm), shape and echogenicity. It has smooth peripheral margination. There is a normal 1:3 cortex to medulla ratio with appropriate corticomedullary distinction. There is no evidence of pyelectasia, mineral or infarcts observed.

HOSPITAL NAME

Timonium AH

Adrenal Glands

Left adrenal gland is normal in size (0.31 cm), shape and overall architecture, echogenicity and echotexture. Visible surrounding vasculature appears normal.

REFERRING VET

Dr. Montessi

Right adrenal gland is normal in size (0.36 cm), shape and overall architecture, echogenicity and echotexture. Visible surrounding vasculature appears normal.

INVOICE

24023

Spleen

Spleen is subjectively normal in size with a normal smooth capsular contour. Parenchyma is appropriately finely textured and homogenous with normal echogenicity relative to surrounding tissue (hyperechoic to liver). No focal nodules or masses are observed. Splenic vasculature appears normal.

Liver

Liver is subjectively normal in size with normal smooth curvilinear peripheral contour. Parenchyma is appropriately hypoechoic to the spleen in echogenicity and appropriately mildly coarse and homogenous in echotexture. No focal lesions are observed. Visible vasculature and biliary tree appear normal without distension or congestion.

Gallbladder is non-distended in size. The wall is smooth without visible thickening. Luminal contents are primarily anechoic. There is no evidence of cystic or common bile duct dilation.

Gastrointestinal

The visible stomach wall is normal in thickness and layering. The lumen of the stomach is empty, except for in the pylorus, where there is an echogenic interface with distal progressively shadowing material consistent with possible nonobstructive hairball.

The visible small intestines are normal in wall thickness and layering. Small intestinal motility appears adequate (1-3 contractions per min). The lumen of the small intestine is empty, except for in the mid jejunum, where there is similar appearing echogenic material with distal progressively shadowing consistent with hairball. There is no evidence of distention, plication or an obstructive pattern in these images at this time.

The visible colon is normal in wall thickness and layering. Contents are consistent with normal formed feces and gas.

Pancreas

The pancreas is well observed/prominent in appearance and mildly hypoechoic to surrounding omental fat. The visible capsule is smooth and normal in contour and the visible parenchyma is homogenous and unremarkable. There is no evidence of pancreatic duct dilation. The peripancreatic area is subtly enhanced/hyperechoic.

Free Abdomen

There is no evidence of peritoneal effusion. There is no apparent lymphadenopathy.

ULTRASONOGRAPHIC FINDINGS

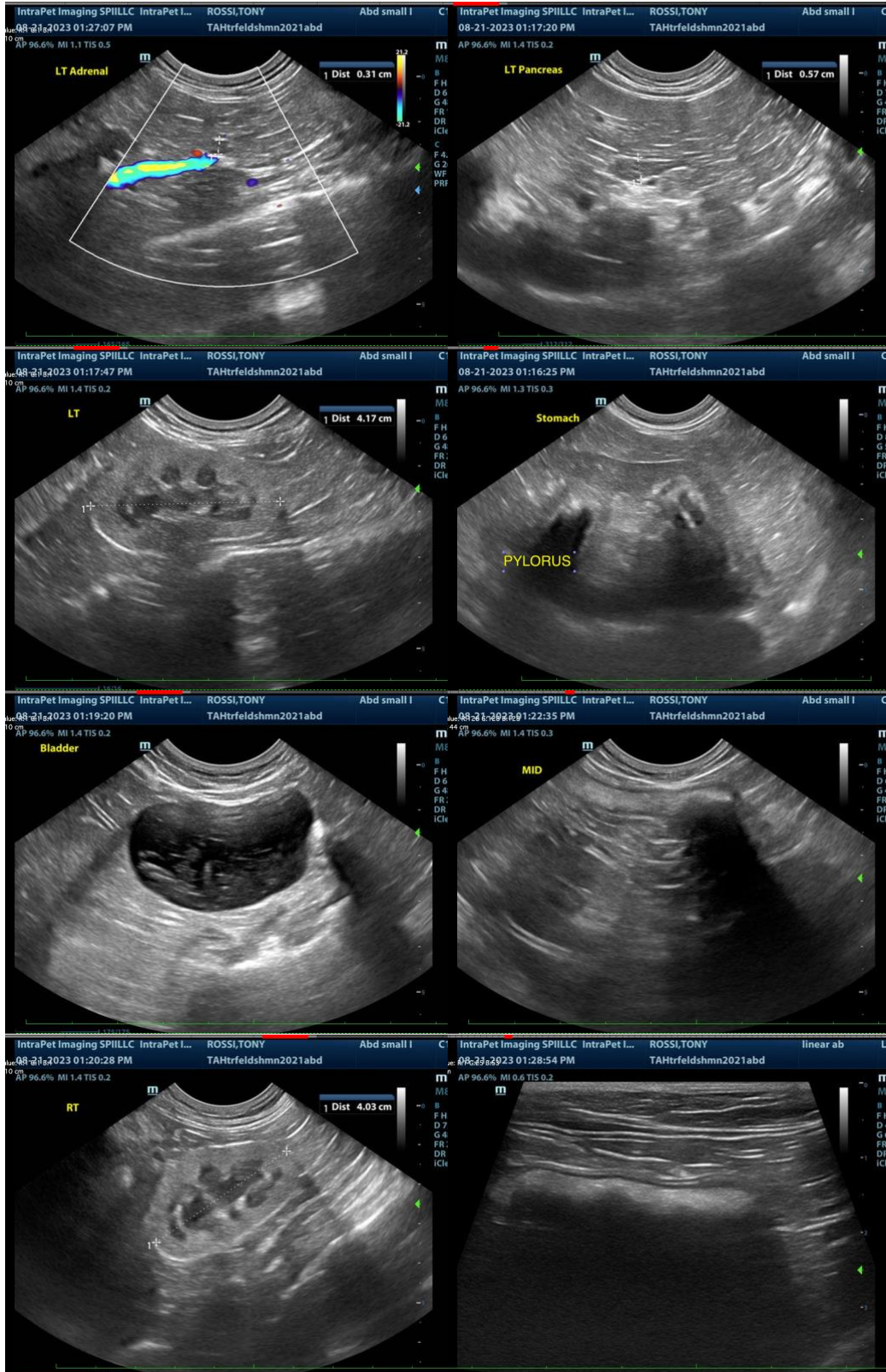
- There are pyloric and mid jejunal contents consistent with this patient's history of hairballs, however, there is no evidence of an obstructive pattern in these images at this time.
- Mild or potentially emerging vs resolving pancreatitis could be contributing to patient's gastrointestinal signs.
- Urinary bladder debris

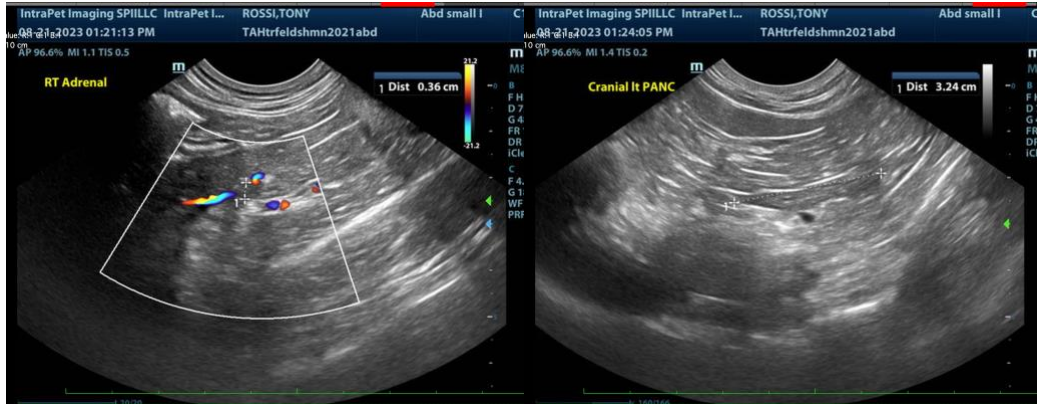INTERPRETATION OF THE FINDINGS & FURTHER RECOMMENDATIONS

There is no definitive ultrasonographic evidence of infiltrative bowel disease contributing to the overgrooming and hairballs, however, infiltrative bowel disease cannot be ruled out based on ultrasound alone. Therefore, especially given the concurrent pancreatic changes, a gastrointestinal malabsorption panel (including cobalamin, folate, TLI and PLI) to Texas A&M GI Laboratory is recommended for further evaluation of GI and pancreatic function.

In the meantime, empirical deworming with a 5-day course of Panacur is recommended, and if tolerated, a transition in diet could be considered beginning with a hydrolyzed protein diet, which could potentially address possible dietary related gastrointestinal disease, as well as potentially atopy contributing to overgrooming.

Pending results, consultation with a veterinary dermatologist could be considered.





The information and recommendations provided are based on the images presented by the referring veterinarian. No evaluation can be communicated regarding pathology that was not visible in the image/video clips provided.

Thank you for this referral. If the clinical or image interpretation does not parallel your findings or if I can be of any further assistance please contact me.

Beth Johnson, DVM DACVIM
info@SonoPath.com