



PATIENT

Snoopy Stanlick

SPECIES

Feline

BREED

DSH

SEX

Neutered Male

AGE

17

WEIGHT

4.7

INTERPRETED BY

Beth Johnson, DVM
DACVIM

IMAGING PERFORMED BY

Michelle Roche

HOSPITAL NAME

Fredon AH

REFERRING VET

Linda Grau

INVOICE

24026

DATE

8/21/23

PRESENTING CLINICAL SIGNS

History: loose stool, no response to empirical pred/B12.

Abnormal PE/Chem/CBC/UA Results: wasted on exam, bw last nov wnl.

ULTRASONOGRAPHIC EXAMINATION OF THE ABDOMEN

Urinary System

Urinary bladder is adequately distended with anechoic contents. No masses, inflammatory changes, echogenic sediment or cystoliths are observed. The urinary bladder, trigone and visible pelvic urethra are normal in thickness with a smooth mucosal surface.

Kidneys are overall normal in size and shape with smooth peripheral margination. A normal 1:3 cortex to medulla ratio is maintained. The medulla and cortices are uniform in texture with some mild increased cortical echogenicity and mild loss of corticomedullary distinction, expected in this age patient. There is no evidence of pyelectasia or infarcts observed. Small cortical cysts are noted bilaterally. Nonobstructive nephroliths are noted bilaterally. Left kidney measures 3.11 cm. Right kidney measures 3.33 cm.

Adrenal Glands

Left adrenal gland is unable to be well visualized in these images.

Right adrenal gland is normal in size (0.47 cm), shape and overall architecture, echogenicity and echotexture. Visible surrounding vasculature appears normal.

Spleen

Spleen is subjectively normal in size with a normal smooth capsular contour. Parenchyma is appropriately finely textured and homogenous with normal echogenicity relative to surrounding tissue (hyperechoic to liver). No focal nodules or masses are observed. Splenic vasculature appears normal.

Liver

Liver is subjectively normal in size with normal smooth curvilinear peripheral contour. Parenchyma is appropriately hypoechoic to the spleen in echogenicity and appropriately mildly coarse and homogenous in echotexture. No focal lesions are observed. Visible vasculature and biliary tree appear normal without distension or congestion.

Gallbladder is moderately distended with anechoic bile as well as suspended and gravity dependent echogenic debris. The wall is smooth without visible thickening. There is no evidence of cystic or CBD dilation. There is no evidence of effusion or inflammation.

Gastrointestinal

The visible stomach wall is normal in thickness and layering. The lumen of the stomach is empty with no evidence of obstruction, foreign material or infiltrative disease. Pyloric outflow tract appears patent.

The visible small intestines are normal in wall thickness and layering. Small intestinal motility appears adequate (1-3 contractions per min). The lumen of the small intestine is empty with no evidence of obstruction, foreign material or infiltrative disease.

The visible colon is normal in wall thickness and layering. Contents are consistent with normal formed feces and gas.



PATIENT

Pancreas

Snoopy Stanlick

The observed pancreas appears appropriately isoechoic to surrounding omental fat. Visible capsule is smooth and normal in contour. Visible pancreatic parenchyma is homogenous and unremarkable. There is no visible pancreatic duct dilation. There is no evidence of active peripancreatic inflammation.

SPECIES

Feline

Free Abdomen

There is no evidence of peritoneal effusion. There is no apparent lymphadenopathy.

BREED

DSH

SEX

Neutered Male

AGE

17

WEIGHT

4.7

INTERPRETED BY

Beth Johnson, DVM
DACVIM

IMAGING PERFORMED BY

Michelle Roche

HOSPITAL NAME

Fredon AH

REFERRING VET

Linda Grau

INVOICE

24026

DATE

8/21/23

ULTRASONOGRAPHIC FINDINGS

- Mild gallbladder debris – Cholecystic debris is of unknown clinical significance. It can be seen with biliary stasis from fasting or illness, however, it can also be associated with hepatobiliary disease in cats and should be interpreted in combination with clinical signs such as nausea, inappetence, cranial abdominal discomfort and/or laboratory changes such as increased ALP and/or increased Tbili.
- Age-related kidney changes with nonobstructive small nephroliths and cortical cysts noted bilaterally.

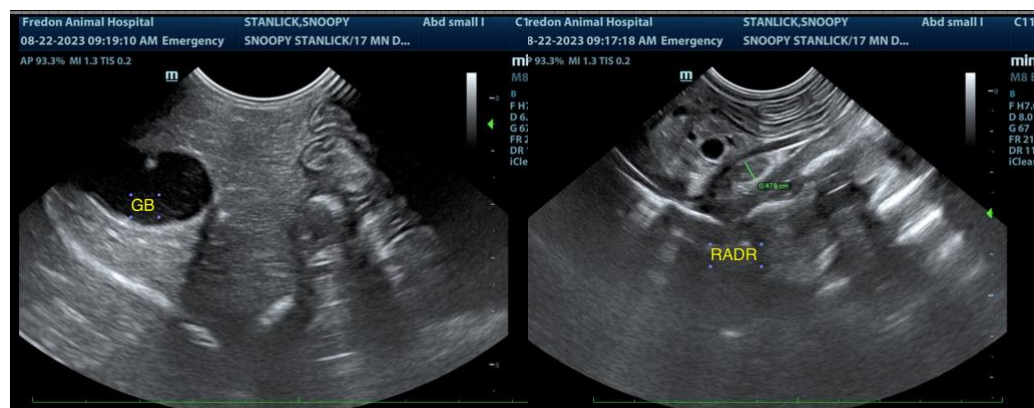
INTERPRETATION OF THE FINDINGS & FURTHER RECOMMENDATIONS

There is no definitive ultrasonographically visible evidence of infiltrative gastrointestinal disease present in these images at this time. However, changes could be masked by the current therapy.

Given the lack of improvement on empirical medication, further evaluation, if not already evaluated, of possible exocrine pancreatic insufficiency via evaluation of TLI is recommended.

Additionally, a fecal enteropathogen PCR panel to Texas A&M GI Laboratory could be considered for further evaluation of possible infectious disease.

Pending results, ultimately, biopsies of the gastrointestinal tract may be necessary for a definitive diagnosis, and therefore, to guide more aggressive medical management. If biopsies are not possible, other empirical therapeutic considerations could include empirical deworming with a 5-day course of Panacur, a probiotic such as Visbiome or Provable, potentially a transition in diet, beginning with a hydrolyzed protein diet if tolerated, and ultimately, while the empirical use should be pursued cautiously, additional immunosuppressants, such as chlorambucil could be considered, if there are no patient contraindications/comorbidities that would prevent its safe use.





PATIENT

Snoopy Stanlick

SPECIES

Feline

BREED

DSH

SEX

Neutered Male

AGE

17

WEIGHT

4.7

INTERPRETED BY

Beth Johnson, DVM
DACVIM

IMAGING PERFORMED BY

Michelle Roche

HOSPITAL NAME

Fredon AH

REFERRING VET

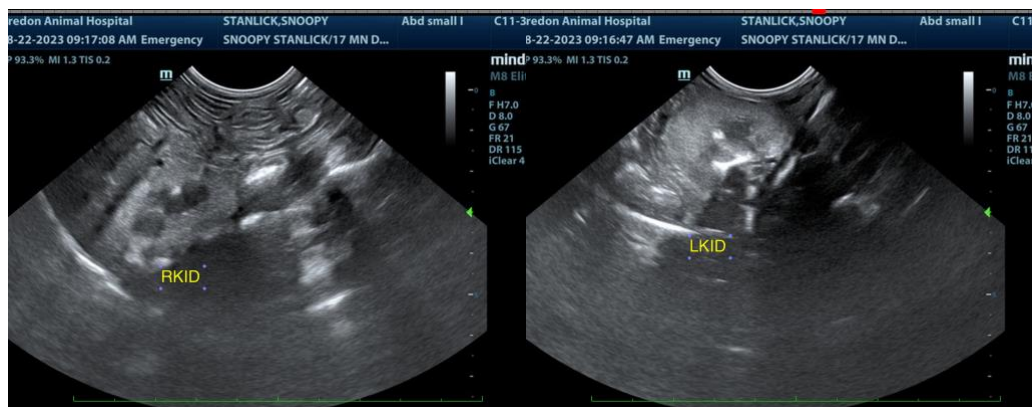
Linda Grau

INVOICE

24026

DATE

8/21/23



The information and recommendations provided are based on the images presented by the referring veterinarian. No evaluation can be communicated regarding pathology that was not visible in the image/video clips provided.

Thank you for this referral. If the clinical or image interpretation does not parallel your findings or if I can be of any further assistance please contact me.

Beth Johnson, DVM DACVIM

info@sonopath.com