



PATIENT

Jia Troupe

SPECIES

Canine

BREED

Sheltie

SEX

Spayed Female

AGE

13 Years

WEIGHT

21 Pounds

INTERPRETED BY

Beth Johnson, DVM
DACVIM

IMAGING PERFORMED BY

Danielle Lanz

HOSPITAL NAME

New Holland VH

REFERRING VET

Danielle Lanz

INVOICE

24025

DATE

8/21/23

PRESENTING CLINICAL SIGNS

Persistent elevated liver enzymes. HX of IBD and hypothyroidism. Currently controlled on hydrolyzed protein and levothyroxine. No concerns at home - eating, drinking, energy level is normal. Unable to take denamarin and ursodiol due to IBD flare ups.

Abnormal PE/Chem/CBC/UA Results: ALT 124 ALP 192 Cholesterol 644

ULTRASONOGRAPHIC EXAMINATION OF THE ABDOMEN

Urinary System

Urinary bladder is adequately distended with anechoic contents. No masses, inflammatory changes, echogenic sediment or cystoliths are observed. The urinary bladder, trigone and visible pelvic urethra are normal in thickness with a smooth mucosal surface.

Left kidney is normal in size (4.3 cm), shape and echogenicity. It has smooth peripheral margination. There is a normal 1:3 cortex to medulla ratio with appropriate corticomedullary distinction. There is no evidence of pyelectasia, mineral or infarcts observed.

Right kidney is normal in size (4.41 cm), shape and echogenicity. It has smooth peripheral margination. There is a normal 1:3 cortex to medulla ratio with appropriate corticomedullary distinction. There is no evidence of pyelectasia, mineral or infarcts observed.

Adrenal Glands

The areas of both adrenal glands are examined without evident adrenal gland pathology.

Spleen

Spleen is subjectively normal in size with a normal smooth capsular contour. Parenchyma is appropriately finely textured and homogenous with normal echogenicity relative to surrounding tissue (hyperechoic to liver). Multifocal well-demarcated hyperechoic homogenous nodules are noted. Splenic vasculature appears normal.

Liver

Liver is subjectively normal in size with normal smooth curvilinear peripheral contour. Parenchyma is appropriately hypoechoic to the spleen in echogenicity and appropriately mildly coarse and homogenous in echotexture. No focal lesions are observed. Visible vasculature and biliary tree appear normal without distension or congestion.

Gallbladder is moderately distended with anechoic bile as well as suspended and gravity dependent echogenic debris. The wall is smooth without visible thickening. There is no evidence of cystic or CBD dilation. There is no evidence of effusion or inflammation.

Gastrointestinal

The visible stomach wall is normal in thickness and layering. The lumen of the stomach is mildly distended with very echogenic reverberation artifact from intraluminal gas. There is no evidence of obstruction, foreign material or infiltrative disease; however, complete visualization of far wall is partially inhibited by gas. Pyloric outflow tract appears patent.

The visible small intestines are normal in wall thickness and layering. Small intestinal motility appears adequate (1-3 contractions per min). The lumen of the small intestine is empty with no evidence of obstruction, foreign material or infiltrative disease.



PATIENT

The visible colon is normal in wall thickness and layering. Contents are consistent with normal formed feces and gas.

Jia Troupe

Pancreas

SPECIES

The observed pancreas appears appropriately isoechoic to surrounding omental fat. Visible capsule is smooth and normal in contour. Visible pancreatic parenchyma is homogenous and unremarkable. There is no visible pancreatic duct dilation. There is no evidence of active peripancreatic inflammation.

Canine

BREED

Free Abdomen

There is no evidence of peritoneal effusion. There is no apparent lymphadenopathy.

Sheltie

ULTRASONOGRAPHIC FINDINGS

SEX

- Moderate gallbladder debris - Cholecystic debris is of unknown clinical significance. It can be seen with biliary stasis from fasting or illness. Cholecystic debris is not necessarily related to hepatobiliary disease. Echogenic bile is most commonly an incidental finding in dogs and should be interpreted in combination with clinical signs such as nausea, inappetence, cranial abdominal discomfort and/or laboratory changes such as increased ALP and/or increased Tbili.

Spayed Female

AGE

13 Years

WEIGHT

21 Pounds

- Hyperechoic splenic nodules - most consistent with benign myelolipomas. Other differentials such as fibrosis or calcification caused by old hematomas or infarcts, chronic inflammation, granulomatous disease or metastatic disease cannot be ruled out, but are considered less likely.

INTERPRETED BY

INTERPRETATION OF THE FINDINGS & FURTHER RECOMMENDATIONS

Beth Johnson, DVM
DACVIM

Given this patients breed and the appearance of the gallbladder, ideally, ursodiol therapy would be implemented, however, given this patients reported inability to tolerate ursodiol, close monitoring of liver enzymes, clinical signs, ultrasound changes, etc., is recommended with ultimately, potentially, a cholecystectomy being the only option if clinical signs develop and then persist/progress. At this time, however, in an asymptomatic patient with relatively mild liver enzyme increases, surgery is not necessary.

IMAGING PERFORMED BY

Danielle Lanz

HOSPITAL NAME

New Holland VH

REFERRING VET

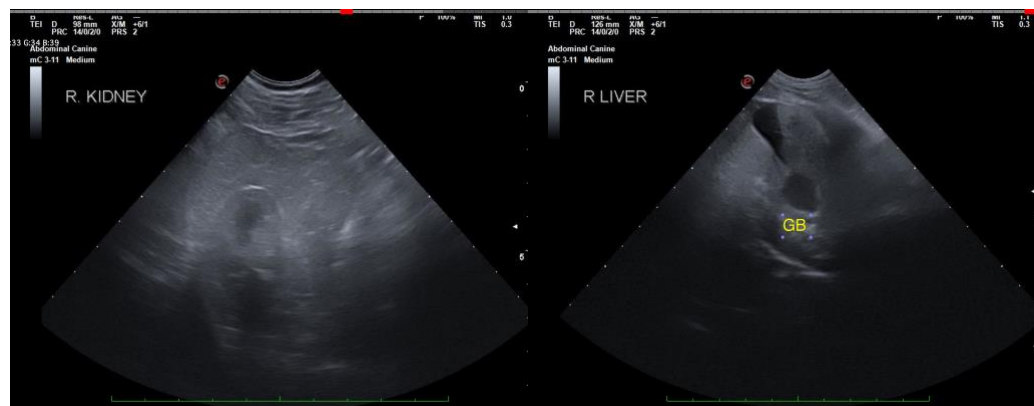
Danielle Lanz

INVOICE

24025

DATE

8/21/23





PATIENT

Jia Troupe

SPECIES

Canine

BREED

Sheltie

SEX

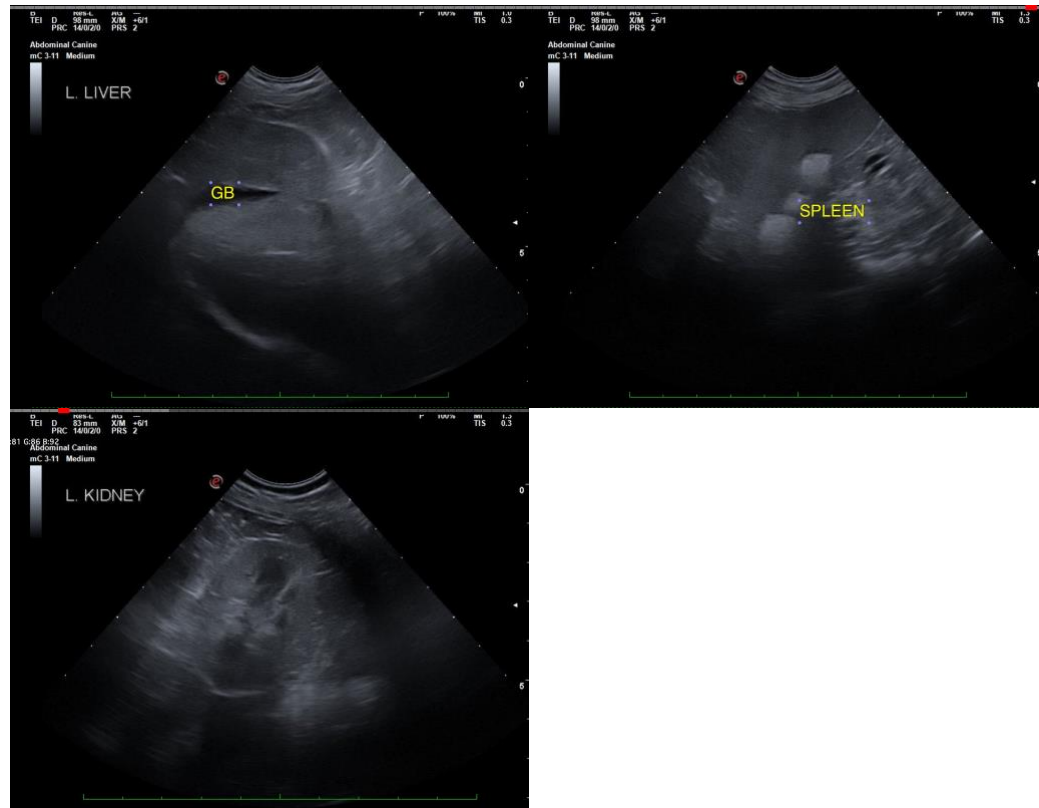
Spayed Female

AGE

13 Years

WEIGHT

21 Pounds



INTERPRETED BY

Beth Johnson, DVM
DACVIM

IMAGING PERFORMED BY

Danielle Lanz

HOSPITAL NAME

New Holland VH

REFERRING VET

Danielle Lanz

INVOICE

24025

DATE

8/21/23

The information and recommendations provided are based on the images presented by the referring veterinarian. No evaluation can be communicated regarding pathology that was not visible in the image/video clips provided.

Thank you for this referral. If the clinical or image interpretation does not parallel your findings or if I can be of any further assistance please contact me.

Beth Johnson, DVM DACVIM

info@sonopath.com