

**DATE PRESENTING CLINICAL SIGNS**

8/21/23 History: High assessment on NuQ cancer screening.

**PATIENT**

Bumble Funk

Current Medications: Gabapentin 25mg BID PRN, Trazodone 50mg ¼-1/2 PRN for fireworks.

Radiographs: See attached.

Date of Previous IntraPet Ultrasound: No previous.

Sedation: Not required to complete full diagnostic ultrasound.

**SPECIES**

Canine

Stat Report: Not requested.

Imaging Performed By: Stephanie Warag RDCS, RVT.

**BREED**

Maltese Mix

**ULTRASONOGRAPHIC EXAMINATION OF THE ABDOMEN****SEX**

Neutered Male

**Urinary System**

Urinary bladder is adequately distended with anechoic contents. No masses, inflammatory changes, echogenic sediment or cystoliths are observed. The urinary bladder, trigone and visible pelvic urethra are normal in thickness with a smooth mucosal surface.

Prostate (neutered) is normal in size, echotexture and echogenicity for a neutered male.

**AGE**

10/29/13

Left kidney is normal in size (3.74 cm), shape and echogenicity. It has smooth peripheral margination. There is a normal 1:3 cortex to medulla ratio with appropriate corticomedullary distinction. There is no evidence of pyelectasia, mineral or infarcts observed.

**WEIGHT**

12.6 Pounds

Right kidney is normal in size (3.29 cm), shape and echogenicity. It has smooth peripheral margination. There is a normal 1:3 cortex to medulla ratio with appropriate corticomedullary distinction. There is no evidence of pyelectasia, mineral or infarcts observed.

**INTERPRETED BY**Beth Johnson, DVM  
DACVIM**Adrenal Glands**

Left adrenal gland is normal in size (0.54 cm at cranial pole and 0.47 cm at caudal pole), shape and overall architecture, echogenicity and echotexture. Visible surrounding vasculature appears normal.

Right adrenal gland is normal in size (0.36 cm at cranial pole and 0.42 cm at caudal pole), shape and overall architecture, echogenicity and echotexture. Visible surrounding vasculature appears normal.

**HOSPITAL NAME**AMC of Dulaney  
Valley**Spleen**

Spleen is subjectively normal in size with a normal smooth capsular contour. Parenchyma is appropriately finely textured and homogenous with normal echogenicity relative to surrounding tissue (hyperechoic to liver). No focal nodules or masses are observed. Splenic vasculature appears normal.

**REFERRING VET**

Dr. Chrest

**Liver**

Liver is subjectively normal in size with normal smooth curvilinear peripheral contour. Parenchyma is appropriately hypoechoic to the spleen in echogenicity and appropriately mildly coarse and homogenous in echotexture. No focal lesions are observed. Visible vasculature and biliary tree appear normal without distension or congestion.

**INVOICE**

24020

Gallbladder is non-distended in size. The wall is smooth without visible thickening. Luminal contents are primarily anechoic. There is no evidence of cystic or common bile duct dilation.

**Gastrointestinal**

The visible stomach wall is normal in thickness and layering. The lumen of the stomach is empty with no evidence of obstruction, foreign material or infiltrative disease. Pyloric outflow tract appears patent. The visible small intestines are normal in wall thickness and layering. Hyperechoic mucosal fogging or speckling is noted. Small intestinal motility appears adequate (1-3 contractions per min). The lumen of the small intestine is empty with no evidence of obstruction or foreign material.

The visible colon is normal in wall thickness and layering. Contents are consistent with normal formed feces and gas.

### ***Pancreas***

The observed pancreas appears appropriately isoechoic to surrounding omental fat. Visible capsule is smooth and normal in contour. Visible pancreatic parenchyma is homogenous and unremarkable. There is no visible pancreatic duct dilation. There is no evidence of active peripancreatic inflammation. \*See Free Abdomen section.

### ***Free Abdomen***

A scant/trace amount of anechoic free fluid is noted in the mid abdomen, as well as subjectively subtly diffusely enhanced/hyperechoic mesenteric fat. Additionally, in the left cranial abdomen, there is a 1.0 cm x 1.3 cm hypo- to anechoic appearing structure, that appears to be associated with the pancreas, such as a cyst, however, an enlarged lymph node cannot be definitively ruled out. There is no apparent lymphadenopathy.

### ***Other***

Subtle ringdowns are noted at the level of the diaphragm.

## **ULTRASONOGRAPHIC FINDINGS**

- Mucosal speckling – Mucosal speckling is often present with inflammatory bowel disease (IBD). It is not specific for type or severity of disease. Mild speckling change can occur as a normal patient variant in the post-prandial state.
- Subtle ringdowns at the level of the diaphragm could suggest concurrent pulmonary pathology.
- The hypo- to anechoic structure within the cranial abdomen appears to be associated with the pancreas and is consistent with a pancreatic cyst, and trends in appearance toward benign. Having said that, while considered less likely, an enlarged lymph node, infiltrative neoplasia, etc., can't be definitively ruled out.
- The subtly diffusely enhanced mesenteric fat and scant amount of free fluid could be secondary to diffuse gastroenteritis/bowel disease vs mild or emerging pancreatitis vs other. A paraneoplastic effusion is possible, however, there are no definitive characteristics of malignancy in this study to make cancer more probable than other more likely benign differentials.

## **INTERPRETATION OF THE FINDINGS & FURTHER RECOMMENDATIONS**

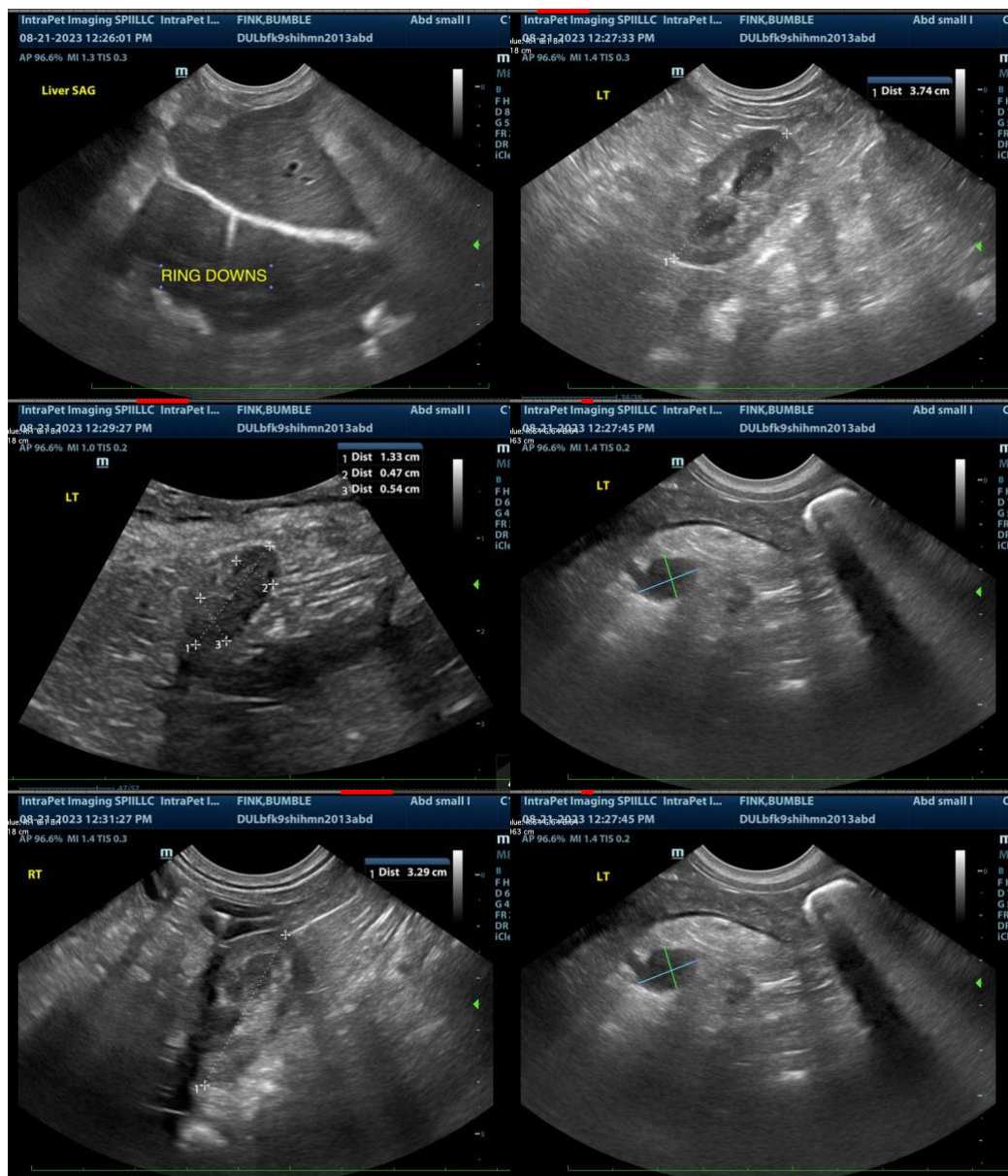
If not recently evaluated, three view thoracic radiographs are recommended for further assessment of cardio-pulmonary status as well as to further evaluate for any evidence of metastatic disease, if not recently evaluated.

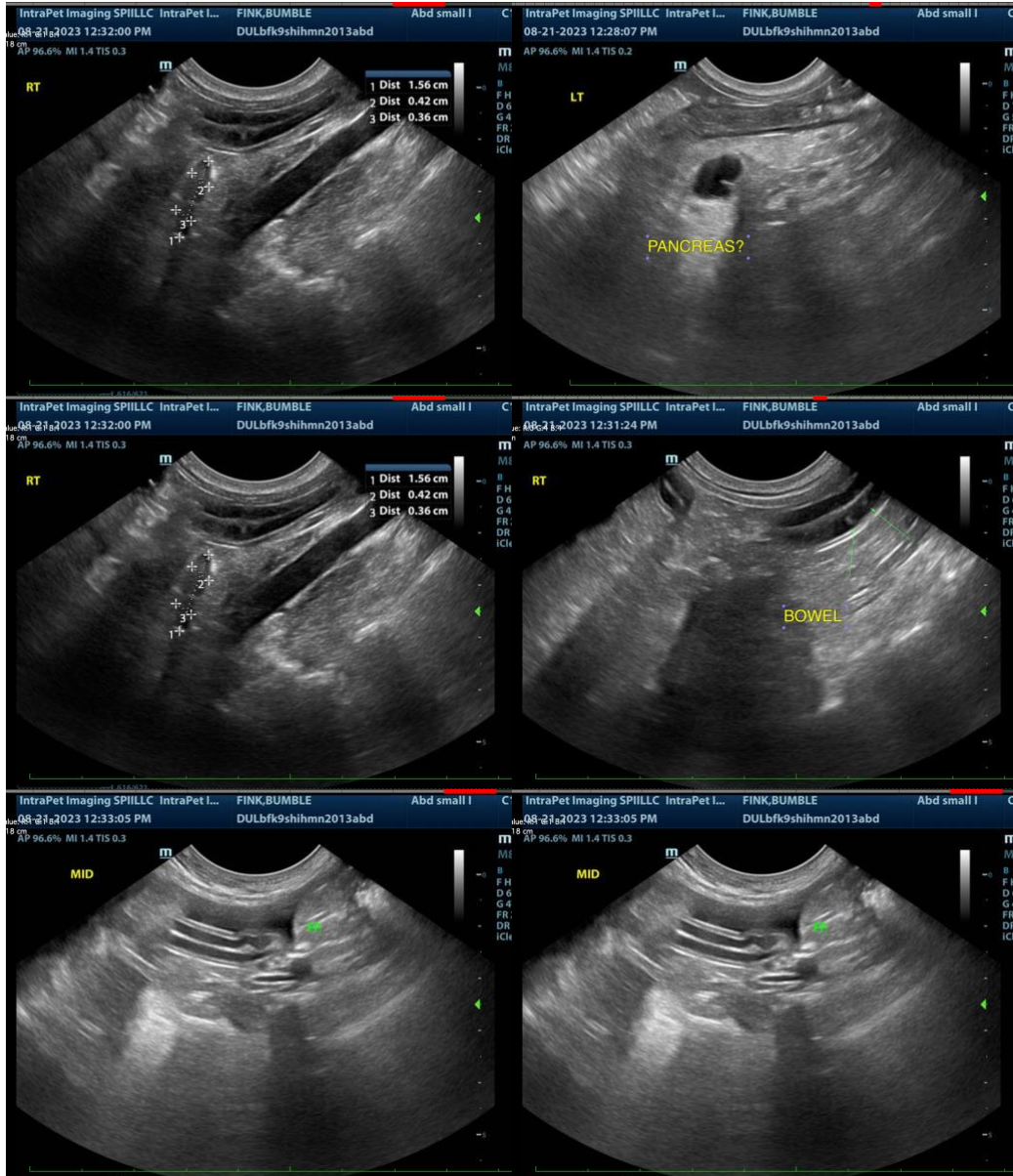
Given this patient's mucosal speckling and reported hypoalbuminemia, further evaluation of digestion and absorption is recommended, beginning with a gastrointestinal malabsorption panel (including cobalamin,

folate, TLI and PLI) to Texas A&M GI Laboratory is recommended for further evaluation of GI and pancreatic function.

A baseline cortisol is recommended. If baseline cortisol is less than 2, a full ACTH stimulation test is recommended to rule out hypoadrenocorticism.

Pending results of above, a fine needle aspirate of the cranial abdominal structure could be considered if patients coagulation status is appropriate or alternatively, monitoring for progression ultrasonographically could be considered as a less invasive approach. Ultimately, recommendations for this patient are partially dependent on clinical signs, etc.





The information and recommendations provided are based on the images presented by the referring veterinarian. No evaluation can be communicated regarding pathology that was not visible in the image/video clips provided.

Thank you for this referral. If the clinical or image interpretation does not parallel your findings or if I can be of any further assistance please contact me.

**Beth Johnson, DVM DACVIM**  
info@SonoPath.com