

**DATE PRESENTING CLINICAL SIGNS**

8/2/23 Decreased appetite for 2-3 weeks, rapid weight loss/muscle mass loss, abdominal effusion, panhypoproteinemia.

PATIENT

Gus Mitchell Current Medications: GS injections once daily.
Lab Results: Alb 1.6, Glob 2.3, tCa 7.7.

Date of Previous IntraPet Ultrasound: No previous.

Sedation: Not required to complete full diagnostic ultrasound.

SPECIES

Stat Report: Not requested.

Feline

Imaging Performed By:

BREED

Maine Coon

ULTRASONOGRAPHIC EXAMINATION OF THE ABDOMEN**Urinary System**

The urinary bladder is moderately distended with anechoic contents. No masses, inflammatory changes, echogenic sediment or cystoliths are observed. The urinary bladder, trigone and visible pelvic urethra are normal in thickness with a smooth mucosal surface.

SEX

Neutered Male

The right kidney is normal in size (4.68 cm), shape and echogenicity. It has smooth peripheral margination. There is a normal 1:3 cortex to medulla ratio with appropriate corticomedullary distinction. There is no evidence of pyelectasia, mineral or infarcts observed.

AGE

9/15/14

The left kidney is normal in size (4.46 cm), shape and echogenicity. It has smooth peripheral margination. There is a normal 1:3 cortex to medulla ratio with appropriate corticomedullary distinction. There is no evidence of pyelectasia, mineral or infarcts observed.

WEIGHT

7.93 Pounds

INTERPRETED BY

Beth Johnson, DVM
DACVIM

Adrenal Glands

The adrenal glands are difficult to fully visualize in these images.

Spleen

The spleen is subjectively normal in size with a normal smooth capsular contour. Parenchyma is appropriately finely textured and homogenous with normal echogenicity relative to surrounding tissue (hyperechoic to liver). No focal nodules or masses are observed. Splenic vasculature appears normal.

HOSPITAL NAME

Nexus Vet Specialists

Liver

The liver is subjectively normal in size with normal smooth curvilinear peripheral contour. Parenchyma is appropriately hypoechoic to the spleen in echogenicity and appropriately mildly coarse and homogenous in echotexture. No focal lesions are observed. Visible vasculature and biliary tree appear normal without distension or congestion.

REFERRING VET

Dr. Steele

INVOICE

44580

The gallbladder is non-distended in size. The wall is smooth without visible thickening. Luminal contents are primarily anechoic. There is no evidence of cystic or common bile duct dilation.

Gastrointestinal

The stomach wall is normal in thickness (canine < 0.5 cm and feline < 0.4 cm) and layering. The lumen of the stomach is empty with no evidence of obstruction, foreign material or infiltrative disease. Pyloric outflow tract appears patent.

The visible small intestines are normal in wall thickness and layering (canine duodenum < 0.5 cm and feline duodenum < 0.4 cm; other < 0.3 cm). Small intestinal motility appears adequate (1-3 contractions per min).

The lumen of the small intestine is empty with no evidence of obstruction, foreign material or infiltrative disease.

The visible colon is normal in wall thickness (< 0.2 cm) and layering. Contents are consistent with normal formed feces and gas.

Pancreas

The pancreatic parenchyma is appropriately isoechoic to surrounding tissue. Visible capsule is smooth and normal in contour. There is no visible pancreatic duct dilation. There is no evidence of active peripancreatic inflammation.

Free Abdomen

There is no apparent lymphadenopathy noted in these images.

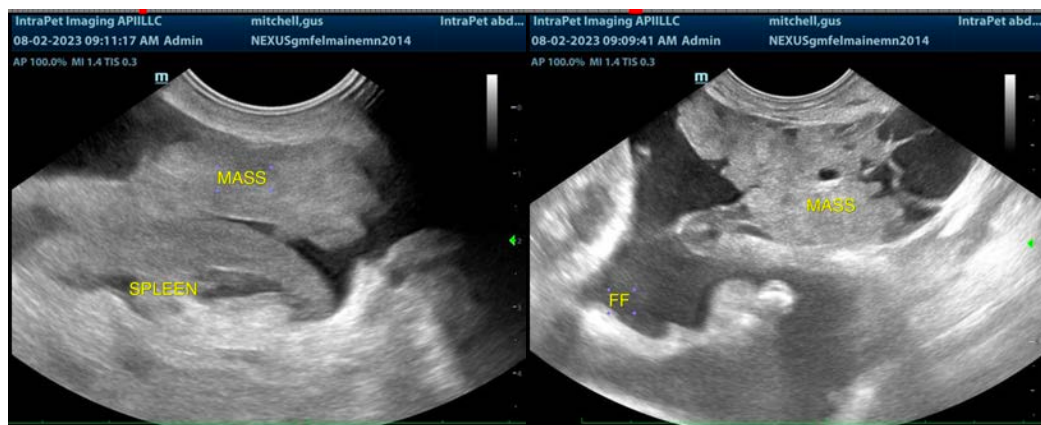
There is a large amount of very echogenic appearing free fluid throughout the abdomen as well as through suspected bowel wall erosion and herniation of the nodules/masses that diffusely encompass the omentum/mesentery. Multifocal heterogeneous, primarily hyperechoic body wall nodules/masses are also appreciated.

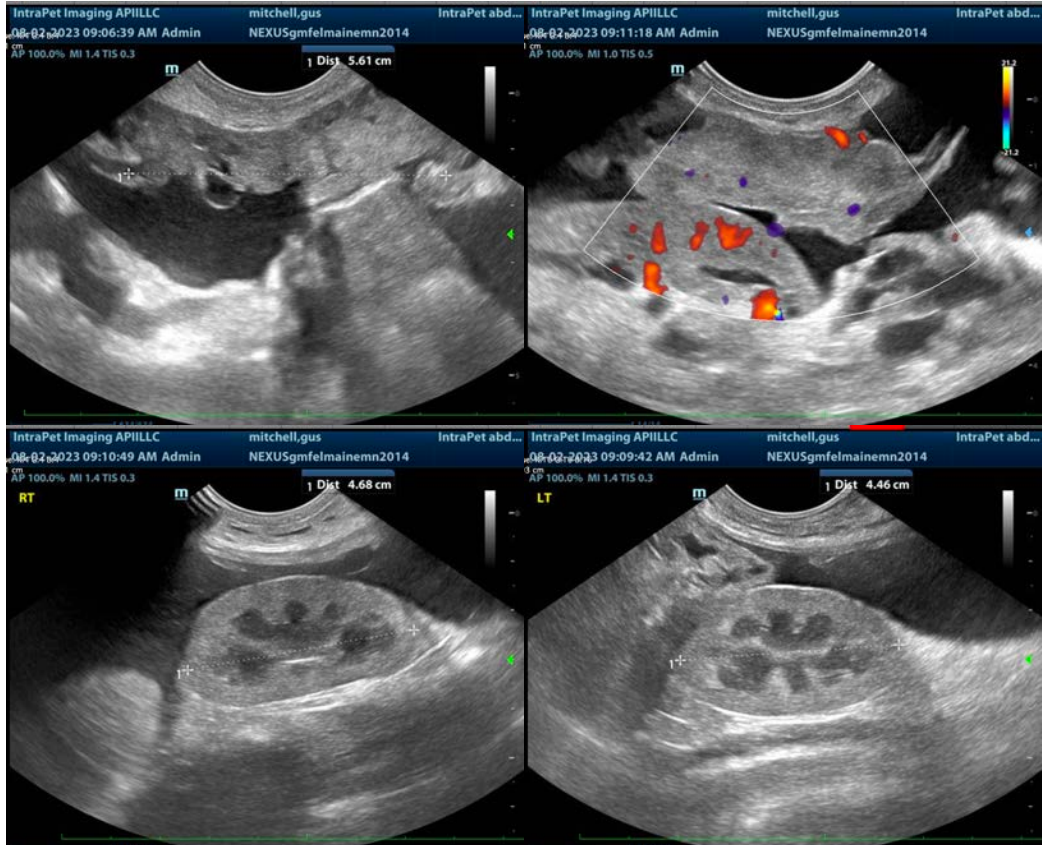
ULTRASONOGRAPHIC FINDINGS

- Diffusely nodular omentum/mesentery and a nodular body wall with disruption of the integrity of the body wall, and herniation of abdominal fat is suspected. Additionally, a large amount of echogenic free fluid is noted.

INTERPRETATION OF THE FINDINGS & FURTHER RECOMMENDATIONS

The patient was reportedly humanely euthanized following this exam under the guidance of attending internist.





The information and recommendations provided are based on the images presented by the referring veterinarian/sonographer. No evaluation can be communicated regarding pathology that was not visible in the image/video clips provided.

Thank you for this referral. If the clinical or image interpretation does not parallel your findings or if I can be of any further assistance please contact me.

Beth Johnson, DVM, DACVIM
info@sonopath.com