

PATIENT

Cleopatra Townsend

SPECIES

Feline

BREED

Bengal

SEX

Spayed Female

AGE

9 Years

WEIGHT

6.45 kg

INTERPRETED BY

Beth Johnson, DVM
DACVIM

IMAGING PERFORMED BY

Crystal Hill

HOSPITAL NAME

Buck Animal Hospital

REFERRING VET

Dr. MacFarlane

INVOICE

44577

DATE

8/2/23

PRESENTING CLINICAL SIGNS

Presented April 19 for decreased appetite, occasional vomiting and lethargy. BW revealed pancreatitis and found a UTI. Treated with Convenia. Sent home with oral Buprenorphine as well Presented again July 25 for vomiting again for about 1 week, lethargic. Repeated meds.

ULTRASONOGRAPHIC EXAMINATION OF THE ABDOMEN

Urinary System

The urinary bladder is moderately distended with anechoic contents. No masses, inflammatory changes, echogenic sediment or cystoliths are observed. The urinary bladder, trigone and visible pelvic urethra are normal in thickness with a smooth mucosal surface.

The right kidney is normal in size (4.57 cm), shape and echogenicity. It has smooth peripheral margination. There is a normal 1:3 cortex to medulla ratio with appropriate corticomedullary distinction. There is no evidence of pyelectasia or infarcts observed. Non-obstructive nephrolithiasis is present.

The left kidney is normal in size (4.1 cm), shape and echogenicity. It has smooth peripheral margination. There is a normal 1:3 cortex to medulla ratio with appropriate corticomedullary distinction. There is no evidence of pyelectasia or infarcts observed. Non-obstructive nephrolithiasis is present.

Adrenal Glands

The right adrenal gland is normal in size (0.46 cm), shape and contour. Corticomedullary structure is unremarkable. Visible surrounding vasculature appears normal.

The left adrenal gland is normal in size (0.50 cm), shape and contour. Corticomedullary structure is unremarkable. Visible surrounding vasculature appears normal.

Spleen

The spleen is subjectively normal in size with a normal smooth capsular contour. Parenchyma is appropriately finely textured and homogenous with normal echogenicity relative to surrounding tissue (hyperechoic to liver). No focal nodules or masses are observed. Splenic vasculature appears normal.

Liver

The liver is subjectively normal in size with normal smooth curvilinear peripheral contour. Parenchyma is appropriately hypoechoic to the spleen in echogenicity and appropriately mildly coarse and homogenous in echotexture. No focal lesions are observed. Visible vasculature and biliary tree appear normal without distension or congestion.

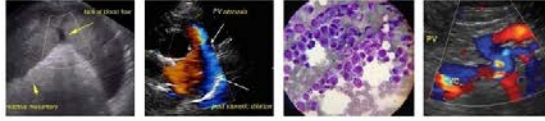
The gallbladder is non-distended in size. The wall is smooth without visible thickening. Luminal contents are primarily anechoic. There is no evidence of cystic or common bile duct dilation.

Gastrointestinal

The stomach wall is normal in thickness (canine < 0.5 cm and feline < 0.4 cm) and layering. The lumen of the stomach is empty with no evidence of obstruction, foreign material or infiltrative disease. Pyloric outflow tract appears patent.



PATIENT	The visible small intestine demonstrates areas of thick muscularis layer relative to mucosa (disruption of the normal 1:3 muscularis:mucosa ratio). Small intestinal submucosa is slightly irregular, thick and hyperechoic, without evident loss of layering appreciated. The lumen is empty with no evidence of obstruction or foreign material.
Cleopatra Townsend	
SPECIES	The visible colon is normal in wall thickness (< 0.2 cm) and layering. Contents are consistent with normal formed feces and gas.
Feline	
BREED	<i>Pancreas</i>
Bengal	The pancreatic parenchyma is appropriately isoechoic to surrounding tissue. Visible capsule is smooth and normal in contour. There is no visible pancreatic duct dilation. There is no evidence of active peripancreatic inflammation.
SEX	<i>Free Abdomen</i>
Spayed Female	There is no evidence of free peritoneal effusion noted in these images.
AGE	There is no apparent lymphadenopathy noted in these images.
9 Years	
WEIGHT	ULTRASONOGRAPHIC FINDINGS
6.45 kg	<ul style="list-style-type: none"> Inflammatory bowel disease (IBD) pattern – Thick muscularis has been reported with infiltrative bowel disease including both benign inflammatory disease as well as infiltrative neoplasia such as lymphoma. No aggressive lymphadenopathy, loss of layering, etc. is noted to make lymphoma more probable, but lymphoma cannot be definitively ruled out without tissue sampling. Non-obstructive nephroliths bilaterally.
INTERPRETED BY	<u>INTERPRETATION OF THE FINDINGS & FURTHER RECOMMENDATIONS</u>
Beth Johnson, DVM DACVIM	A recheck general metabolic health screen is recommended, if not already evaluated, to include CBC/Chem panel and electrolytes.
IMAGING PERFORMED BY	Urinalysis and, if indicated based on urinalysis results, urine culture are recommended. If protein is present in an otherwise quiet sediment, protein quantification with a urine protein to creatinine ratio is recommended.
Crystal Hill	Pending results, A gastrointestinal malabsorption panel (including cobalamin, folate, TLI and PLI) to Texas A&M GI Laboratory is recommended for further evaluation of GI and pancreatic function.
HOSPITAL NAME	Ideally, biopsies of the GI tract, being sure to include ileum if possible, are recommended to definitively diagnose and therefore manage the infiltrative bowel disease.
Buck Animal Hospital	If biopsies cannot be obtained, empirical therapies could include a probiotic (if diarrhea is present, such as visbiome or proviable), empirical deworming with a 5-day course of Panacur and, if tolerated, a transition in diet, based on trial-and-error response, beginning with a hydrolyzed protein diet. Some patients respond to one brand/version of a hydrolyzed protein diet better than another brand, so several trials may be required.
REFERRING VET	
Dr. MacFarlane	
INVOICE	
44577	
DATE	
8/2/23	



PATIENT

Cleopatra Townsend

Additional considerations could include cobalamin supplementation (unless cobalamin level is evaluated and supplementation is not warranted) and prednisolone (if not contraindicated based on patient contraindications, co-morbidities, etc.).

SPECIES

Feline

BREED

Bengal

SEX

Spayed Female

AGE

9 Years

WEIGHT

6.45 kg

INTERPRETED BY

Beth Johnson, DVM
DACVIM

IMAGING PERFORMED BY

Crystal Hill

HOSPITAL NAME

Buck Animal Hospital

REFERRING VET

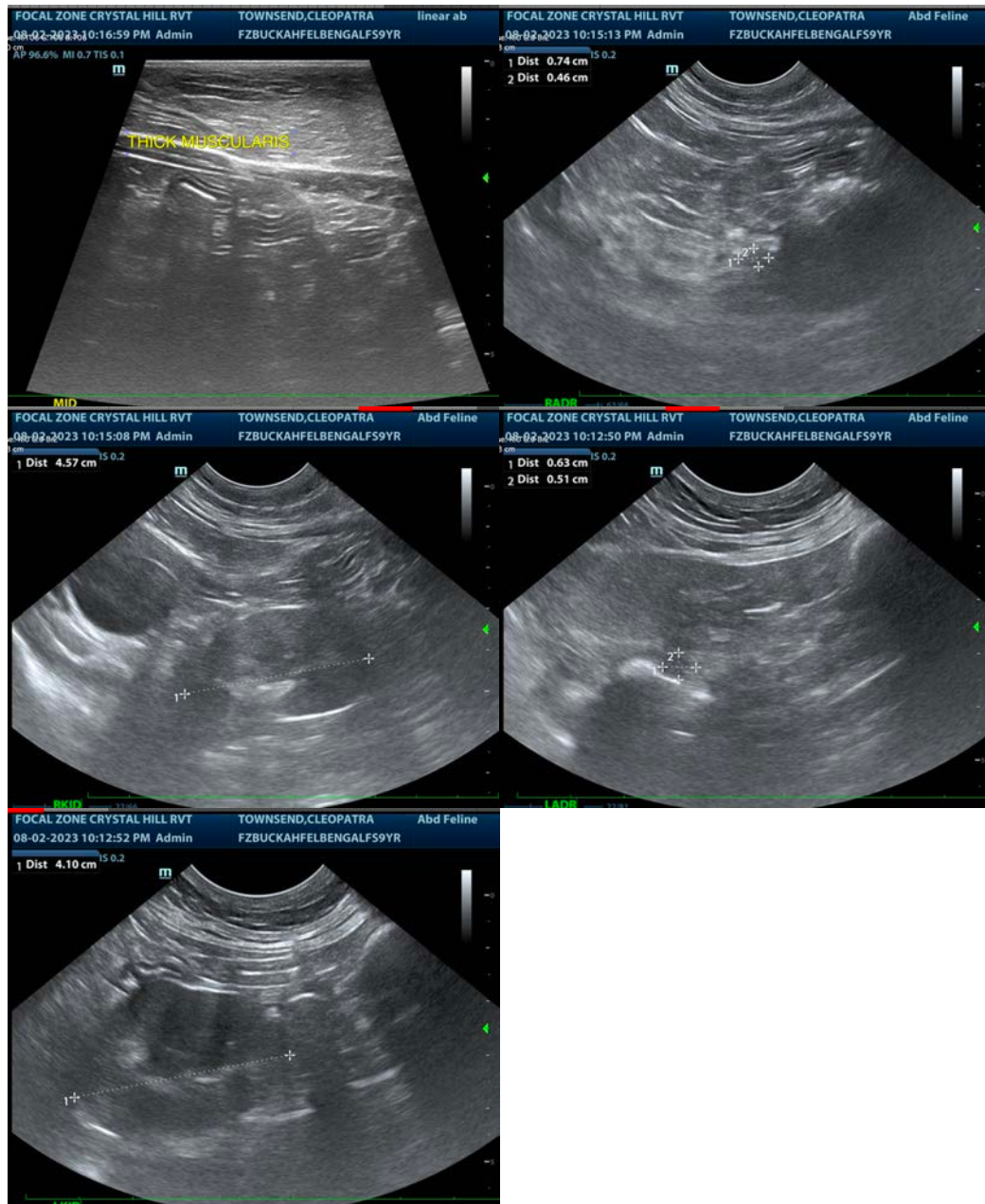
Dr. MacFarlane

INVOICE

44577

DATE

8/2/23





PATIENT

Cleopatra Townsend

The information and recommendations provided are based on the images presented by the referring veterinarian/sonographer. No evaluation can be communicated regarding pathology that was not visible in the image/video clips provided.

SPECIES

Feline

Thank you for this referral. If the clinical or image interpretation does not parallel your findings or if I can be of any further assistance please contact me.

BREED

Bengal

Beth Johnson, DVM, DACVIM
info@sonopath.com

SEX

Spayed Female

AGE

9 Years

WEIGHT

6.45 kg

INTERPRETED BY

Beth Johnson, DVM
DACVIM

IMAGING PERFORMED BY

Crystal Hill

HOSPITAL NAME

Buck Animal Hospital

REFERRING VET

Dr. MacFarlane

INVOICE

44577

DATE

8/2/23