

**PATIENT**

Beau Beau Orler

SPECIES

Canine

BREED

Silky Terrier

SEX

Neutered Male

AGE

17 Years

WEIGHT

9.6 Pounds

INTERPRETED BYBeth Johnson, DVM
DACVIM**IMAGING PERFORMED BY**

Amy Mayhew, LVT

HOSPITAL NAME

SVS Imaging MI

REFERRING VET

Dr. Notarius

INVOICE

44573

DATE

8/2/23

PRESENTING CLINICAL SIGNS

History of elevated liver enzymes, on denamarin and actigal. Previous cholecystectomy.

ULTRASONOGRAPHIC EXAMINATION OF THE ABDOMEN**Urinary System**

The urinary bladder is moderately distended with anechoic contents. No masses, inflammatory changes, echogenic sediment or cystoliths are observed. The urinary bladder, trigone and visible pelvic urethra are normal in thickness with a smooth mucosal surface.

Prostate is normal in size, echotexture and echogenicity for a neutered male.

Kidneys are overall normal in size and shape with smooth peripheral margination. A normal 1:3 cortex to medulla ratio is maintained. The medulla and cortices are uniform in texture with some mild increased cortical echogenicity and mild loss of corticomedullary distinction, expected in this age patient. There is no evidence of infarcts observed. Punctate non-obstructive nephroliths are noted bilaterally. Trace pyelectasia is noted bilaterally. The left kidney measures 3.87 cm. The right kidney measures 3.62 cm.

Adrenal Glands

The right adrenal gland is normal in size (0.41 cm at the caudal pole), shape and contour. Corticomedullary structure is unremarkable. Visible surrounding vasculature appears normal. The cranial pole is difficult to fully visualize in these images.

The left adrenal gland is normal in size (0.43 cm at the cranial pole and 0.47 cm at the caudal pole), shape and contour. Corticomedullary structure is unremarkable. Visible surrounding vasculature appears normal.

Spleen

The spleen is subjectively normal in size with a normal smooth capsular contour. Parenchyma is appropriately finely textured and homogenous with normal echogenicity relative to surrounding tissue (hyperechoic to liver). No focal nodules or masses are observed. Splenic vasculature appears normal.

Liver

Liver is relatively normal in size and contour. Parenchyma is mildly heterogenous and coarse with mild likely age-related parenchymal remodeling noted. No focal lesions are observed. Visible vasculature and biliary tree appear normal without distension or congestion.

The gallbladder has been previously removed.

Gastrointestinal

The stomach wall is normal in thickness (canine < 0.5 cm and feline < 0.4 cm) and layering. The lumen of the stomach is empty with no evidence of obstruction, foreign material or infiltrative disease. Pyloric outflow tract appears patent.

The visible small intestines are normal in wall thickness and layering. Small intestinal motility appears adequate (1-3 contractions per min). The lumen of the small intestine is mildly distended with echogenic

IMAGING PERFORMED BY

SVS Mobile Imaging MI 734-637-7711
svsimagingmi@gmail.com



PATIENT

Beau Beau Orler

SPECIES

Canine

BREED

Silky Terrier

SEX

Neutered Male

AGE

17 Years

WEIGHT

9.6 Pounds

INTERPRETED BY

Beth Johnson, DVM
DACVIM

IMAGING PERFORMED BY

Amy Mayhew, LVT

HOSPITAL NAME

SVS Imaging MI

REFERRING VET

Dr. Notarius

INVOICE

44573

DATE

8/2/23

non-shadowing luminal contents and gas consistent with normal ingesta. There is no evidence of obstruction, foreign material or infiltrative disease.

The visible colon is normal in wall thickness (< 0.2 cm) and layering. Contents are consistent with normal formed feces and gas.

Pancreas

The pancreatic parenchyma is appropriately isoechoic to surrounding tissue. Visible capsule is smooth and normal in contour. There is no visible pancreatic duct dilation. There is no evidence of active peripancreatic inflammation.

Free Abdomen

There is no evidence of free peritoneal effusion noted in these images.

There is no pathologic lymphadenopathy noted in these images.

ULTRASONOGRAPHIC FINDINGS

- This is a relatively unremarkable/normal geriatric abdomen with age related changes, non-obstructive nephroliths bilaterally, and trace pyelectasia bilaterally in the kidneys.
- An obvious cause for the reported increased liver enzymes is not identified in these images. Microscopic disease such as Leptospirosis, bacterial cholangiohepatitis, chronic active hepatitis, copper-associated hepatotoxicity, other hepatotoxicity, infiltrative neoplasia (considered unlikely), etc. cannot be definitively ruled out.
- This patient’s gallbladder has been previously removed.

INTERPRETATION OF THE FINDINGS & FURTHER RECOMMENDATIONS

If not recently evaluated, given this patient’s reported azotemia, a urinalysis and, if indicated based on urinalysis results, urine culture are recommended. If protein is present in an otherwise quiet sediment, protein quantification with a urine protein to creatinine ratio is recommended.

Recommendations include an “antigen search” for sources of reactive hepatopathy (including testing for Leptospirosis), followed by a course of empirical antibiotics and hepatic nutraceuticals, with monitoring of ALT for improvement. If improvement is noted, antibiotics should be continued until liver enzymes either normalize or plateau (recheck every 2-3 weeks); however, if improvement is not noted and/or enzyme increase progresses, antibiotics should not be continued long term and sampling, beginning with a FNA of the liver if patient’s coagulation status is appropriate or progressing to a liver biopsy (including copper level assessment) may ultimately be warranted.

IMAGING PERFORMED BY

SVS Mobile Imaging MI ☎ 734-637-7711
svsimagingmi@gmail.com



PATIENT

Beau Beau Orler

SPECIES

Canine

BREED

Silky Terrier

SEX

Neutered Male

AGE

17 Years

WEIGHT

9.6 Pounds

INTERPRETED BY

Beth Johnson, DVM
DACVIM

IMAGING PERFORMED BY

Amy Mayhew, LVT

HOSPITAL NAME

SVS Imaging MI

REFERRING VET

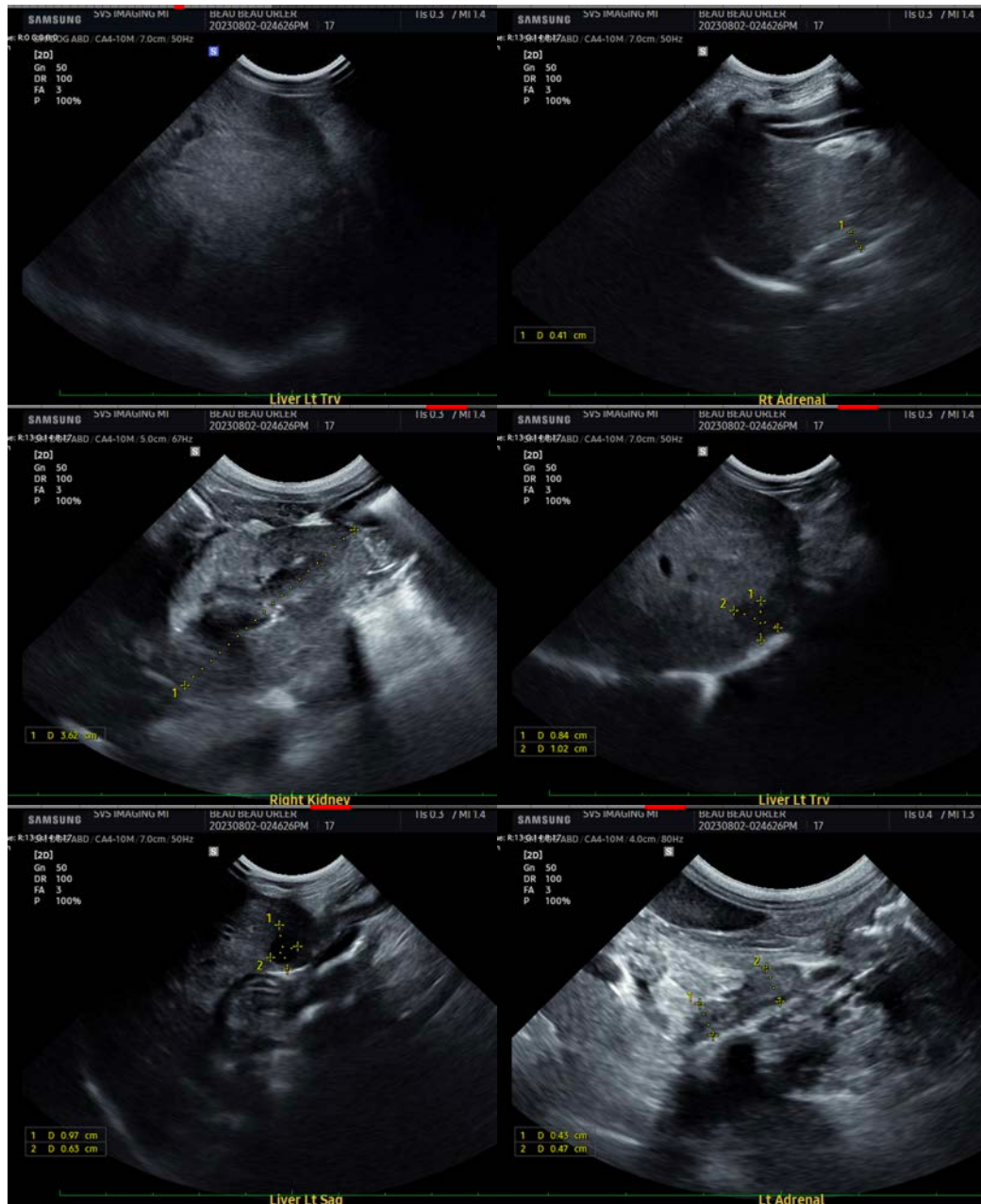
Dr. Notarius

INVOICE

44573

DATE

8/2/23



IMAGING PERFORMED BY

SVS Mobile Imaging MI 734-637-7711
svsimagingmi@gmail.com



Clinical Sonography & Telecytology

EDUCATIONAL TELECONSULTATION SERVICES™

1-800-838-4268 info@sonopath.com SonoPath.com

PATIENT

Beau Beau Orler

SPECIES

Canine

BREED

Silky Terrier

SEX

Neutered Male

AGE

17 Years

WEIGHT

9.6 Pounds

INTERPRETED BY

Beth Johnson, DVM
DACVIM

IMAGING PERFORMED BY

Amy Mayhew, LVT

HOSPITAL NAME

SVS Imaging MI

REFERRING VET

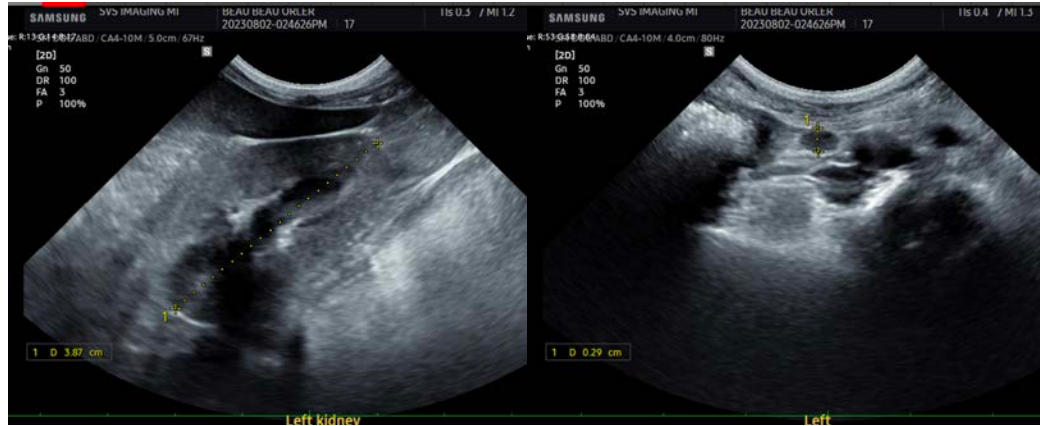Dr. Notarius

INVOICE

44573

DATE

8/2/23



The information and recommendations provided are based on the images presented by the referring veterinarian/sonographer. No evaluation can be communicated regarding pathology that was not visible in the image/video clips provided.

Thank you for this referral. If the clinical or image interpretation does not parallel your findings or if I can be of any further assistance please contact me.

Beth Johnson, DVM, DACVIM
info@sonopath.com