



PATIENT PRESENTING CLINICAL SIGNS

PATIENT Buttons Toms
SPECIES Canine
BREED Boston Terrier
SEX Spayed Female
AGE 3 Years
WEIGHT 11 kg

started vomiting Thursday, went to the rDVM on Friday, and got medications (steroid, Cerenia), but patient is still vomiting. Previous Health Concerns: Allergies Current Medications/Supplements/OTC: Reglan as needed Appetite/When did they eat last: Not eating Since Wed Diet: Dry- Nutro Vomiting/Diarrhea: V+ Coughing/Sneezing: -- Urination: Normal Indoor/Outdoor: Indoor Mostly Any changes in their environment: None Vaccines up to Date: Yes HW/Flea/Tick Prevention: No Abnormal PE/Chem/CBC/UA Results: MM/CRT: pink, tacky, crt <2 Level of Pain: (0-4) 2 BCS (0-5): 4 Oral-Nasal-Throat: underbite, hair stuck in teeth Abdominal: bloated, tucks away with palpation Integument: erythema and scabs on ventral abdomen 2/6 heart murmur noted 8/2/22 Results of Diagnostics: 1) 2V Abdomen – stomach and intestines empty, small amount of gas in colon, decreased serosal detail in cranial abdomen 2) CBC/Chem/EPOC – mild ALP elevation, stress hyperglycemia, amylase & lipase too high to read, leukocytosis with left shift 3) cPL - abnormal

ULTRASONOGRAPHIC EXAMINATION OF THE ABDOMEN

Urinary System

The urinary bladder is moderately distended with anechoic contents. No masses, inflammatory changes, echogenic sediment or cystoliths are observed. The urinary bladder, trigone and visible pelvic urethra are normal in thickness with a smooth mucosal surface.

The right kidney is normal in size (5.51 cm), shape and echogenicity. It has smooth peripheral margination. There is a normal 1:3 cortex to medulla ratio with appropriate corticomedullary distinction. There is no evidence of pyelectasia, mineral or infarcts observed.

The left kidney is normal in size (5.3 cm), shape and echogenicity. It has smooth peripheral margination. There is a normal 1:3 cortex to medulla ratio with appropriate corticomedullary distinction. There is no evidence of pyelectasia, mineral or infarcts observed.

Adrenal Glands

The area of the right adrenal gland is examined without evident pathology.

The left adrenal gland is normal in size (1.7 cm long x 0.40 cm at the cranial pole and 0.59 cm at the caudal pole), shape and contour. Corticomedullary structure is unremarkable. Visible surrounding vasculature appears normal.

Spleen

The spleen is subjectively normal in size with a normal smooth capsular contour. Parenchyma is appropriately finely textured and homogenous with normal echogenicity relative to surrounding tissue (hyperechoic to liver). No focal nodules or masses are observed. Splenic vasculature appears normal.

Liver

The liver is subjectively normal in size with normal smooth curvilinear peripheral contour. Parenchyma is appropriately hypoechoic to the spleen in echogenicity and appropriately mildly coarse and homogenous in echotexture. No focal lesions are observed. Visible vasculature and biliary tree appear normal without distension or congestion.

The gallbladder is non-distended in size. The wall is smooth without visible thickening. Luminal contents are primarily anechoic. There is no evidence of cystic or common bile duct dilation.

INTERPRETED BY

Beth Johnson, DVM
DACVIM

IMAGING PERFORMED BY

Erin Wicks

HOSPITAL NAME

Shores VEC

REFERRING VET

Dr. Lupole

INVOICE

40025

DATE

8/2/22



PATIENT

Gastrointestinal

Buttons Toms

The stomach wall is normal in thickness (canine < 0.5 cm and feline < 0.4 cm) and layering. The lumen of the stomach is moderately distended with anechoic fluid. There is no evidence of obstruction, foreign material or infiltrative disease. Pyloric outflow tract appears patent.

SPECIES

Canine

The visible small intestines are normal in wall thickness and layering (canine duodenum < 0.5 cm and feline duodenum < 0.4 cm; other < 0.3 cm). Small intestinal motility appears adequate (1-3 contractions per min). The lumen of the small intestine is empty with no evidence of obstruction, foreign material or infiltrative disease.

BREED

Boston Terrier

The visible colon is normal in wall thickness (< 0.2 cm) and layering. Contents are consistent with normal formed feces and gas.

SEX

Pancreas

Spayed Female

The observed pancreas is prominent (enlarged) in size, hypoechoic to surrounding tissue and irregular in shape with a swollen undulating contour. Enhanced hyperechoic ill-defined surrounding fat is noted. Just caudal to the stomach, there is a 2.5 cm x 4.0 cm hypo- to anechoic structure that appears to be walled off by enhanced hyperechoic fat and mesentery, consistent with an inflamed acute pancreatitis. However, an early emerging cyst or abscess or necrosis can't be ruled out.

AGE

3 Years

Free Abdomen

WEIGHT

11 kg

There is no evidence of free peritoneal effusion noted in these images.

There is no apparent lymphadenopathy noted in these images.

ULTRASONOGRAPHIC FINDINGS

INTERPRETED BY

- Severe acute pancreatitis with early pancreatic cyst, abscess or necrosis unable to be definitively ruled out.

Beth Johnson, DVM
DACVIM

INTERPRETATION OF THE FINDINGS & FURTHER RECOMMENDATIONS

IMAGING PERFORMED BY

A quantitative PLI is recommended, if not recently evaluated.

Erin Wicks

Medical management of pancreatitis with anti-emetics, gastroprotectants, appetite stimulants or nutritional support as needed (with low-fat diet), pain management, broad spectrum antibiotics, and fluid therapy is recommended. If possible, a fresh frozen plasma transfusion and hyperbaric oxygen therapy (HBOT) could be beneficial. Monitoring of the pancreas with power doppler is recommended to identify possible necrosis as well as other potential sequelae such as abscesses, etc.

HOSPITAL NAME

Shores VEC

REFERRING VET

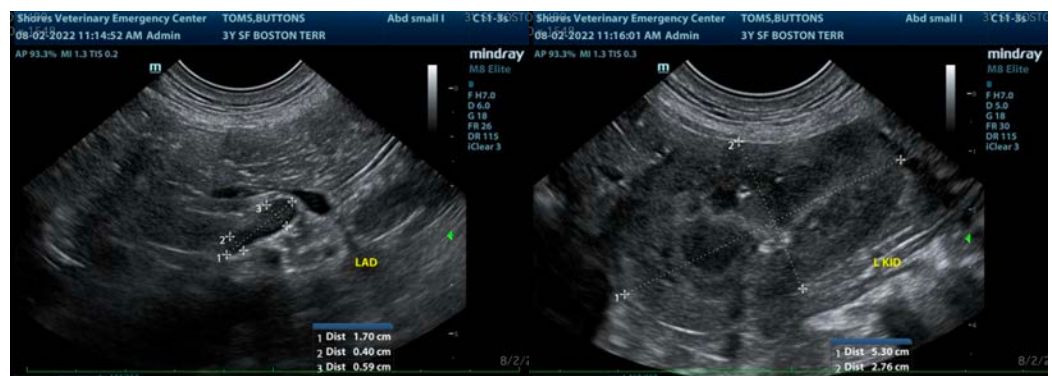
Dr. Lupole

INVOICE

40025

DATE

8/2/22





PATIENT

Buttons Toms

SPECIES

Canine

BREED

Boston Terrier

SEX

Spayed Female

AGE

3 Years

WEIGHT

11 kg

INTERPRETED BY

Beth Johnson, DVM
DACVIM

IMAGING PERFORMED BY

Erin Wicks

HOSPITAL NAME

Shores VEC

REFERRING VET

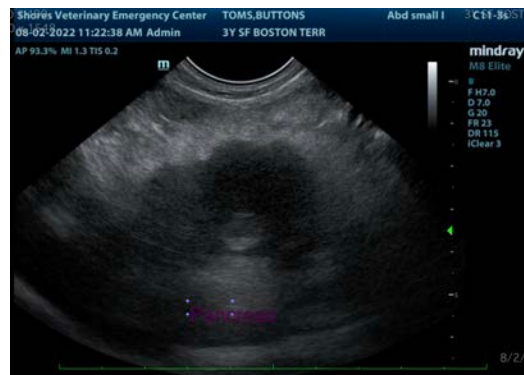
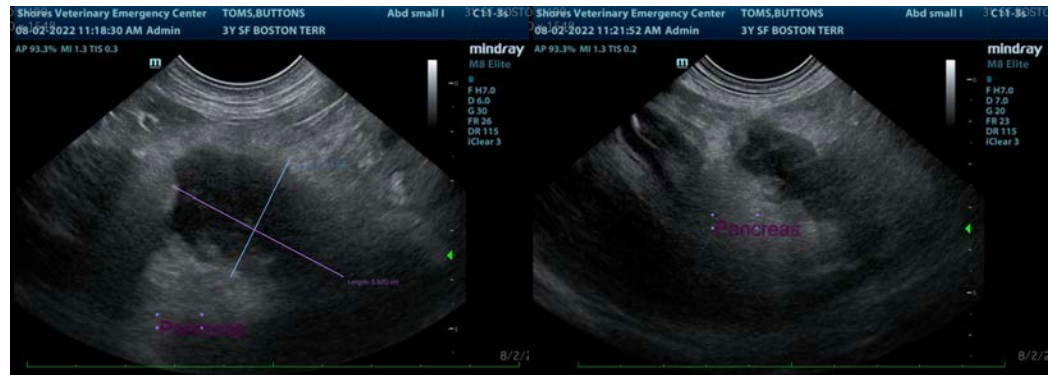
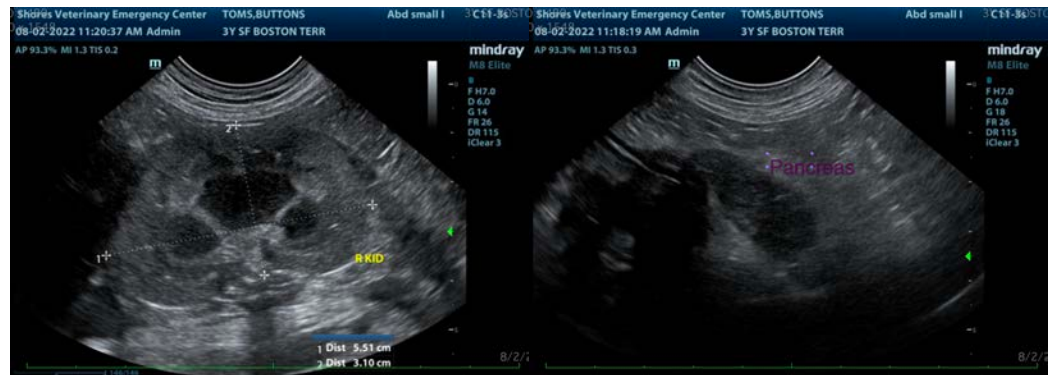
Dr. Lupole

INVOICE

40025

DATE

8/2/22



The information and recommendations provided are based on the images presented by the referring veterinarian/sonographer. No evaluation can be communicated regarding pathology that was not visible in the image/video clips provided.

Thank you for this referral. If the clinical or image interpretation does not parallel your findings or if I can be of any further assistance please contact me.

Beth Johnson, DVM, DACVIM
Beth.Johnson@sonopath.com