

**DATE PRESENTING CLINICAL SIGNS**

8/18/22 Presented for inappetence, no interest in food for about 1 week. Some nibbling but overall not very interested. NSF on physical exam.

PATIENT

Rylee Keck Current Medications: Cerenia 24mg ½ SID. Added in Entyce 30mg/mL 0.5mL SID.
Lab Results: ALT >460, ALP 198, Tbili 1.0. 3+ bilirubin on urinalysis.

Date of Previous IntraPet Ultrasound: No previous.

SPECIES

Sedation: Not required to complete full diagnostic ultrasound.
Stat Report: Not requested.

Canine

ULTRASONOGRAPHIC EXAMINATION OF THE ABDOMEN**BREED****Urinary System**

Mixed

The urinary bladder is moderately distended with anechoic contents. No masses, inflammatory changes, echogenic sediment or cystoliths are observed. The urinary bladder, trigone and visible pelvic urethra are normal in thickness with a smooth mucosal surface.

SEX

Spayed Female

The right kidney is normal in size (3.74 cm), shape and echogenicity. It has smooth peripheral margination. There is a normal 1:3 cortex to medulla ratio with appropriate corticomedullary distinction. There is no evidence of pyelectasia, mineral or infarcts observed. A hyperechoic band parallel to the corticomedullary border is present.

AGE

8/3/13

The left kidney is normal in size (4.4 cm), shape and echogenicity. It has smooth peripheral margination. There is a normal 1:3 cortex to medulla ratio with appropriate corticomedullary distinction. There is no evidence of pyelectasia, mineral or infarcts observed. A hyperechoic band parallel to the corticomedullary border is present.

WEIGHT

10.4 Pounds

INTERPRETED BY

Beth Johnson, DVM
DACVIM

Adrenal Glands

Adrenal glands are small (flattened contour). Corticomedullary structure is unremarkable. Visible surrounding vasculature appears normal. The left adrenal gland measured 1.0 cm long x 0.24 cm at the cranial pole and 0.26 cm at the caudal pole. The right adrenal gland measured 1.34 cm x 0.35 cm at the cranial pole and 0.32 cm at the caudal pole.

IMAGING PERFORMED BY

Stephanie Warga
RDCS, RVT

Spleen

The spleen is subjectively normal in size with a normal smooth capsular contour. Parenchyma is appropriately finely textured and homogenous with normal echogenicity relative to surrounding tissue (hyperechoic to liver). No focal nodules or masses are observed. Splenic vasculature appears normal.

HOSPITAL NAME

Everhart Vet Hospital

Liver

Liver is subjectively enlarged (swollen contour) without disruption of architecture. It has a normal homogenous echotexture. Parenchyma is diffusely hyperechoic characterized by less prominent than normal portal vein walls and increased echogenicity relative to the spleen and falciform fat. No focal lesions are observed. Visible vasculature and biliary tree appear normal without distension or congestion.

REFERRING VET

Dr. Betta

INVOICE

40603

Gastrointestinal

The stomach wall is normal in thickness (canine < 0.5 cm and feline < 0.4 cm) and layering. The lumen of the stomach is empty with no evidence of obstruction, foreign material or infiltrative disease. Pyloric outflow tract appears patent.

The visible small intestines are normal in wall thickness and layering (canine duodenum < 0.5 cm and feline duodenum < 0.4 cm; other < 0.3 cm). Small intestinal motility appears adequate (1-3 contractions per min). The lumen of the small intestine is empty with no evidence of obstruction, foreign material or infiltrative disease.

The visible colon is normal in wall thickness (< 0.2 cm) and layering. Contents are consistent with normal formed feces and gas.

Pancreas

The observed pancreas is prominent (enlarged) in size, hypoechoic to surrounding tissue and irregular in shape with a swollen undulating contour. Enhanced hyperechoic ill-defined surrounding fat is noted.

Free Abdomen

There is no evidence of free peritoneal effusion noted in these images.

Mild reactive medial iliac lymphadenopathy is noted.

In the cranial abdomen, around the liver and the area of the pancreas, the mesentery is mildly enhanced/hyperechoic.

PRIMARY FINDINGS

- **Hyperechoic hepatomegaly** - This appearance is non-specific and most consistent with a benign steroid (endocrine) or vacuolar hepatopathy or reactive or idiopathic hepatopathy. Inflammatory and/or infiltrative disease (such as round cell neoplasia) are also possible, but considered less likely.
- **Mild gallbladder debris** - Cholecystic debris is of unknown clinical significance. It can be seen with biliary stasis from fasting or illness. Cholecystic debris is not necessarily related to hepatobiliary disease. Echogenic bile is most commonly an incidental finding in dogs and should be interpreted in combination with clinical signs such as nausea, inappetence, cranial abdominal discomfort and/or laboratory changes such as increased ALP and/or increased Tbili.
- Mild acute pancreatitis suspected
- **Flat adrenal glands** - This can be a normal patient variant and/or a sign of exogenous cortisol administration. If exogenous steroids are not being administered, hypoadrenocorticism (either relative or absolute) should be considered.

SECONDARY FINDINGS

- **Bilateral medullary rim sign** - This finding is of unknown clinical significance and can be a normal variant, often idiopathic. Medullary rim sign can be present with renal disease including FIP, lymphoma, hypercalcemic nephropathy, Leptospirosis, tubular disease, other and should be interpreted in combination with other more specific indications of kidney disease such as isosthenuria, proteinuria, azotemia, etc. This is a common incidental finding in patients with diabetes mellitus.

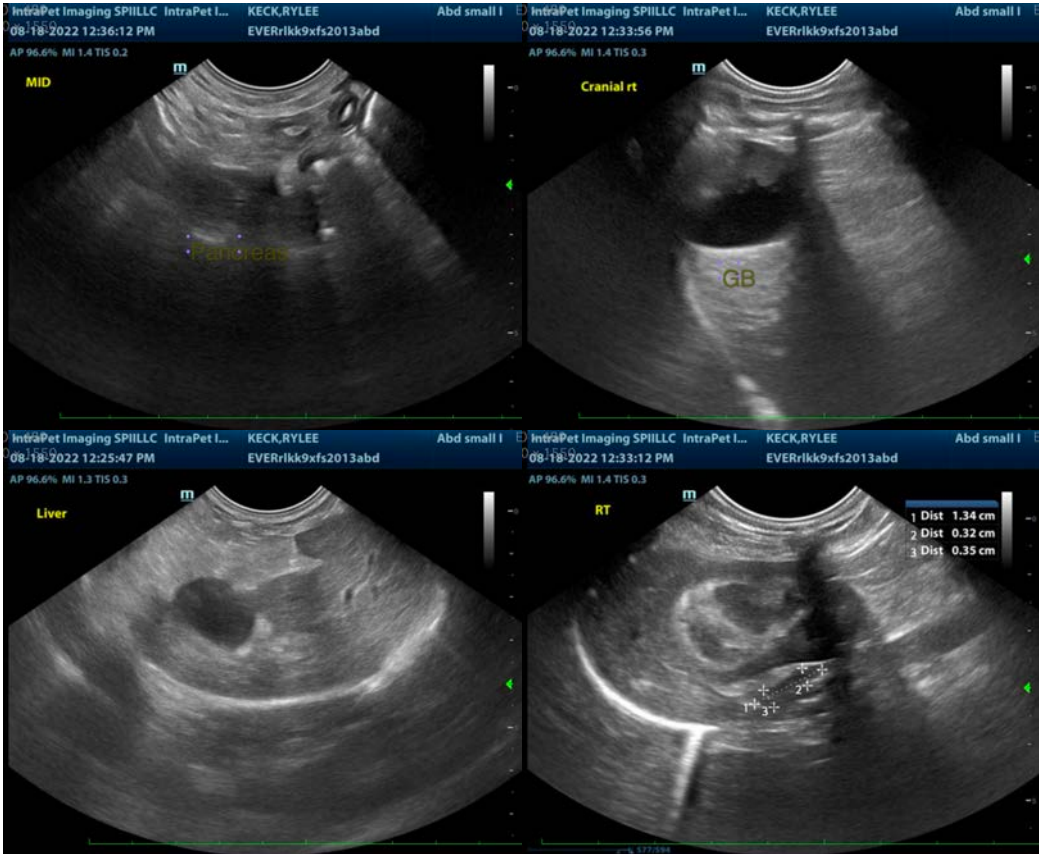
INTERPRETATION OF THE FINDINGS & FURTHER RECOMMENDATIONS

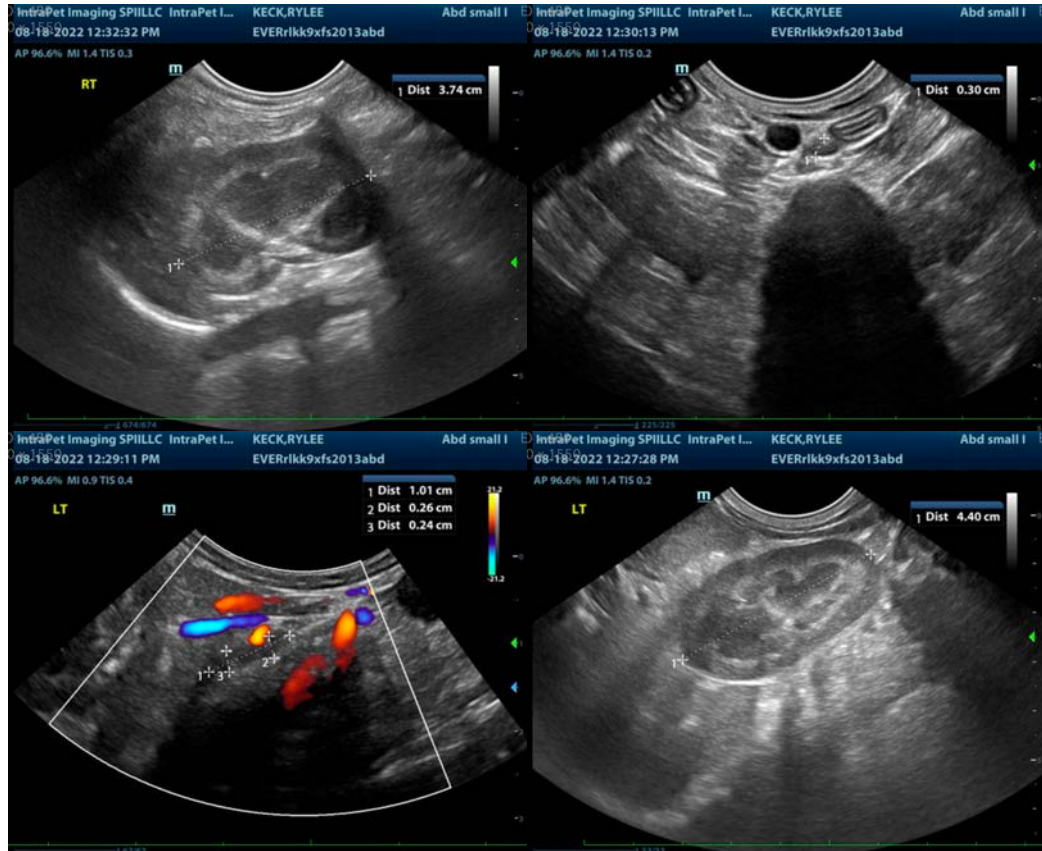
Given this patient's subjectively flat adrenal glands and inappetence, a baseline cortisol is recommended. If baseline cortisol is less than 2, a full ACTH stimulation test is recommended to rule out hypoadrenocorticism.

Given the reported liver increases combined with the ultrasonographic changes, differentials include a non-specific hepatopathy as can be seen with microscopic diseases such as Leptospirosis, bacterial cholangiohepatitis, chronic active hepatitis, copper associated hepatotoxicity, other hepatotoxicity, less likely infiltrative neoplasia, etc., combined with possibly mild acute pancreatitis.

Therefore, other recommendations include a quantitative PLI (if not recently evaluated) as well as an "antigen search" for sources of reactive hepatopathy (including testing for Leptospirosis), followed by a course of empirical antibiotics and hepatic nutraceuticals, with monitoring of ALT for improvement. If improvement is not noted and/or enzyme increase progresses, a liver fine needle aspirate or biopsy may be warranted.

Additional therapeutic recommendations include supportive/symptomatic medical management of clinical signs with antiemetics, gastroprotectants, and an appetite stimulant, +/- pain management and fluid support, if indicated.





The information and recommendations provided are based on the images presented by the referring veterinarian/sonographer. No evaluation can be communicated regarding pathology that was not visible in the image/video clips provided.

Thank you for this referral. If the clinical or image interpretation does not parallel your findings or if I can be of any further assistance please contact me.

Beth Johnson, DVM, DACVIM
Beth.Johnson@sonopath.com