

**DATE PRESENTING CLINICAL SIGNS**

8/18/22 Chronic vomiting, diarrhea, weight loss, and low normal albumin.

PATIENT Current Medications: None listed.

Oliver Nape

Lab Results: Senior labwork Nov 2021 – unremarkable.

Date of Previous IntraPet Ultrasound: No previous.

Sedation: Gabapentin PO and Torbugesic IV. Gaba given about 45 minutes prior to scan.

Stat Report: Not requested.

SPECIES

Feline

ULTRASONOGRAPHIC EXAMINATION OF THE ABDOMEN**BREED**

DSH

SEX

Neutered Male

Urinary System

Urinary bladder is adequately distended. It has a normal uniform wall thickness. Contents include primarily anechoic fluid with occasional echogenic non-shadowing debris, most consistent with incidental suspended lipid in a cat, possibly combined with exfoliated cells, mucous and/or small blood clots. Both sterile inflammation as well as urinary tract infection can also present with echogenic debris. No masses or cystoliths are observed. The trigone and visible pelvic urethra are normal in thickness with a smooth mucosal surface.

AGE

9/1/09

The right kidney is normal in size (3.45 cm), shape and echogenicity. It has smooth peripheral margination. There is a normal 1:3 cortex to medulla ratio with appropriate corticomedullary distinction. There is no evidence of pyelectasia, mineral or infarcts observed.

WEIGHT

8.78 Pounds

The left kidney is normal in size (3.68 cm), shape and echogenicity. It has smooth peripheral margination. There is a normal 1:3 cortex to medulla ratio with appropriate corticomedullary distinction. There is no evidence of pyelectasia, mineral or infarcts observed.

INTERPRETED BYBeth Johnson, DVM
DACVIM**Adrenal Glands**

The right adrenal gland is normal in size (0.40 cm thick), shape and contour. Corticomedullary structure is unremarkable. Visible surrounding vasculature appears normal.

IMAGING PERFORMED BYStephanie Warga
RDCS, RVT

The left adrenal gland is normal in size (0.42 cm thick), shape and contour. Corticomedullary structure is unremarkable. Visible surrounding vasculature appears normal.

HOSPITAL NAME

Noth Laurel AH

Spleen

Spleen is subjectively normal in size with a normal smooth capsular contour. Parenchyma is appropriately finely textured and homogenous with normal echogenicity relative to surrounding tissue (hyperechoic to liver). Multifocal well-demarcated hyperechoic homogenous nodules are noted. Splenic vasculature appears normal.

REFERRING VET

Dr. Nelson

Liver

The liver is subjectively normal in size with normal smooth curvilinear peripheral contour. Parenchyma is appropriately hypoechoic to the spleen in echogenicity and appropriately mildly coarse and homogenous in echotexture. No focal lesions are observed. Visible vasculature and biliary tree appear normal without distension or congestion.

INVOICE

40605

The gallbladder is mildly subjectively overdistended in size. The wall is smooth without visible thickening. Luminal contents are primarily anechoic. The cystic and common bile duct are mildly dilated, measuring 0.60 cm, and are tortuous in appearance. There is no visible cause for obstruction in these images.

Gastrointestinal

The stomach wall is normal in thickness (canine < 0.5 cm and feline < 0.4 cm) and layering. The lumen of the stomach is empty with no evidence of obstruction, foreign material or infiltrative disease. Pyloric outflow tract appears patent.

The visible small intestines are normal in wall thickness and layering (canine duodenum < 0.5 cm and feline duodenum < 0.4 cm; other < 0.3 cm). Small intestinal motility appears adequate (1-3 contractions per min). The lumen of the small intestine is empty with no evidence of obstruction, foreign material or infiltrative disease.

The visible colon is normal in wall thickness (< 0.2 cm) and layering. Contents are consistent with normal formed feces and gas.

Pancreas

The observed pancreas is prominent (enlarged) in size, hypoechoic to surrounding tissue and irregular in shape with a swollen undulating contour. Pancreatic duct dilation is noted. Enhanced hyperechoic ill-defined surrounding fat is noted.

Free Abdomen

There is no evidence of free peritoneal effusion noted in these images.

The mesenteric lymph nodes are prominent in size with swollen capsular contour. Normal elongated shape (length to width ratio) is maintained. There is no loss of parenchymal detail.

PRIMARY FINDINGS

- Chronic active smoldering pancreatitis suspected with possible acute on chronic episode unable to be definitively ruled out.
- **Mildly dilated tortuous common bile duct and mildly overdistended gallbladder** – This could be the result of an obstruction from a cholecystolith versus debris versus even a mass or nodule. However, the origin of the obstruction, if present, is not visible in these images. This could also be a residual change from historical or chronic cholangiohepatitis.
- **Reactive mesenteric lymph nodes** – infiltrative neoplastic disease cannot be ruled out but is considered less likely.

SECONDARY FINDINGS

- Urinary bladder debris
- **Hyperechoic splenic nodules** – most consistent with benign myelolipomas. Other differentials such as fibrosis or calcification caused by old hematomas or infarcts, chronic inflammation, granulomatous disease or metastatic disease cannot be ruled out, but are considered less likely.

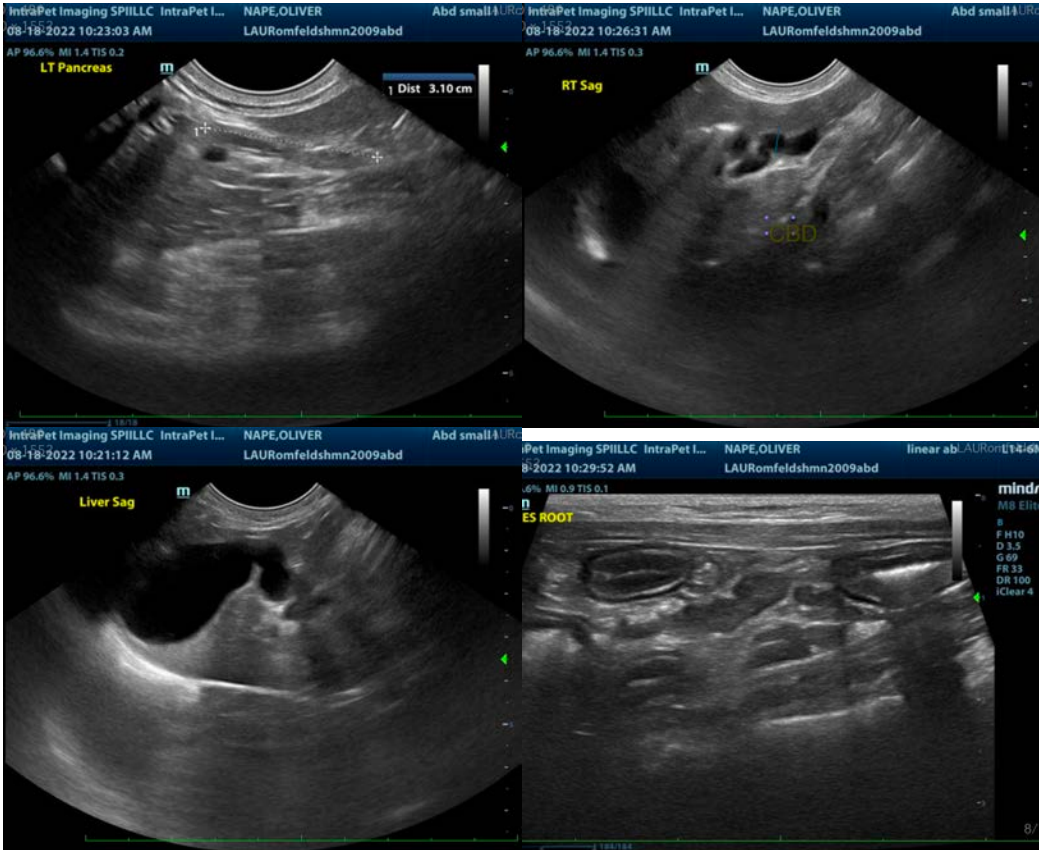
INTERPRETATION OF THE FINDINGS & FURTHER RECOMMENDATIONS

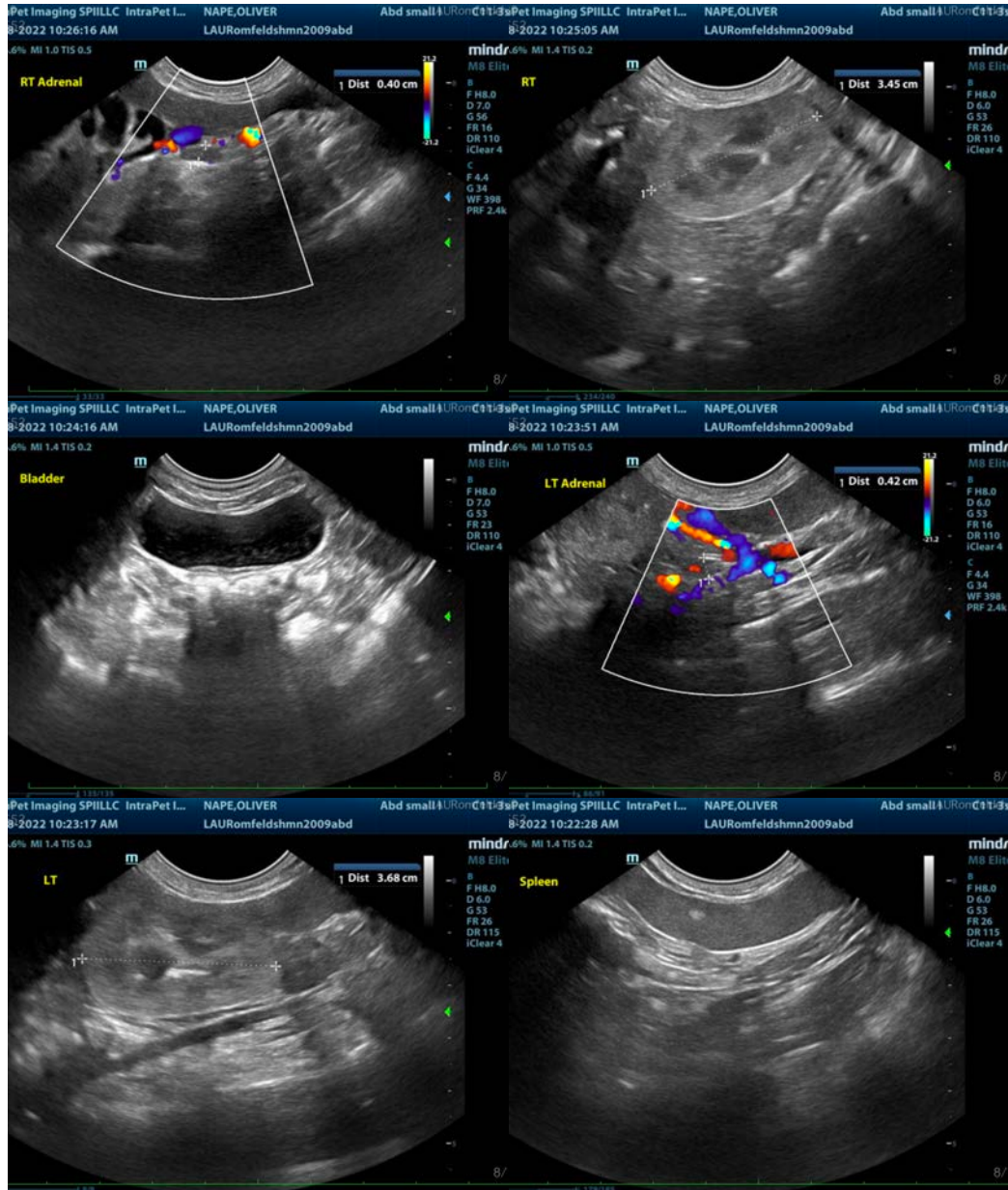
There are no obvious ultrasonographic changes to signify significant gastrointestinal disease. However, that doesn't rule out a malabsorptive condition. Therefore, given this patient's vomiting, diarrhea, weight loss and mildly low albumin, further evaluation is warranted with a gastrointestinal malabsorption panel (including cobalamin, folate, TLI and PLI) to Texas A&M GI Laboratory. A T4 is also recommended if not recently evaluated.

Given the mildly low albumin, a urinalysis and, if indicated based on urinalysis results, urine culture are recommended. If protein is present in an otherwise quiet sediment, protein quantification with a urine protein to creatinine ration is recommended.

With normal liver enzymes, a current or active cholangitis/cholangiohepatitis is considered less likely. However, if liver enzyme changes are present and/or clinical signs are consistent (such as cranial abdominal pain, etc.), concurrent cholangitis may be contributing to this patient's weight loss, in which case empirical therapies include fluid support (to maintain adequate hydration), broad-spectrum antibiotics, as well as hepatic nutraceuticals, including Ursodiol, if possible and if tolerated.

Otherwise, supportive/symptomatic management of the gastrointestinal signs is recommended with antiemetics, gastroprotectants, and appetite stimulant, with transition to either a novel or hydrolyzed protein diet or potentially a bland, easy to digest diet, or even a low-fat diet, based on trial and error response.





The information and recommendations provided are based on the images presented by the referring veterinarian/sonographer. No evaluation can be communicated regarding pathology that was not visible in the image/video clips provided.

Thank you for this referral. If the clinical or image interpretation does not parallel your findings or if I can be of any further assistance please contact me.

Beth Johnson, DVM, DACVIM
Beth.Johnson@sonopath.com