



<b>PATIENT</b>	<b>PRESENTING CLINICAL SIGNS</b>
Cammie Probst	History: Recent history of hypokalemia and lethargy at home. Has responded to oral K+ supplementation, values have normalized. Previous U/S has shown possible abnormality in region of right adrenal gland, gland not clearly visualized. Recheck scan today to check for progression of abnormalities in region, identify right adrenal
<b>SPECIES</b>	Abnormal PE/Chem/CBC/UA Results: Recent b/w WNL on oral K+ supplementation Hx heart disease - mild mitral valve insufficiency, left ventricular hypertrophy - asymptomatic
Feline	
<b>BREED</b>	<b>ULTRASONOGRAPHIC EXAMINATION OF THE ABDOMEN</b>
Domestic Shorthair	<i>Urinary System</i>
<b>SEX</b>	Urinary bladder is adequately distended with anechoic contents. No masses, inflammatory changes, echogenic sediment or cystoliths are observed. The urinary bladder, trigone and visible pelvic urethra are normal in thickness with a smooth mucosal surface.
Spayed female	
<b>AGE</b>	Kidneys are overall normal in size and shape with smooth peripheral margination. A normal 1:3 cortex to medulla ratio is maintained. The medulla and cortices are uniform in texture with some mild increased cortical echogenicity and mild loss of corticomedullary distinction, expected in this age patient. There is no evidence of pyelectasia, mineral or infarcts observed. The left kidney measured 3.6 cm and the right kidney measured 3.47 cm.
13 years	
<b>WEIGHT</b>	<i>Adrenal Glands</i>
13 lbs	Left adrenal gland is normal in size (0.42 cm), shape and overall architecture, echogenicity and echotexture. Visible surrounding vasculature appears normal.
<b>INTERPRETED BY</b>	Right adrenal gland is definitively visualized separately from what was previously believed to be an adrenal gland, which was an enlarged mesenteric lymph node that was also visualized in these images. The left adrenal gland is normal in size (0.47-0.5 cm with two different measurements), shape and overall architecture, echogenicity and echotexture. Visible surrounding vasculature appears normal.
Beth Johnson, DVM DACVIM	
<b>IMAGING PERFORMED BY</b>	<i>Spleen</i>
Dr. Reese	Spleen is subjectively normal in size with a normal smooth capsular contour. Parenchyma is appropriately finely textured and homogenous with normal echogenicity relative to surrounding tissue (hyperechoic to liver). No focal nodules or masses are observed. Splenic vasculature appears normal.
<b>HOSPITAL NAME</b>	
Willow Run VC	
<b>REFERRING VET</b>	<i>Liver</i>
Dr. Reese	Liver is subjectively normal in size with normal smooth curvilinear peripheral contour. Parenchyma is appropriately hypoechoic to the spleen in echogenicity and appropriately mildly coarse and homogenous in echotexture. No focal lesions are observed. Visible vasculature and biliary tree appear normal without distension or congestion.
<b>INVOICE</b>	Gallbladder is non-distended in size. The wall is smooth without visible thickening. Luminal contents are primarily anechoic. There is no evidence of cystic or common bile duct dilation.
32403	
<b>DATE</b>	
8/18/22	



<b>PATIENT</b>	<b><i>Gastrointestinal</i></b>
Camie Probst	The visible stomach wall is normal in thickness and layering. The lumen of the stomach is empty with no evidence of obstruction, foreign material or infiltrative disease. Pyloric outflow tract appears patent.
<b>SPECIES</b>	The visible small intestine demonstrates areas of thick muscularis layer relative to mucosa (disruption of the normal 1:3 muscularis:mucosa ratio). Small intestinal submucosa is slightly irregular, thick and hyperechoic, without evident loss of layering appreciated. The lumen of the small intestine is empty with no evidence of obstruction or foreign material.
Feline	
<b>BREED</b>	The visible colon is normal in wall thickness (< 0.2 cm) and layering. Contents are consistent with normal formed feces and gas.
Domestic Shorthair	
<b>SEX</b>	<b><i>Pancreas</i></b>
Spayed female	The observed pancreas appears appropriately isoechoic to surrounding omental fat. Visible capsule is smooth and normal in contour. Visible pancreatic parenchyma is homogenous and unremarkable. There is no visible pancreatic duct dilation. There is no evidence of active peripancreatic inflammation.
<b>AGE</b>	
13 years	<b><i>Free Abdomen</i></b>
<b>WEIGHT</b>	There is no evidence of free peritoneal effusion noted in these images.
13 lbs	The mesenteric lymph nodes are prominent in size with swollen capsular contour. Normal elongated shape (length to width ratio) is maintained. There is no loss of parenchymal detail.
<b>INTERPRETED BY</b>	<b>ULTRASONOGRAPHIC FINDINGS</b>
Beth Johnson, DVM DACVIM	<b>Primary Findings</b>
<b>IMAGING PERFORMED BY</b>	<ul style="list-style-type: none"> <li>• <b>Inflammatory bowel disease (IBD) pattern</b> – Thick muscularis has been reported with infiltrative bowel disease including both benign inflammatory disease as well as infiltrative neoplasia such as lymphoma. No aggressive lymphadenopathy, loss of layering, etc. is noted to make lymphoma more probable, but lymphoma cannot be definitively ruled out without tissue sampling.</li> <li>• <b>Reactive lymph nodes</b> – Lymph node(s) is(are) prominent in size with swollen capsular contour. Normal elongated shape (length to width ratio) is maintained. There is no loss of parenchymal detail.</li> </ul>
Dr. Reese	<b>Secondary Findings</b>
<b>HOSPITAL NAME</b>	<ul style="list-style-type: none"> <li>• <b>Age related renal changes.</b></li> <li>• Both <b>adrenal glands</b> are normal in size and appearance.</li> </ul>
Willow Run VC	
<b>REFERRING VET</b>	
Dr. Reese	
<b>INVOICE</b>	<b><u>INTERPRETATION OF THE FINDINGS &amp; FURTHER RECOMMENDATIONS</u></b>
32403	Given the patient's lack of adrenomegaly an aldosterone producing tumor causing the hypertension and hypokalemia is no longer believed to be a differential. The previously suspected adrenomegaly appears in these images to be a mildly enlarged, reactive mesenteric lymph node. The mild reactive mesenteric
<b>DATE</b>	
8/18/22	



**PATIENT**

Cammie Probst

**SPECIES**

Feline

**BREED**

Domestic Shorthair

**SEX**

Spayed female

**AGE**

13 years

**WEIGHT**

13 lbs

**INTERPRETED BY**

Beth Johnson, DVM  
DACVIM

**IMAGING PERFORMED BY**

Dr. Reese

**HOSPITAL NAME**

Willow Run VC

**REFERRING VET**

Dr. Reese

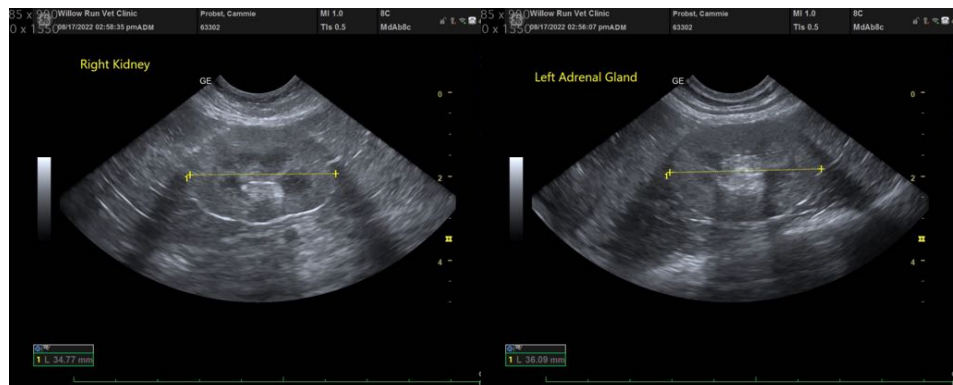
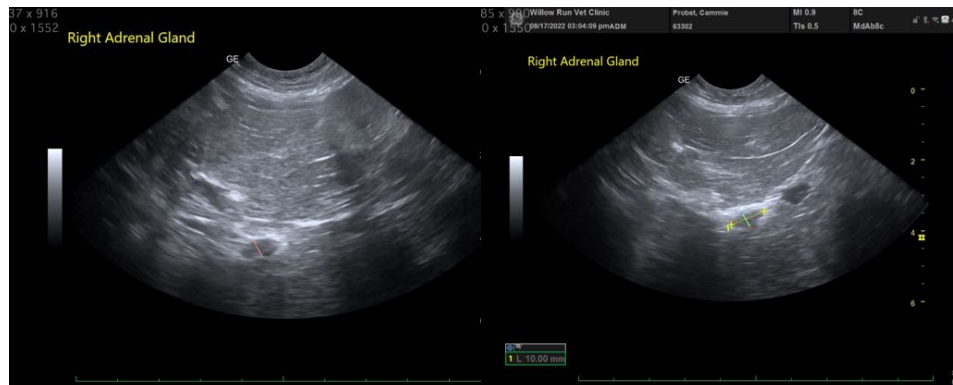
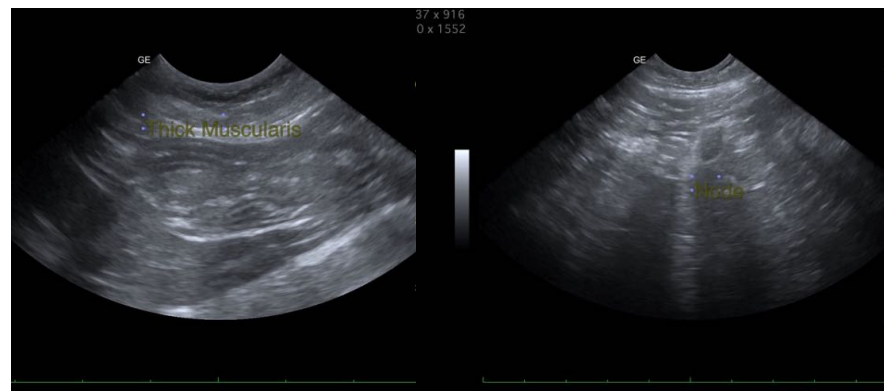
**INVOICE**

32403

**DATE**

8/18/22

lymphadenopathy combined with the mild bowel changes could suggest an underlying infiltrative/inflammatory bowel disease; however, with lack of supporting clinical signs such as weight loss, diarrhea, vomiting, decreased appetite, etc. Monitoring for now is a reasonable approach given that the primary presenting complaint was to recheck the adrenal gland. Having said that further investigation for possible malabsorptive condition potentially helping to contribute to the hyperkalemia in the first place could be considered with a gastrointestinal malabsorption panel (including cobalamin, folate, TLI and PLI) to Texas A&M GI Laboratory is recommended for further evaluation of GI and pancreatic function.





**PATIENT**

Cammie Probst

**SPECIES**

Feline

**BREED**

Domestic Shorthair

**SEX**

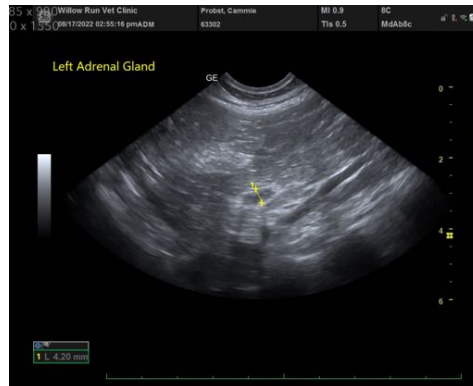Spayed female

**AGE**

13 years

**WEIGHT**

13 lbs



The information and recommendations provided are based on the images presented by the referring veterinarian/sonographer. No evaluation can be communicated regarding pathology that was not visible in the image/video clips provided.

Thank you for this referral. If the clinical or image interpretation does not parallel your findings or if I can be of any further assistance please contact me.

**Beth Johnson, DVM DACVIM**

Beth.Johnson@SonoPath.com

**INTERPRETED BY**

Beth Johnson, DVM  
DACVIM

**IMAGING PERFORMED BY**

Dr. Reese

**HOSPITAL NAME**

Willow Run VC

**REFERRING VET**

Dr. Reese

**INVOICE**

32403

**DATE**

8/18/22