



PATIENT PRESENTING CLINICAL SIGNS

Penny Sowko Weight loss since May. Intermittent inappetence with large bowel diarrhea.
Abnormal PE/Chem/CBC/UA Results: USG of 1.012, pH >9. ALP = 392

SPECIES ULTRASONOGRAPHIC EXAMINATION OF THE ABDOMEN

Canine **Urinary System**

BREED The urinary bladder is moderately distended with anechoic contents. No masses, inflammatory changes, echogenic sediment or cystoliths are observed. The urinary bladder, trigone and visible pelvic urethra are normal in thickness with a smooth mucosal surface.

Lab X

SEX The right kidney is normal in size (7.93 cm), shape and echogenicity. It has smooth peripheral margination. There is a normal 1:3 cortex to medulla ratio with appropriate corticomedullary distinction. There is no evidence of pyelectasia, mineral or infarcts observed. A subtle hyperechoic band parallel to the corticomedullary border is present.

Spayed Female

AGE The left kidney is normal in size (6.78 cm), shape and echogenicity. It has smooth peripheral margination. There is a normal 1:3 cortex to medulla ratio with appropriate corticomedullary distinction. There is no evidence of pyelectasia, mineral or infarcts observed. A subtle hyperechoic band parallel to the corticomedullary border is present.

11 Years

WEIGHT **Adrenal Glands**

72.5 Pounds

Only one pole of the right adrenal gland is well visualized with normal appearance and measures 0.50 cm thick. The other pole is difficult to fully evaluate in these images.

INTERPRETED BY

Beth Johnson, DVM
DACVIM

The left adrenal gland is normal in size (0.48 cm at the cranial pole and 0.71 cm at the caudal pole), shape and contour. Corticomedullary structure is unremarkable. Visible surrounding vasculature appears normal.

IMAGING PERFORMED BY **Spleen**

Dr. Brandon Holmes

Spleen is subjectively normal in size with a normal smooth capsular contour. Parenchyma is appropriately finely textured and homogenous with normal echogenicity relative to surrounding tissue (hyperechoic to liver). Multifocal well-demarcated hyperechoic homogenous nodules are noted. Splenic vasculature appears normal.

HOSPITAL NAME

West Newton AC

Liver

REFERRING VET

Dr. Brandon Holmes

Liver is relatively normal in size and contour. Parenchyma is mildly heterogenous and coarse with mild likely age-related parenchymal remodeling noted. No focal lesions are observed. Visible vasculature and biliary tree appear normal without distension or congestion.

INVOICE

44757

Gallbladder is non-distended in size. The wall is smooth without visible thickening. Luminal contents are primarily anechoic with some echogenic debris noted. There is no evidence of cystic or common bile duct dilation.

DATE

8/17/23

Gastrointestinal

The stomach wall is normal in thickness (canine < 0.5 cm and feline < 0.4 cm) and layering. The lumen of the stomach is empty with no evidence of obstruction, foreign material or infiltrative disease. Pyloric outflow tract appears patent.



PATIENT

Penny Sowko

The visible small intestines are normal in wall thickness and layering (canine duodenum < 0.5 cm and feline duodenum < 0.4 cm; other < 0.3 cm). Small intestinal motility appears adequate (1-3 contractions per min). The lumen of the small intestine is empty with no evidence of obstruction, foreign material or infiltrative disease.

SPECIES

Canine

The visible colon is normal in wall thickness (< 0.2 cm) and layering. Contents are consistent with normal formed feces and gas.

BREED

Lab X

Pancreas

The pancreatic parenchyma is appropriately isoechoic to surrounding tissue. Visible capsule is smooth and normal in contour. There is no visible pancreatic duct dilation. There is no evidence of active peripancreatic inflammation.

SEX

Spayed Female

Free Abdomen

There is no evidence of free peritoneal effusion noted in these images.

AGE

11 Years

There is no apparent lymphadenopathy noted in these images.

ULTRASONOGRAPHIC FINDINGS

WEIGHT

72.5 Pounds

- **Subtle bilateral medullary rim sign** - This finding is of unknown clinical significance and can be a normal variant, often idiopathic. Medullary rim sign can be present with renal disease including FIP, lymphoma, hypercalcemic nephropathy, Leptospirosis, tubular disease, other and should be interpreted in combination with other more specific indications of kidney disease such as isosthenuria, proteinuria, azotemia, etc. This is a common incidental finding in patients with diabetes mellitus.
- **Hyperechoic splenic nodules** – most consistent with benign myelolipomas. Other differentials such as fibrosis or calcification caused by old hematomas or infarcts, chronic inflammation, granulomatous disease or metastatic disease cannot be ruled out, but are considered less likely.
- Otherwise, this is a relatively unremarkable abdomen with expected age related changes.

INTERPRETED BY

Beth Johnson, DVM
DACVIM

IMAGING PERFORMED BY

Dr. Brandon Holmes

INTERPRETATION OF THE FINDINGS & FURTHER RECOMMENDATIONS

HOSPITAL NAME

West Newton AC

Given the subtle medullary rim sign combined with this patient's reported weight loss, and if not recently evaluated, ruling out diabetes mellitus is recommended.

REFERRING VET

Dr. Brandon Holmes

A gastrointestinal malabsorption panel (including cobalamin, folate, TLI and PLI) to Texas A&M GI Laboratory is recommended for further evaluation of GI and pancreatic function.

INVOICE

44757

A baseline cortisol is recommended. If baseline cortisol is less than 2, a full ACTH stimulation test is recommended to rule out hypoadrenocorticism.

DATE

8/17/23

A fecal enteropathogen PCR panel to Texas A&M GI Laboratory could be considered for further evaluation of possible infectious disease.

In the meantime, supportive/symptomatic medical management of clinical signs is recommended, including a probiotic (such as visbiome or proviable), empirical deworming with a 5-day course of Panacur and, if tolerated, a transition in diet, based on trial-and-error response, beginning with a



PATIENT

hydrolyzed protein diet. Some patients respond to one brand/version of a hydrolyzed protein diet better than another brand, so several attempts may be required.

Penny Sowko

SPECIES

Ultimately, if clinical signs persist, and a diagnosis is not reached, further evaluation of the GI tract via upper and lower endoscopy for visualization and biopsies may be warranted.

Canine

BREED

Lab X

SEX

Spayed Female

AGE

11 Years

WEIGHT

72.5 Pounds

INTERPRETED BY

Beth Johnson, DVM
DACVIM

IMAGING PERFORMED BY

Dr. Brandon Holmes

HOSPITAL NAME

West Newton AC

REFERRING VET

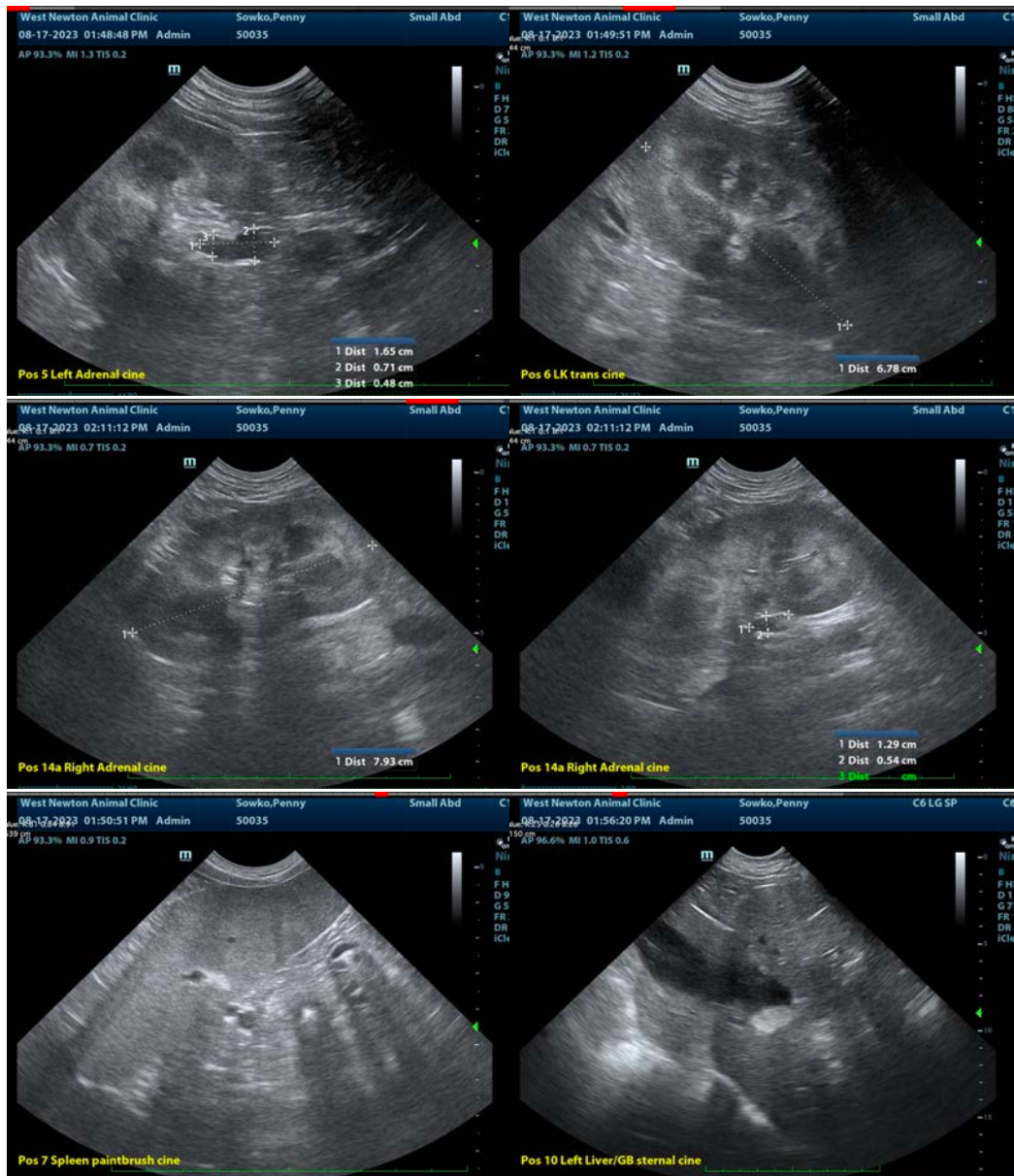
Dr. Brandon Holmes

INVOICE

44757

DATE

8/17/23





PATIENT

Penny Sowko

The information and recommendations provided are based on the images presented by the referring veterinarian/sonographer. No evaluation can be communicated regarding pathology that was not visible in the image/video clips provided.

SPECIES

Canine

Thank you for this referral. If the clinical or image interpretation does not parallel your findings or if I can be of any further assistance please contact me.

BREED

Lab X

Beth Johnson, DVM, DACVIM
info@sonopath.com

SEX

Spayed Female

AGE

11 Years

WEIGHT

72.5 Pounds

INTERPRETED BY

Beth Johnson, DVM
DACVIM

**IMAGING
PERFORMED BY**

Dr. Brandon Holmes

HOSPITAL NAME

West Newton AC

REFERRING VET

Dr. Brandon Holmes

INVOICE

44757

DATE

8/17/23