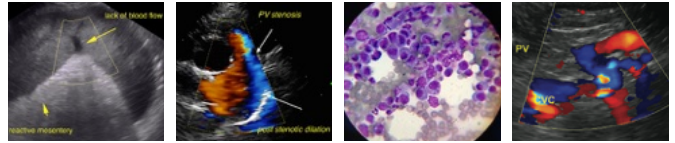


PATIENT	PRESENTING CLINICAL SIGNS
Caesar Von Essen	Acute Vomiting/Diarrhea x 3 days.
SPECIES	Abnormal PE/Chem/CBC/UA Results: ALT 311, ALKP 708
Canine	ULTRASONOGRAPHIC EXAMINATION OF THE ABDOMEN
BREED	Urinary System
Mixed	The urinary bladder is moderately distended with anechoic contents. No masses, inflammatory changes, echogenic sediment or cystoliths are observed. The urinary bladder, trigone and visible pelvic urethra are normal in thickness with a smooth mucosal surface.
SEX	The prostate is unable to be well visualized in these images.
Neutered Male	Kidneys are overall normal in size and shape with smooth peripheral margination. A normal 1:3 cortex to medulla ratio is maintained. The medulla and cortices are uniform in texture with some mild increased cortical echogenicity and mild loss of corticomedullary distinction, expected in this age patient. There is no evidence of pyelectasia, mineral or infarcts observed. The left kidney measures 5.04 cm. The right kidney measures 4.91 cm.
AGE	Adrenal Glands
WEIGHT	The right adrenal gland is normal in size (0.62 cm at the caudal pole, the cranial pole is difficult to fully visualize in these images), shape and contour. Corticomedullary structure is unremarkable. Visible surrounding vasculature appears normal.
24.6 lbs	The area of the left adrenal gland examined without evident adrenal gland pathology.
INTERPRETED BY	Spleen
Beth Johnson, DVM DACVIM	The spleen is subjectively normal in size with a normal smooth capsular contour. Parenchyma is appropriately finely textured and homogenous with normal echogenicity relative to surrounding tissue (hyperechoic to liver). No focal nodules or masses are observed. Splenic vasculature appears normal.
IMAGING PERFORMED BY	Liver
Dr. Travis Cerf	Liver is subjectively enlarged with mildly irregular margins. Parenchyma is heterogenous characterized by multiple poorly defined hypoechoic nodules within otherwise hyperechoic liver parenchyma. Visible vasculature and biliary tree appear normal without distension or congestion.
HOSPITAL NAME	Gallbladder is moderately distended with anechoic bile as well as suspended and gravity dependent echogenic debris. The wall is smooth without visible thickening. There is no evidence of cystic or CBD dilation. There is no evidence of effusion or inflammation.
Veterinary Center of Hardyston	Gastrointestinal
REFERRING VET	The stomach wall is normal in thickness (canine < 0.5 cm and feline < 0.4 cm) and layering. The lumen of the stomach is empty with no evidence of obstruction or foreign material. Pyloric outflow tract appears patent.
Dr. Travis Cerf	The visible small intestines are normal in wall thickness and layering (canine duodenum < 0.5 cm and feline duodenum < 0.4 cm; other < 0.3 cm). Small intestinal motility appears adequate (1-3 contractions per min). The lumen of the small intestine is mildly distended with echogenic non-shadowing luminal contents and gas consistent with normal ingesta. There is no evidence of obstruction or foreign material noted.
INVOICE	
10427	
DATE	
8/17/2023	



PATIENT

Caesar Von Essen

The visible colon is normal in wall thickness (< 0.2 cm) and layering. Contents are consistent with normal formed feces and gas.

SPECIES

Canine

Pancreas

The pancreatic parenchyma is appropriately isoechoic to surrounding tissue. Visible capsule is smooth and normal in contour. There is no visible pancreatic duct dilation. There is no evidence of active peripancreatic inflammation.

BREED

Mixed

Free Abdomen

There is no evidence of free peritoneal effusion noted in these images.

SEX

Neutered Male

There is no apparent lymphadenopathy noted in these images.

AGE

ULTRASONOGRAPHIC FINDINGS

WEIGHT

24.6 lbs

- **Heterogenous Liver** – These changes are most consistent with benign processes such as nodular hyperplasia, steroid (vacuolar) hepatopathy, extramedullary hematopoiesis or possibly chronic inflammatory disease and less commonly infiltrative round cell or metastatic neoplasia.
- **Moderate gallbladder debris** - Cholecystic debris is of unknown clinical significance. It can be seen with biliary stasis from fasting or illness. Cholecystic debris is not necessarily related to hepatobiliary disease. Echogenic bile is most commonly an incidental finding in dogs and should be interpreted in combination with clinical signs such as nausea, inappetence, cranial abdominal discomfort and/or laboratory changes such as increased ALP and/or increased Tbili.

INTERPRETED BY

Beth Johnson, DVM
DACVIM

SECONDARY FINDINGS

- Age related kidneys

IMAGING PERFORMED BY

Dr. Travis Cerf

INTERPRETATION OF THE FINDINGS & FURTHER RECOMMENDATIONS

HOSPITAL NAME

Veterinary Center of
Hardyston

Recommendations include “antigen search” for sources of reactive hepatopathy (including testing for leptospirosis). Additionally, a fine needle aspirate of the liver could be consider if patients coagulation status is appropriate.

REFERRING VET

Dr. Travis Cerf

In the meantime, in addition to supportive/symptomatic medical management of the gastrointestinal signs in the form of antiemetics, gastroprotectants, and appetite stimulant, if necessary, a probiotic such as Visbiome or Provable, +/- empirical deworming with a 5-day course of Panacur, hepatic nutraceuticals i.e., Ursodiol given the gallbladder debris and broad spectrum antibiotics are recommended with monitoring of clinical signs, liver enzymes, etc. for improvement. If gastrointestinal signs persist next diagnostic considerations could include:

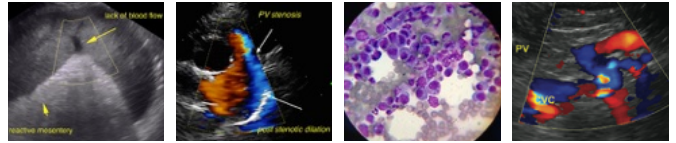
INVOICE

10427

DATE

8/17/2023

- A baseline cortisol is recommended. If baseline cortisol is less than 2, a full ACTH stimulation test is recommended to rule out hypoadrenocorticism.
- A gastrointestinal malabsorption panel (including cobalamin, folate, TLI and PLI) to Texas A&M GI Laboratory is recommended for further evaluation of GI and pancreatic function.



PATIENT

Caesar Von Essen

SPECIES

Canine

BREED

Mixed

SEX

Neutered Male

AGE

WEIGHT

24.6 lbs

INTERPRETED BY

Beth Johnson, DVM
DACVIM

IMAGING PERFORMED BY

Dr. Travis Cerf

HOSPITAL NAME

Veterinary Center of
Hardyston

REFERRING VET

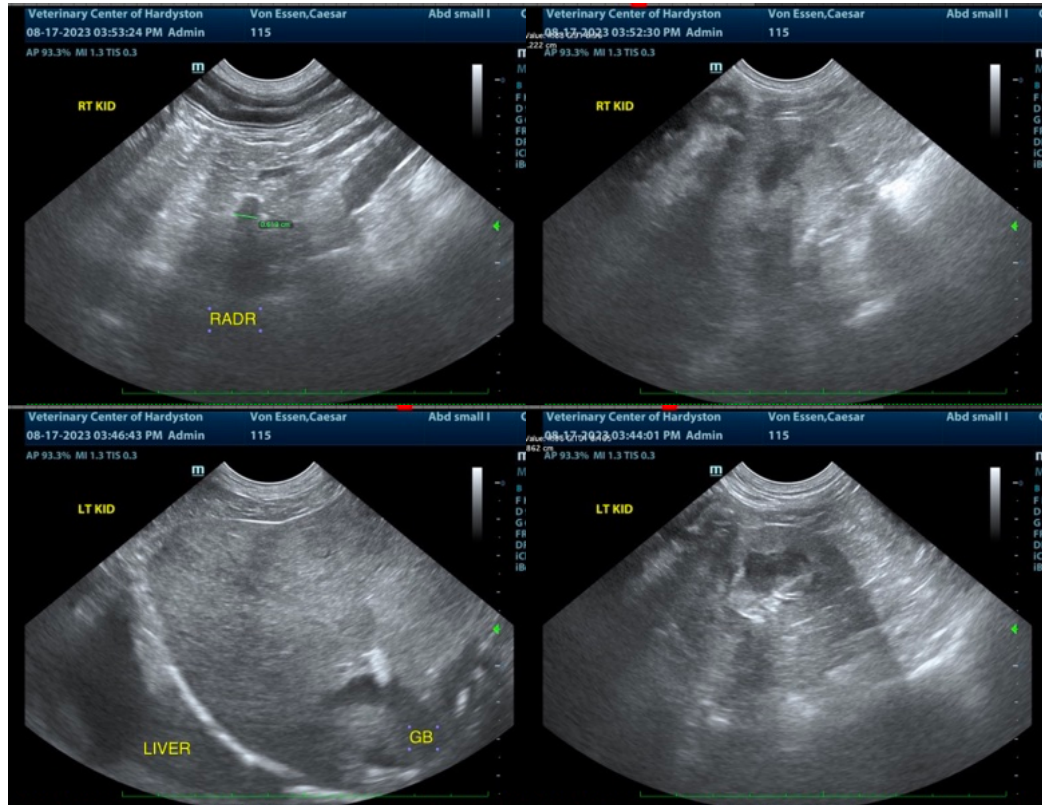
Dr. Travis Cerf

INVOICE

10427

DATE

8/17/2023



The information and recommendations provided are based on the images presented by the referring veterinarian/sonographer. No evaluation can be communicated regarding pathology that was not visible in the image/video clips provided.

Thank you for this referral. If the clinical or image interpretation does not parallel your findings or if I can be of any further assistance, please contact me.

Beth Johnson, DVM, DACVIM
info@sonopath.com