

**DATE PRESENTING CLINICAL SIGNS**

8/16/23 New chronic kidney disease.

**PATIENT** Current Medications: None listed.  
Date of Previous IntraPet Ultrasound: No previous.  
Iggly Keller Sedation: IV Torb.  
Stat Report: Not requested.  
**SPECIES** Imaging Performed By: Rachel Brillhart, RDMS.

Canine

**ULTRASONOGRAPHIC EXAMINATION OF THE ABDOMEN****BREED** *Urinary System*

Airedale Terrier

The urinary bladder is moderately distended with anechoic contents. No masses, inflammatory changes, echogenic sediment or cystoliths are observed. The urinary bladder, trigone and visible pelvic urethra are normal in thickness with a smooth mucosal surface.

**SEX**

Spayed Female

The right kidney is normal in size (6.95 cm), shape and echogenicity. It has smooth peripheral margination. There is a normal 1:3 cortex to medulla ratio with appropriate corticomedullary distinction. There is no evidence of pyelectasia, mineral or infarcts observed.

**AGE**

12/30/14

The left kidney is normal in size (7.77 cm), shape and echogenicity. It has smooth peripheral margination. There is a normal 1:3 cortex to medulla ratio with appropriate corticomedullary distinction. There is no evidence of mineral or infarcts observed. Trace pyelectasia noted.

**WEIGHT**

21.77 kg

**Adrenal Glands****INTERPRETED BY**Beth Johnson, DVM  
DACVIM

The right adrenal gland is normal in size (1.8 cm at the cranial pole and 0.49 cm at the caudal pole), shape and contour. A hyperechoic nodule is noted in the cranial pole. Nodule does not disrupt normal shape and/or architecture. Visible surrounding vasculature appears normal.

The left adrenal gland is normal in size (0.77 cm at the cranial pole and 0.76 cm at the caudal pole), shape and contour. Corticomedullary structure is unremarkable. Visible surrounding vasculature appears normal.

**HOSPITAL NAME**

Banfield Towson

**Spleen****REFERRING VET**

Dr. Washington

Spleen is subjectively large in size with a swollen and scalloped/undulating capsular contour. Multifocal coalescing nodules are noted throughout the parenchyma. Specifically, an approximately 2.0 cm homogeneous, hypoechoic nodule resulting in a bulge mid spleen is noted, as well as an approximately 4.0 cm homogeneous, hypoechoic nodule/mass resulting in a bulge near the tail of the spleen. Splenic vasculature appears normal. Enhanced hyperechoic surrounding fat is noted.

**INVOICE**

44723

**Liver**

Liver is subjectively enlarged (swollen contour). Mild parenchymal remodeling with diffusely mildly coarse architecture and increased portal markings is present. No focal nodules or masses are observed. Visible vasculature and biliary tree appear normal without distension or congestion.

The gallbladder is non-distended in size. The wall is smooth without visible thickening. Luminal contents are primarily anechoic. There is no evidence of cystic or common bile duct dilation.

### ***Gastrointestinal***

The stomach wall is normal in thickness (canine < 0.5 cm and feline < 0.4 cm) and layering. The lumen of the stomach is empty with no evidence of obstruction, foreign material or infiltrative disease. Pyloric outflow tract appears patent.

The visible small intestines are normal in wall thickness and layering (canine duodenum < 0.5 cm and feline duodenum < 0.4 cm; other < 0.3 cm). Small intestinal motility appears adequate (1-3 contractions per min). The lumen of the small intestine is empty with no evidence of obstruction, foreign material or infiltrative disease.

The visible colon is normal in wall thickness (< 0.2 cm) and layering. Contents are consistent with normal formed feces and gas.

### ***Pancreas***

The pancreatic parenchyma is appropriately isoechoic to surrounding tissue. Visible capsule is smooth and normal in contour. There is no visible pancreatic duct dilation. There is no evidence of active peripancreatic inflammation.

### ***Free Abdomen***

There is no evidence of free peritoneal effusion noted in these images.

There is no apparent lymphadenopathy noted in these images.

## **ULTRASONOGRAPHIC FINDINGS**

- **Honeycomb Spleen** – This finding is strongly suggestive of infiltrative disease such as round cell neoplasia. Benign disease cannot be ruled out but is considered less likely.
- **Hypoechoic hepatomegaly** – This appearance is consistent with an acute hepatopathy or acute cholangiohepatitis. Infiltrative neoplasia (round cell neoplasia) should also be considered.
- **Trace left kidney pyelectasia** – Differentials for pyelectasia include pyelonephritis, diuresis, congenital malformation or ureteral or lower urinary tract obstruction.
- **Hyperechoic adrenal nodule cranial pole right adrenal gland** – Differentials include primary adrenal cortical adenoma or adenocarcinoma, pheochromocytoma, myelolipoma, adrenal hyperplasia secondary to pituitary disease or metastatic disease. Ultrasound alone cannot differentiate between functional and non-functional nodules and/or between benign and malignant disease. Small nodules without other evidence of abdominal disease (to suggest metastatic disease) and/or clinical signs (to suggest adrenal disease) are most often incidental and should be monitored.

## **INTERPRETATION OF THE FINDINGS & FURTHER RECOMMENDATIONS**

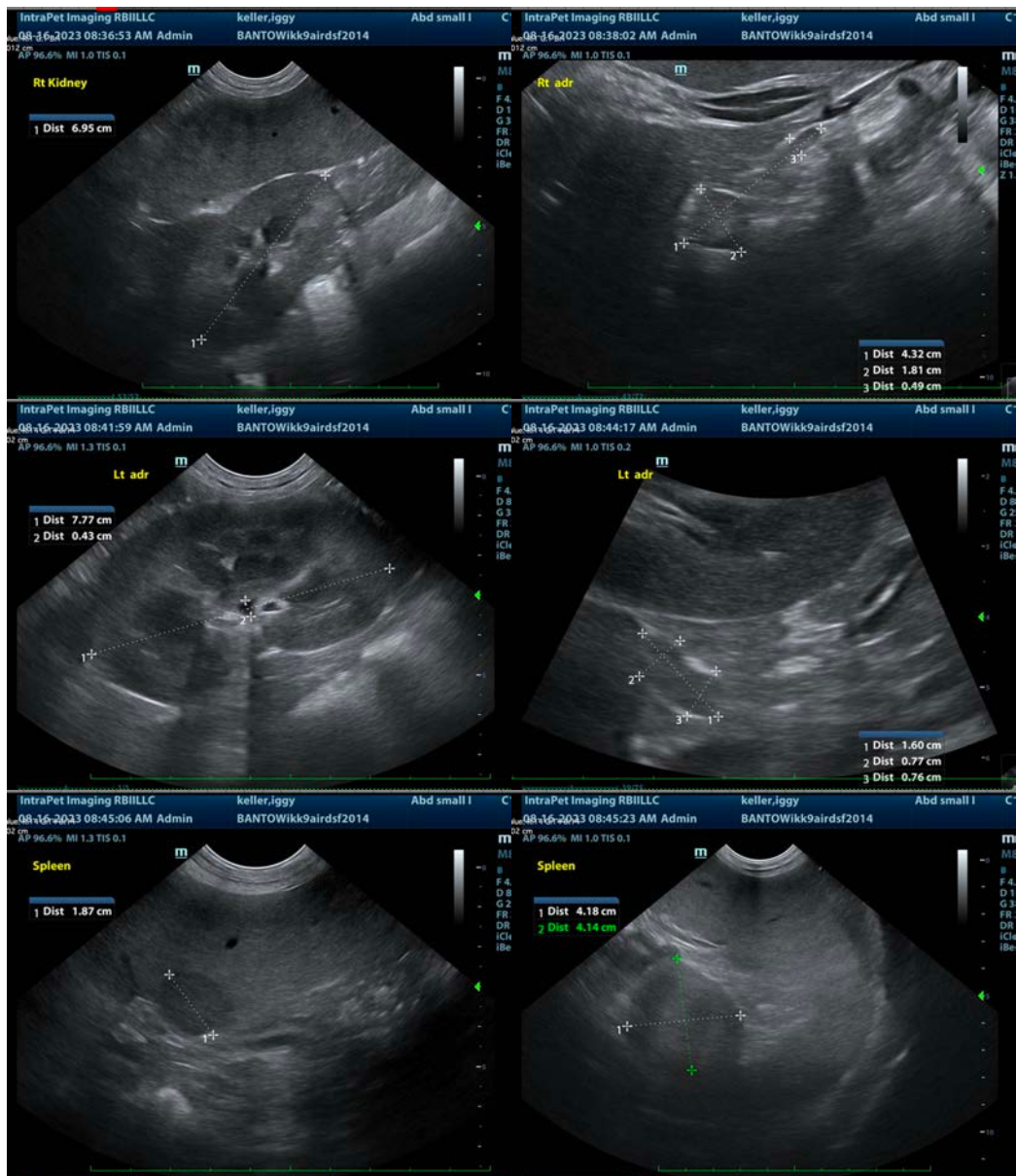
Recommendations for this patient depend in part on specific laboratory values as well as patient's clinical status. Having said that, given the reported new chronic kidney disease, if not recently evaluated, a urinalysis and, if indicated based on urinalysis results, urine culture are recommended. If protein is present in an otherwise quiet sediment, protein quantification with a urine protein to creatinine ratio is recommended.

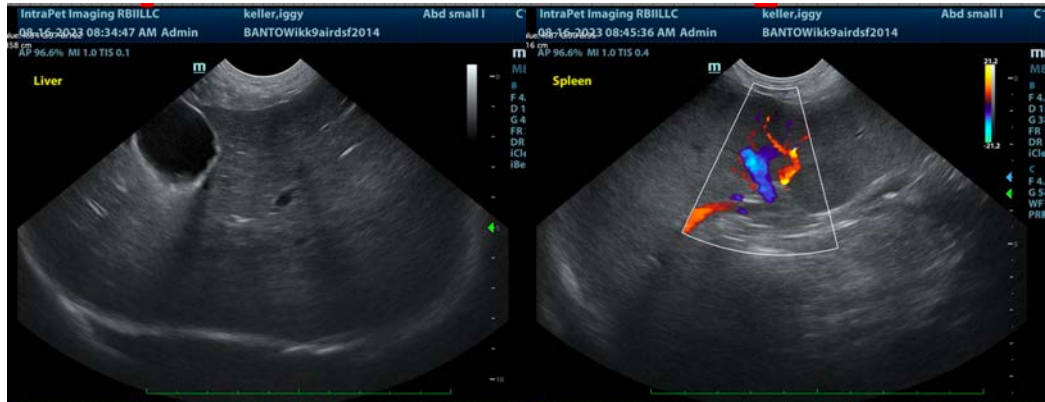
Blood pressure is recommended if not recently evaluated.

Testing for Leptospirosis could be considered.

Having said that, however, the most concerning pathology in this patient is not the kidneys but the spleen and liver, and further investigation is recommended, beginning with fine needle aspirate of the spleen and liver if patient's coagulation status is appropriate.

Three view thoracic radiographs are recommended for further assessment of cardio-pulmonary status as well as to further evaluate for any evidence of metastatic disease, if not recently evaluated.





The information and recommendations provided are based on the images presented by the referring veterinarian/sonographer. No evaluation can be communicated regarding pathology that was not visible in the image/video clips provided.

Thank you for this referral. If the clinical or image interpretation does not parallel your findings or if I can be of any further assistance please contact me.

**Beth Johnson, DVM, DACVIM**  
info@sonopath.com