



**PATIENT PRESENTING CLINICAL SIGNS**

Louie Hammack

Vomiting/regurgitation/diarrhea intermittently for 6 weeks, not daily but several times per week. Sometimes undigested kibble. Appetite is somewhat reduced when fed, but will ravenously eat later in the day. Does not ever seem to vomit treats. Current diet is Beyond Superfood Blend. Had some areas of hair loss on face and topline but new growth is present after switching food.

**SPECIES**

Canine

Abnormal PE/Chem/CBC/UA Results: Lab results 8/12/22 - CBC - moderate thrombocytosis Chem - Ca 8.1, Alb 1.6, Glob 2.2, AST 89, CK 652 UA - USG 1.039, pH 7.5, trace proteinuria Recently ruptured left CCL, BP normal (systolic just about 150, but patient panting and anxious in hospital). Left hind limb lameness, dental disease with possible crown fractures of 108/208. No pain on abdominal palpation. Feces are malodorous.

**BREED**

Labrador Retriever

**SEX**

Neutered Male

**ULTRASONOGRAPHIC EXAMINATION OF THE ABDOMEN**

**Urinary System**

Urinary bladder is adequately distended with primarily anechoic contents and occasional echogenic non-shadowing debris. Apical urinary bladder wall is diffusely thick. Mucosa is hyperechoic and irregular. No masses or cystoliths are observed. The trigone and visible pelvic urethra are normal thickness with a smooth mucosal surface.

**AGE**

10 Years

The area of the prostate is examined without evident pathology.

**WEIGHT**

31.5 kg

The right kidney is normal in size (7.7 cm), shape and echogenicity. It has smooth peripheral margination. There is a normal 1:3 cortex to medulla ratio with appropriate corticomedullary distinction. There is no evidence of pyelectasia, mineral or infarcts observed.

**INTERPRETED BY**

Beth Johnson, DVM  
DACVIM

The left kidney is normal in size (6.5 cm), shape and echogenicity. It has smooth peripheral margination. There is a normal 1:3 cortex to medulla ratio with appropriate corticomedullary distinction. There is no evidence of pyelectasia, mineral or infarcts observed.

**Adrenal Glands**

**IMAGING PERFORMED BY**

Jolee Stegemoller

The right adrenal gland is normal in size (1.9 cm long x 0.42 cm at the cranial pole and 0.55 cm at the caudal pole), shape and contour. Corticomedullary structure is unremarkable. Visible surrounding vasculature appears normal.

**HOSPITAL NAME**

North Idaho AH

The left adrenal gland is normal in size (3.4 cm long x 0.60 cm at the cranial pole and 0.85 cm at the caudal pole), shape and contour. Corticomedullary structure is unremarkable. Visible surrounding vasculature appears normal.

**Spleen**

**REFERRING VET**

Dr. Jeffrey Poulsen

The spleen is subjectively normal in size with a normal smooth capsular contour. Parenchyma is appropriately finely textured and homogenous with normal echogenicity relative to surrounding tissue (hyperechoic to liver). No focal nodules or masses are observed. Splenic vasculature appears normal.

**Liver**

**INVOICE**

40523

The liver is subjectively normal in size with normal smooth curvilinear peripheral contour. Parenchyma is appropriately hypoechoic to the spleen in echogenicity and appropriately mildly coarse and homogenous in echotexture. A 2.5 cm x 3.0 cm focal discrete, hyperechoic, homogeneous nodule/mass is noted in the mid caudal liver. Visible vasculature and biliary tree appear normal without distension or congestion.

**DATE**

8/16/22



**PATIENT**

Louie Hammack

The gallbladder is non-distended in size. The wall is smooth without visible thickening. Luminal contents are primarily anechoic. There is no evidence of cystic or common bile duct dilation.

**Gastrointestinal**

**SPECIES**

Canine

The visible stomach wall is normal in thickness and layering. The lumen of the stomach is mildly distended with echogenic non-shadowing luminal contents and gas consistent with normal ingesta. There is no evidence of obstruction, foreign material or infiltrative disease. Pyloric outflow tract appears patent.

**BREED**

Labrador Retriever

The visible small intestines are normal in wall thickness and layering (canine duodenum < 0.5 cm and feline duodenum < 0.4 cm; other < 0.3 cm). Small intestinal motility appears adequate (1-3 contractions per min). The lumen of the small intestine is empty with no evidence of obstruction, foreign material or infiltrative disease.

**SEX**

Neutered Male

The visible colon is normal in wall thickness (< 0.2 cm) and layering. Contents are consistent with normal formed feces and gas.

**Pancreas**

**AGE**

10 Years

The pancreatic parenchyma is appropriately isoechoic to surrounding tissue. Visible capsule is smooth and normal in contour. There is no visible pancreatic duct dilation. There is no evidence of active peripancreatic inflammation.

**WEIGHT**

31.5 kg

**Free Abdomen**

There is no evidence of free peritoneal effusion noted in these images.

**INTERPRETED BY**

Beth Johnson, DVM  
DACVIM

The medial iliac lymph nodes are prominent in size with swollen capsular contour. Normal elongated shape (length to width ratio) is maintained. There is no loss of parenchymal detail.

**PRIMARY FINDINGS**

- **Liver nodule** – Differentials for a discrete liver nodule include primarily benign changes such as nodular hyperplasia, fibrosis of an old hematoma, granuloma, etc.; however, while considered less likely, primary hepatic neoplasia, infiltrative round cell neoplasia and metastatic disease can mimic benign lesions and cannot be definitively ruled out.

**IMAGING PERFORMED BY**

Jolee Stegemoller

**SECONDARY FINDINGS**

**HOSPITAL NAME**

North Idaho AH

- **Chronic Cystitis** - Urinary bladder wall changes are most consistent with chronic cystitis. Infiltrative neoplasia cannot be ruled out but is considered less likely give the location and diffuse nature of the changes.

**REFERRING VET**

Dr. Jeffrey Poulsen

- **Reactive medial iliac lymph nodes** – infiltrative neoplastic disease cannot be ruled out but is considered less likely.

**INTERPRETATION OF THE FINDINGS & FURTHER RECOMMENDATIONS**

**INVOICE**

40523

There is no definitive ultrasonographic evidence of gastrointestinal disease/protein losing enteropathy. However, given this patient's history and laboratory changes, a protein losing enteropathy is suspected and can be present without supporting ultrasonographic changes.

**DATE**

8/16/22

A gastrointestinal malabsorption panel (including cobalamin, folate, TLI and PLI) to Texas A&M GI Laboratory is recommended for further evaluation of GI and pancreatic function.



**PATIENT**

Louie Hammack

Three view thoracic radiographs are recommended for further assessment of cardio-pulmonary status as well as to further evaluate for any evidence of metastatic disease, if not recently evaluated.

**SPECIES**

Canine

A fine needle aspirate of the liver nodule could be considered if patient's coagulation status is appropriate. However, the appearance of the nodule trends towards a benign lesion. Therefore, monitoring is a reasonable, more conservative approach with recheck ultrasound of the nodule in 6-8 weeks.

**BREED**

Labrador Retriever

**SEX**

Neutered Male

**AGE**

10 Years

**WEIGHT**

31.5 kg

**INTERPRETED BY**

Beth Johnson, DVM  
DACVIM

**IMAGING PERFORMED BY**

Jolee Stegemoller

**HOSPITAL NAME**

North Idaho AH

**REFERRING VET**

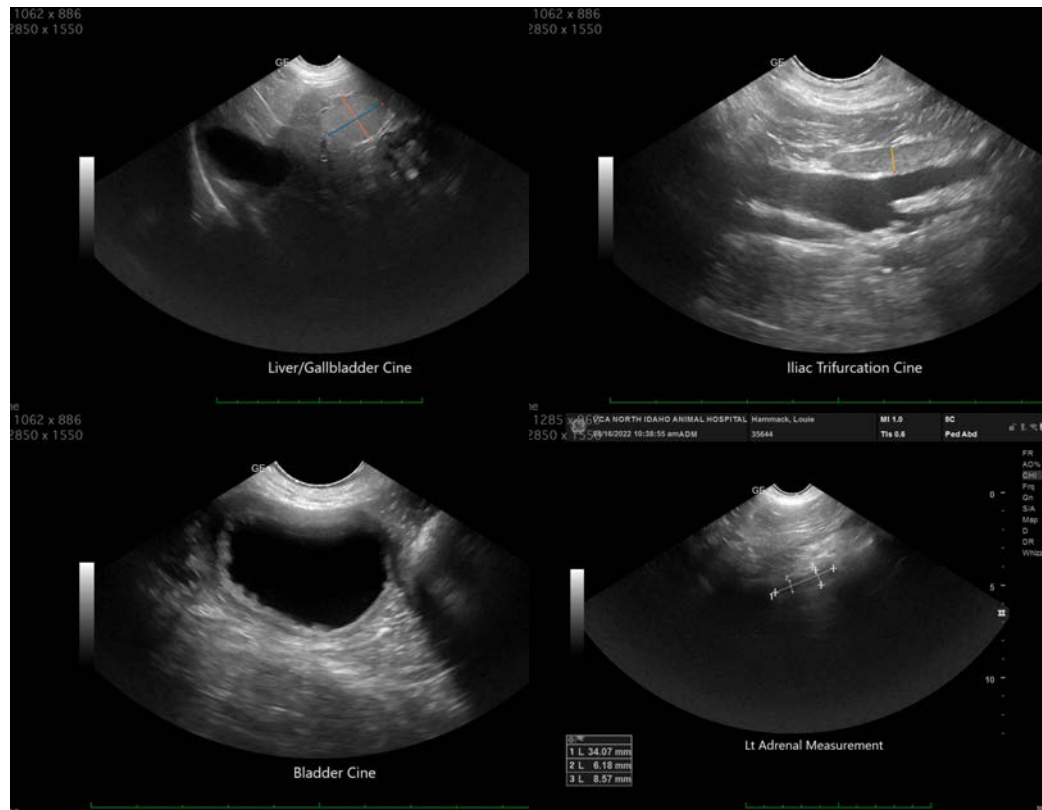
Dr. Jeffrey Poulsen

**INVOICE**

40523

**DATE**

8/16/22





**PATIENT**

Louie Hammack

**SPECIES**

Canine

**BREED**

Labrador Retriever

**SEX**

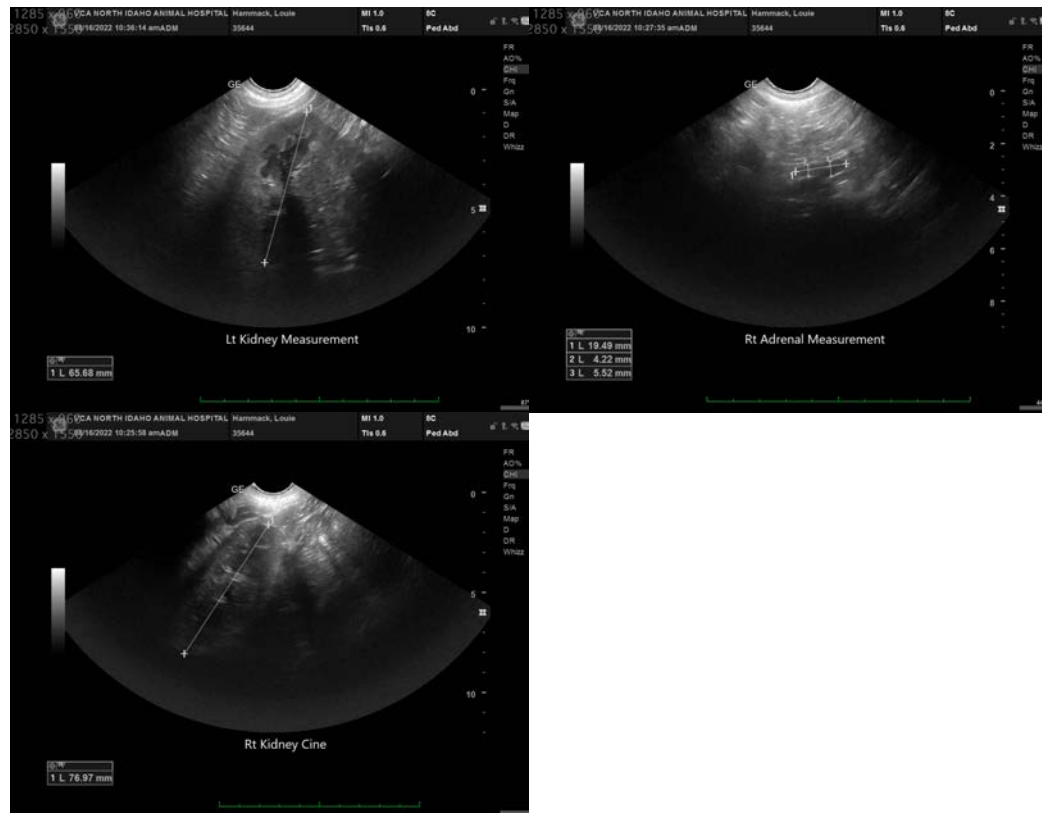
Neutered Male

**AGE**

10 Years

**WEIGHT**

31.5 kg



**INTERPRETED BY**

Beth Johnson, DVM  
DACVIM

**IMAGING PERFORMED BY**

Jolee Stegemoller

**HOSPITAL NAME**

North Idaho AH

**REFERRING VET**

Dr. Jeffrey Poulsen

**INVOICE**

40523

**DATE**

8/16/22

The information and recommendations provided are based on the images presented by the referring veterinarian/sonographer. No evaluation can be communicated regarding pathology that was not visible in the image/video clips provided.

Thank you for this referral. If the clinical or image interpretation does not parallel your findings or if I can be of any further assistance please contact me.

**Beth Johnson, DVM, DACVIM**  
Beth.Johnson@sonopath.com