



**PATIENT**

Jack Noyd

**SPECIES**

Feline

**BREED**

DSH

**SEX**

Neutered Male

**AGE**

16 Years 5 Months

**WEIGHT**

14.5 Pounds

**INTERPRETED BY**

Beth Johnson, DVM  
DACVIM

**IMAGING PERFORMED BY**

Denise Bruno, LVT,  
RDMS

**HOSPITAL NAME**

Brooklyn Heights VH

**REFERRING VET**

Dr. Thomson

**INVOICE**

40521

**DATE**

8/16/22

**PRESENTING CLINICAL SIGNS**

Decreased appetite, dullness, inappropriate urination. Hx IBD, hx of heart murmur (3/6) Last AUS done 12/13/2017 (IBD/GI pattern w/pancreatitis + mild hepatic remodeling. Current Meds: Prednisolone 5mg, Gabapentin 25mg Bid/Tid Labs, Radiographs and previous AUS attached. Evaluate for masses/lymphoma.

**ULTRASONOGRAPHIC EXAMINATION OF THE ABDOMEN**

**Urinary System**

Urinary bladder is adequately distended. It has a normal uniform wall thickness. Contents include primarily anechoic fluid with occasional echogenic non-shadowing debris, most consistent with incidental suspended lipid in a cat, possibly combined with exfoliated cells, mucous and/or small blood clots. Both sterile inflammation as well as urinary tract infection can also present with echogenic debris. No masses or cystoliths are observed. The trigone and visible pelvic urethra are normal in thickness with a smooth mucosal surface.

Kidneys are overall normal in size and shape with smooth peripheral margination. A normal 1:3 cortex to medulla ratio is maintained. The medulla and cortices are uniform in texture with some mild increased cortical echogenicity and mild loss of corticomedullary distinction, expected in this age patient. There is no evidence of pyelectasia, mineral or infarcts observed. The left kidney measured 3.93 cm. The right kidney measured 4.22 cm. A cortical cyst is noted in both kidneys.

**Adrenal Glands**

The right adrenal gland is normal in size (0.57 cm), shape and contour. Corticomedullary structure is unremarkable. Visible surrounding vasculature appears normal.

The left adrenal gland is normal in size (0.31 cm), shape and contour. Corticomedullary structure is unremarkable. Visible surrounding vasculature appears normal.

**Spleen**

The spleen is subjectively normal in size with a normal smooth capsular contour. Parenchyma is appropriately finely textured and homogenous with normal echogenicity relative to surrounding tissue (hyperechoic to liver). No focal nodules or masses are observed. Splenic vasculature appears normal.

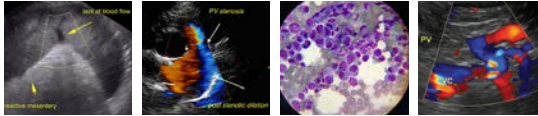
**Liver**

Liver is subjectively enlarged (swollen contour) without disruption of architecture. It has a normal homogenous echotexture. Parenchyma is diffusely hyperechoic characterized by less prominent than normal portal vein walls and increased echogenicity relative to the spleen and falciform fat. No focal lesions are observed. Visible vasculature and biliary tree appear normal without distension or congestion.

The gallbladder is non-distended in size. The wall is smooth without visible thickening. Luminal contents are primarily anechoic. There is no evidence of cystic or common bile duct dilation.

**Gastrointestinal**

The stomach wall is normal in thickness (canine < 0.5 cm and feline < 0.4 cm) and layering. The lumen of the stomach is empty with no evidence of obstruction, foreign material or infiltrative disease. Pyloric outflow tract appears patent.



**PATIENT**

Jack Noyd

**SPECIES**

Feline

**BREED**

DSH

**SEX**

Neutered Male

**AGE**

16 Years 5 Months

**WEIGHT**

14.5 Pounds

**INTERPRETED BY**

Beth Johnson, DVM  
DACVIM

**IMAGING PERFORMED BY**

Denise Bruno, LVT,  
RDMS

**HOSPITAL NAME**

Brooklyn Heights VH

**REFERRING VET**

Dr. Thomson

**INVOICE**

40521

**DATE**

8/16/22

The visible small intestines are normal in wall thickness and layering (canine duodenum < 0.5 cm and feline duodenum < 0.4 cm; other < 0.3 cm), except for a focal loop of small bowel that is mildly thick (upper limit of normal thickness) and has some “fuzzy” emerging loss of layering suspected. Small intestinal motility appears adequate (1-3 contractions per min). The lumen of the small intestine is empty with no evidence of obstruction, foreign material or infiltrative disease.

The visible colon is normal in wall thickness (< 0.2 cm) and layering. Contents are consistent with normal formed feces and gas.

***Pancreas***

Pancreas is prominent (enlarged) in size, hypoechoic to surrounding tissue and has a mildly irregular undulating contour. Parenchyma is coarse with mixed echogenic remodeling noted. Pancreatic duct dilation is noted.

***Free Abdomen***

There is no evidence of free peritoneal effusion noted in these images.

There is no apparent lymphadenopathy noted in these images.

**PRIMARY FINDINGS**

- One focal small bowel loop has some “fuzzy” emerging loss of layering suspected. The remaining small bowel appears more normal. However, more aggressive changes could be being masked by Prednisone. The loss of layering despite the administration of Prednisone is concerning for infiltrative neoplasia such as lymphoma. Benign inflammatory disease can't be ruled out, but is considered less likely.

- **Hyperechoic hepatomegaly** – This appearance is most consistent with benign hepatic lipidosis. Infiltrative disease such as amyloidosis or round cell neoplasia, such as mast cell tumor or less likely, lymphoma, is also possible.

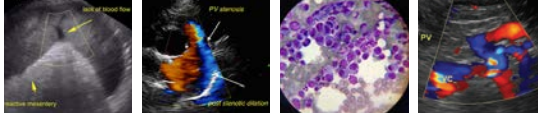
- Chronic active pancreatitis suspected

**SECONDARY FINDINGS**

- Urinary bladder debris
- Age related kidney changes with bilateral cortical cysts

**INTERPRETATION OF THE FINDINGS & FURTHER RECOMMENDATIONS**

Based on these images, there is some concern for infiltrative neoplasia such as lymphoma. However, tissue is required to say definitively. Therefore, options include either biopsies of the GI tract, being sure to locate potentially with intraoperative ultrasound, etc. the focal loss of layering described, or, if biopsies are not possible, and clinical signs are not controlled with the current dose of Prednisone, the dose of Prednisone could be increased and/or additional medication such as Chlorambucil could be considered if there are no contraindications to doing so. If not recently evaluated, a gastrointestinal malabsorption panel (including cobalamin, folate, TLI and PLI) to Texas A&M GI Laboratory is recommended for further evaluation of GI and pancreatic function.



**PATIENT**

Jack Noyd

Urinalysis and, if indicated based on urinalysis results, urine culture are recommended. If protein is present in an otherwise quiet sediment, protein quantification with a urine protein to creatinine ration is recommended.

**SPECIES**

Feline

Given this patient's inappropriate mental dullness, other differentials for decreased appetite, etc. include an underlying neurologic condition versus gastrointestinal, and therefore further neurologic evaluation may be warranted as well.

**BREED**

DSH

**SEX**

Neutered Male

**AGE**

16 Years 5 Months

**WEIGHT**

14.5 Pounds

**INTERPRETED BY**

Beth Johnson, DVM  
DACVIM

**IMAGING PERFORMED BY**

Denise Bruno, LVT,  
RDMS

**HOSPITAL NAME**

Brooklyn Heights VH

**REFERRING VET**

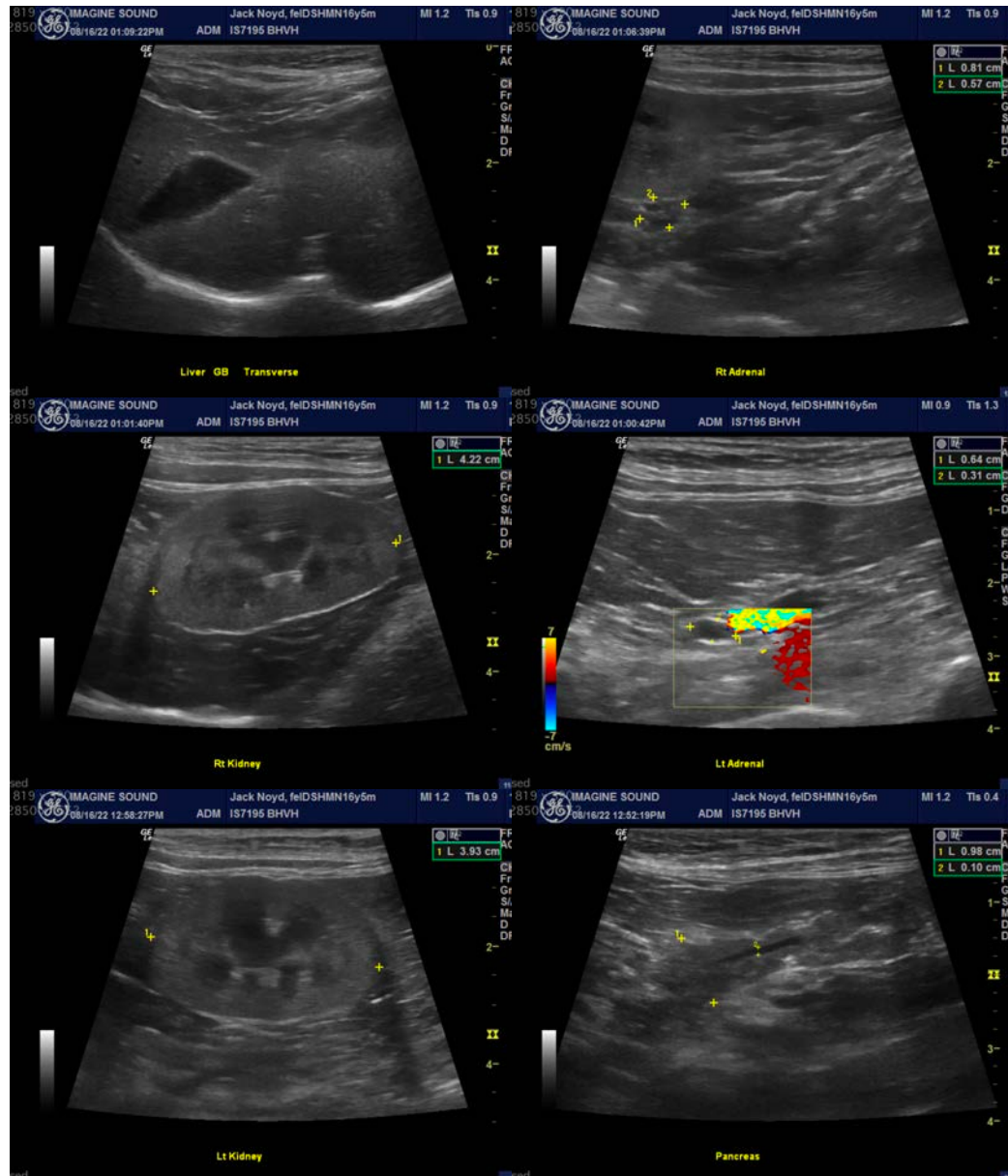
Dr. Thomson

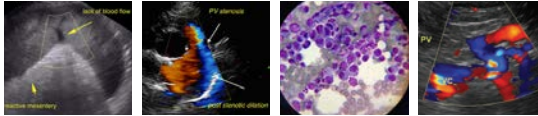
**INVOICE**

40521

**DATE**

8/16/22





**PATIENT**

Jack Noyd

**SPECIES**

Feline

**BREED**

DSH

**SEX**

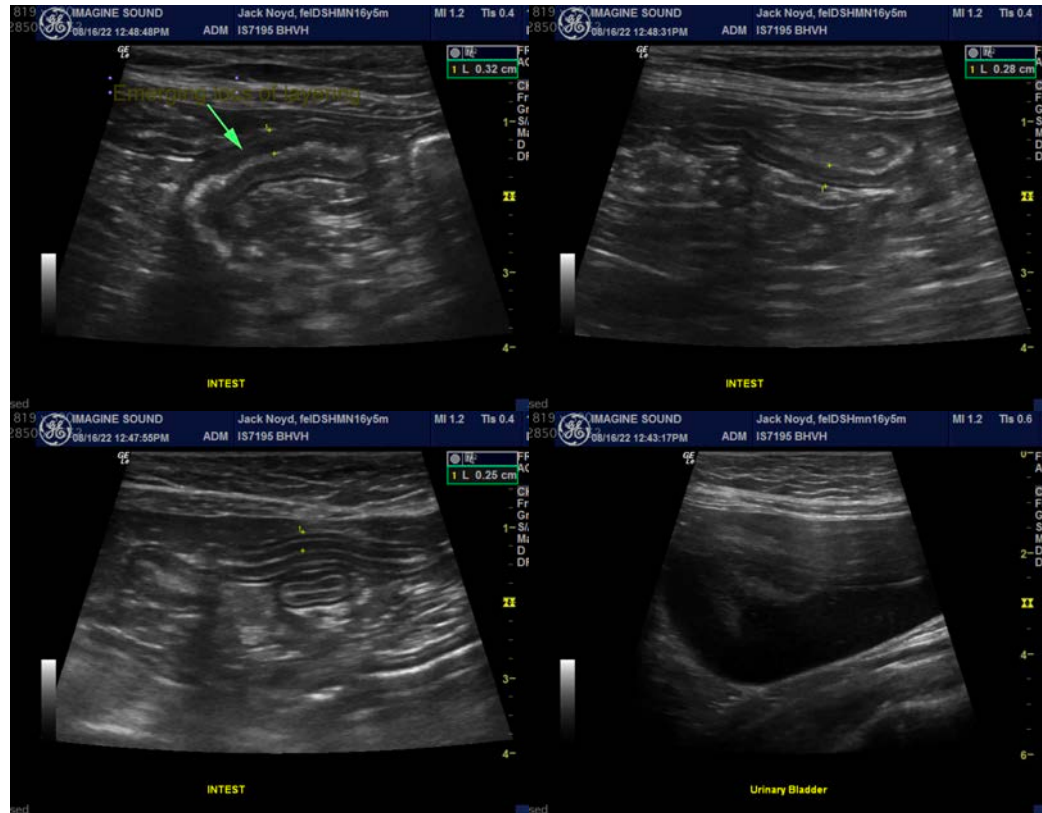
Neutered Male

**AGE**

16 Years 5 Months

**WEIGHT**

14.5 Pounds



**INTERPRETED BY**

Beth Johnson, DVM  
DACVIM

**IMAGING PERFORMED BY**

Denise Bruno, LVT,  
RDMS

**HOSPITAL NAME**

Brooklyn Heights VH

**REFERRING VET**

Dr. Thomson

**INVOICE**

40521

**DATE**

8/16/22

The information and recommendations provided are based on the images presented by the referring veterinarian/sonographer. No evaluation can be communicated regarding pathology that was not visible in the image/video clips provided.

Thank you for this referral. If the clinical or image interpretation does not parallel your findings or if I can be of any further assistance please contact me.

**Beth Johnson, DVM, DACVIM**  
Beth.Johnson@sonopath.com