

**DATE PRESENTING CLINICAL SIGNS**

8/15/23 Diabetic- dysregulation. BG curve 8/7 - all levels high (9am: 744, insulin. 11a: 481, 1pm: 378, 3pm: 337, 5p: 359) Increased insulin by 1unit. Pet went to ER this weekend for diarrhea and BG of 40 (hypoglycemia).

**PATIENT**

Bear Zimmerman

Current Medications: Vetsulin insulin (decreased back to 4u q 12 hrs.).  
Lab Results: Hyperglycemia. Will be placing free style libre on pet today.

Date of Previous IntraPet Ultrasound: No previous.

Sedation: Not required to complete full diagnostic ultrasound.

Stat Report: Not requested.

Imaging Performed By: Andi Parkinson, BS, RDMS.

**SPECIES**

Canine

**BREED**

Bichon

**SEX**

Neutered Male

**AGE**

6/24/12

**WEIGHT**

22.5 Pounds

**INTERPRETED BY**Beth Johnson, DVM  
DACVIM**ULTRASONOGRAPHIC EXAMINATION OF THE ABDOMEN****Urinary System**

Urinary bladder is adequately distended with primarily anechoic contents and occasional echogenic non-shadowing debris. Apical urinary bladder wall is diffusely thick (0.50 cm thick). Mucosa is hyperechoic and irregular. No masses or cystoliths are observed. The trigone and visible pelvic urethra are normal thickness with a smooth mucosal surface.

Prostate is normal in size, echotexture and echogenicity for a neutered male.

The right kidney is normal in size (6.39 cm), shape and echogenicity. It has smooth peripheral margination. There is a normal 1:3 cortex to medulla ratio with appropriate corticomedullary distinction. There is no evidence of pyelectasia, mineral or infarcts observed. A hyperechoic band parallel to the corticomedullary border is present.

The left kidney is normal in size (5.81 cm), shape and echogenicity. It has smooth peripheral margination. There is a normal 1:3 cortex to medulla ratio with appropriate corticomedullary distinction. There is no evidence of pyelectasia, mineral or infarcts observed. A hyperechoic band parallel to the corticomedullary border is present. Multiple small cortical cysts noted.

**HOSPITAL NAME**

Timonium AH

**Adrenal Glands**

The right adrenal gland is normal in size (0.58 cm at the cranial pole and 0.67 cm at the caudal pole), shape and contour. Corticomedullary structure is unremarkable. Visible surrounding vasculature appears normal.

**REFERRING VET**

Dr. McMichael

The left adrenal gland is normal in size (0.48 cm at the cranial pole and 0.67 cm at the caudal pole), shape and contour. Corticomedullary structure is unremarkable. Visible surrounding vasculature appears normal.

**Spleen**

The spleen is subjectively normal in size with a normal smooth capsular contour. Parenchyma is appropriately finely textured and homogenous with normal echogenicity relative to surrounding tissue (hyperechoic to liver). At the head of the spleen, resulting in a mild capsular bulge, there is a 2.1 cm x 2.3 cm homogeneous, hypoechoic nodule/mass. Splenic vasculature appears normal.

**INVOICE**

44669

**Liver**

Liver is subjectively enlarged (swollen contour) without disruption of architecture. It has a normal homogenous echotexture. Parenchyma is diffusely hyperechoic characterized by less prominent than normal portal vein walls and increased echogenicity relative to the spleen and falciform fat. A 0.60 cm x 0.80 cm discrete homogeneous hyperechoic nodule is noted in the caudal liver. Visible vasculature and biliary tree appear normal without distension or congestion.

Gallbladder is moderately distended with anechoic bile as well as suspended and gravity dependent echogenic debris. The wall is smooth without visible thickening. There is no evidence of cystic or CBD dilation. There is no evidence of effusion or inflammation.

### ***Gastrointestinal***

The visible stomach wall is normal in thickness and layering. The lumen of the stomach is mildly distended with echogenic non-shadowing luminal contents and gas consistent with normal ingesta. There is no evidence of obstruction, foreign material or infiltrative disease. Pyloric outflow tract appears patent.

The visible small intestines are normal in wall thickness and layering (canine duodenum < 0.5 cm and feline duodenum < 0.4 cm; other < 0.3 cm). Small intestinal motility appears adequate (1-3 contractions per min). The lumen of the small intestine is empty with no evidence of obstruction, foreign material or infiltrative disease.

The visible colon is normal in wall thickness (< 0.2 cm) and layering. Contents are consistent with normal formed feces and gas.

### ***Pancreas***

The observed pancreas appears appropriately isoechoic to surrounding omental fat. The capsule is mildly irregular in shape. Parenchyma is mildly heterogenous and coarse. There is no visible pancreatic duct dilation. There is no evidence of active peripancreatic inflammation.

### ***Free Abdomen***

There is no evidence of free peritoneal effusion noted in these images.

There is no apparent lymphadenopathy noted in these images.

There is no evidence of heart base or pericardial pathology noted in these images at this time. If cardiac function evaluation is desired a full echocardiogram is recommended.

## **PRIMARY FINDINGS**

- **Splenic nodule/mass** – This could represent a benign change such as nodular hyperplasia, extramedullary hematopoiesis, etc., or infiltrative neoplasia such as round cell neoplasia versus other and cannot be differentiated definitively without tissue sampling.
- **Hyperechoic hepatomegaly** - This appearance is non-specific and most consistent with a benign steroid (endocrine) or vacuolar hepatopathy or reactive or idiopathic hepatopathy. Inflammatory and/or infiltrative disease (such as round cell neoplasia) are also possible, but considered less likely.
- **Liver nodule**- Differentials for a discrete liver nodule include primarily benign changes such as nodular hyperplasia, fibrosis of an old hematoma, granuloma, myelolipoma, etc.; however, while considered less likely, primary hepatic neoplasia, infiltrative round cell neoplasia and metastatic disease can mimic benign lesions and cannot be definitively ruled out.
- **Mild gallbladder debris** - Cholecystic debris is of unknown clinical significance. It can be seen with biliary stasis from fasting or illness. Cholecystic debris is not necessarily related to hepatobiliary disease. Echogenic bile is most commonly an incidental finding in dogs and should be interpreted in combination with clinical signs such as nausea, inappetence, cranial abdominal discomfort and/or

laboratory changes such as increased ALP and/or increased Tbili.

- **Chronic Cystitis** - Urinary bladder wall changes are most consistent with chronic cystitis. Infiltrative neoplasia cannot be ruled out but is considered less likely given the location and diffuse nature of the changes.

## **SECONDARY FINDINGS**

- **Bilateral medullary rim sign** - This finding is of unknown clinical significance and can be a normal variant, often idiopathic. Medullary rim sign can be present with renal disease including FIP, lymphoma, hypercalcemic nephropathy, Leptospirosis, tubular disease, other and should be interpreted in combination with other more specific indications of kidney disease such as isosthenuria, proteinuria, azotemia, etc. This is a common incidental finding in patients with diabetes mellitus.
- **Pancreatic age-related remodeling** – Mild irregularities are consistent with benign age-related change. Low-grade smoldering chronic pancreatitis cannot be ruled out and should be suspected in the face of appropriate clinical signs.

## **INTERPRETATION OF THE FINDINGS & FURTHER RECOMMENDATIONS**

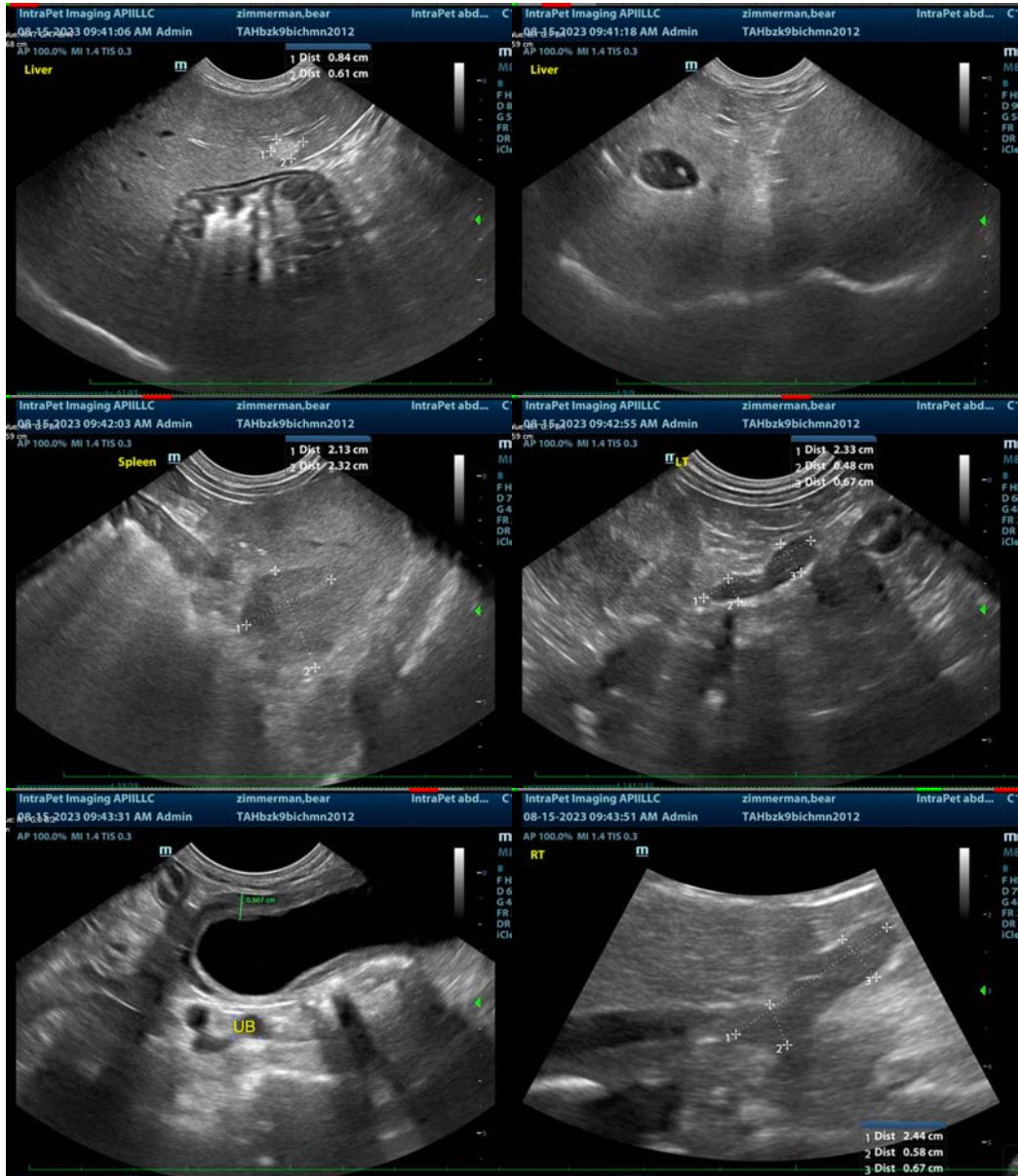
If not recently evaluated, a urinalysis and, if indicated based on urinalysis results, urine culture are recommended. If protein is present in an otherwise quiet sediment, protein quantification with a urine protein to creatinine ratio is recommended.

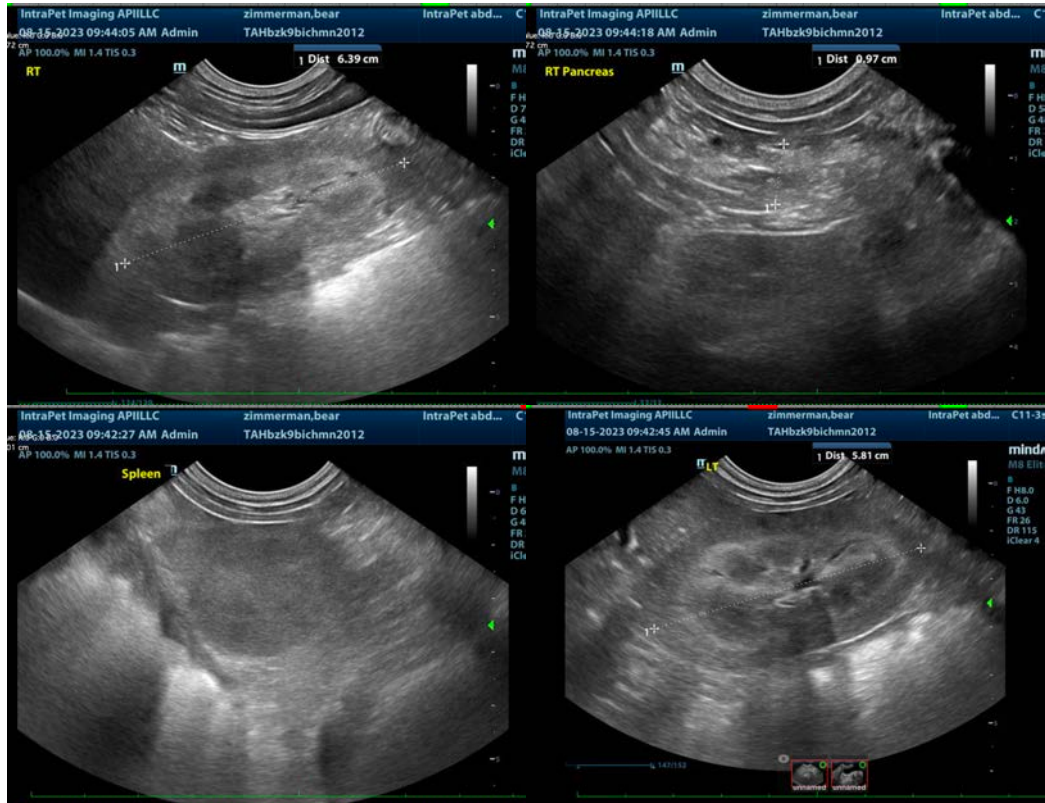
To aid in regulation of this patient's diabetes, as is reportedly already planned, placement of a freestyle libre could be considered.

Additionally, a fine needle aspirate of the splenic nodule/mass is recommended if patient's coagulation status is appropriate. If further sampling is declined, monitoring of the nodule should be planned.

Finally, while the appearance of the pancreas is most consistent with a normal benign age related change, further evaluation of pancreatic function could be considered, evaluating for both pancreatitis as well as exocrine pancreatic insufficiency, beginning with:

A gastrointestinal malabsorption panel (including cobalamin, folate, TLI and PLI) to Texas A&M GI Laboratory is recommended for further evaluation of GI and pancreatic function.





The information and recommendations provided are based on the images presented by the referring veterinarian/sonographer. No evaluation can be communicated regarding pathology that was not visible in the image/video clips provided.

Thank you for this referral. If the clinical or image interpretation does not parallel your findings or if I can be of any further assistance please contact me.

**Beth Johnson, DVM, DACVIM**  
info@sonopath.com