

**DATE PRESENTING CLINICAL SIGNS**

8/15/22 Had fb sx on July 28- removed copius amounts of foreign material removed (hair, bandana, ear wipes, packaging, beetle, and other fabric). Pt is eating and drinking but still having issues with vomiting every 2-3 days. Ate yest @4pm and vomited @ 2am.

PATIENT

Ruthie Campbell

Current Medications: finished meds from AEH- was on cerenia 60mg sid, omeprazole 20mg bid, gabapentin 300mg bid, trazadone 100mg bid, enytce 30mg sol- 2.7ml's po bid, and amoxi 500mg bid. 8/10/2022- owner sent w/ rx for Ondansetron and Prilosec - owner will not give Prilosec 48 hours prior to scan

SPECIES

Canine

Radiographs: delayed gastric emptying with increased gas pattern

Date of Previous IntraPet Ultrasound: No previous.

Sedation: Not required to complete full diagnostic ultrasound.

Stat Report: Not requested.

BREED

Labrador X

ULTRASONOGRAPHIC EXAMINATION OF THE ABDOMEN**Urinary System**

The urinary bladder is moderately distended with anechoic contents. No masses, inflammatory changes, echogenic sediment or cystoliths are observed. The urinary bladder, trigone and visible pelvic urethra are normal in thickness with a smooth mucosal surface.

SEX

Spayed Female

AGE

10/14/15

The right kidney is normal in size (5.59 cm), shape and echogenicity. It has smooth peripheral margination. There is a normal 1:3 cortex to medulla ratio with appropriate corticomedullary distinction. There is no evidence of pyelectasia, mineral or infarcts observed.

WEIGHT

53 Pounds

The left kidney is normal in size (6.07 cm), shape and echogenicity. It has smooth peripheral margination. There is a normal 1:3 cortex to medulla ratio with appropriate corticomedullary distinction. There is no evidence of pyelectasia, mineral or infarcts observed.

INTERPRETED BYBeth Johnson, DVM
DACVIM**Adrenal Glands**

The right adrenal gland is normal in size (2.7 cm long x 0.80 cm at the cranial pole and 0.96 cm at the caudal pole), shape and contour. Corticomedullary structure is unremarkable. Visible surrounding vasculature appears normal.

IMAGING PERFORMED BY

Rachel Brillhart RDMS

The left adrenal gland is normal in size (2.9 cm long x 0.65 cm at the cranial pole and 0.77 cm at the caudal pole), shape and contour. Corticomedullary structure is unremarkable. Visible surrounding vasculature appears normal.

HOSPITAL NAME

Animal Care Center

Spleen

The spleen is subjectively normal in size with a normal smooth capsular contour. Parenchyma is appropriately finely textured and homogenous with normal echogenicity relative to surrounding tissue (hyperechoic to liver). No focal nodules or masses are observed. Splenic vasculature appears normal.

REFERRING VET

Dr. Beavers

Liver

The liver is subjectively normal in size with normal smooth curvilinear peripheral contour. Parenchyma is appropriately hypoechoic to the spleen in echogenicity and appropriately mildly coarse and homogenous in echotexture. No focal lesions are observed. Visible vasculature and biliary tree appear normal without distension or congestion.

INVOICE

40475

The gallbladder is non-distended in size. The wall is smooth without visible thickening. Luminal contents are primarily anechoic. There is no evidence of cystic or common bile duct dilation.

Gastrointestinal

The visible stomach wall is normal in thickness (canine < 0.5 cm and feline < 0.4 cm) and layering. The stomach is not overly distended. However, it does contain an echogenic interface with distal progressively shadowing material, consistent with hairball density or similar fluid absorbing material. Normal gas and ingesta cannot be definitively ruled out. There is no evidence of infiltrative disease in the gastric wall or pyloric area to help explain delayed gastric emptying.

The visible small intestines are normal in wall thickness and layering (canine duodenum < 0.5 cm and feline duodenum < 0.4 cm; other < 0.3 cm). Small intestinal motility appears adequate (1-3 contractions per min). The lumen of the small intestine is empty with no evidence of obstruction, foreign material or infiltrative disease.

The visible colon is normal in wall thickness (< 0.2 cm) and layering. Contents are consistent with normal formed feces and gas.

Pancreas

The pancreatic parenchyma is appropriately isoechoic to surrounding tissue. Visible capsule is smooth and normal in contour. There is no visible pancreatic duct dilation. There is no evidence of active peripancreatic inflammation.

Free Abdomen

There is no evidence of free peritoneal effusion noted in these images.

There is no apparent lymphadenopathy noted in these images.

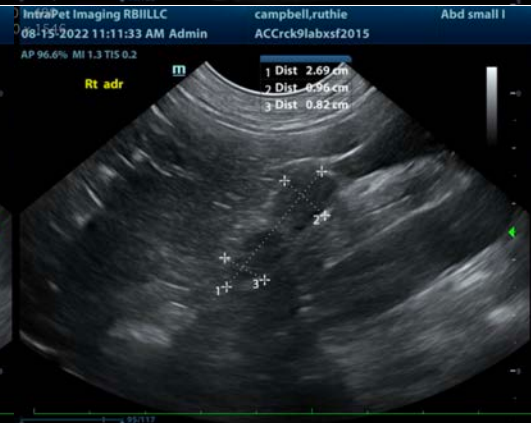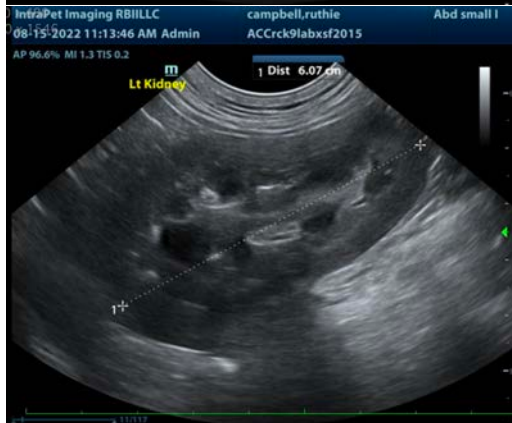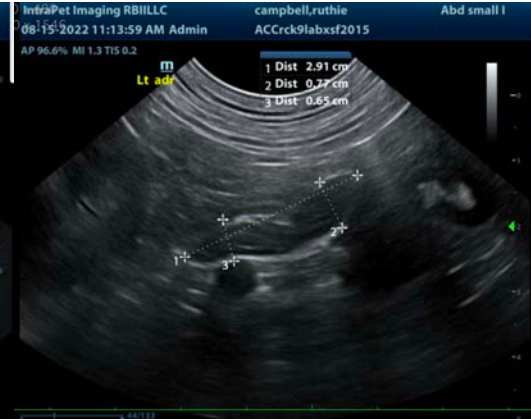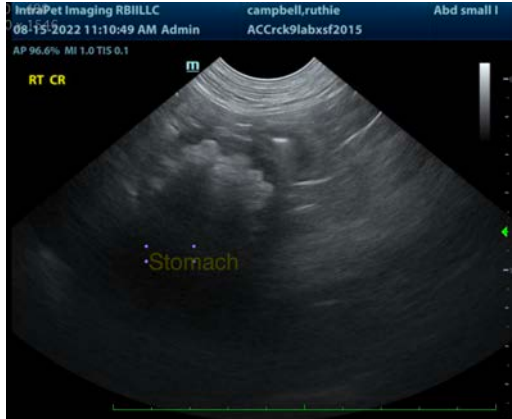ULTRASONOGRAPHIC FINDINGS

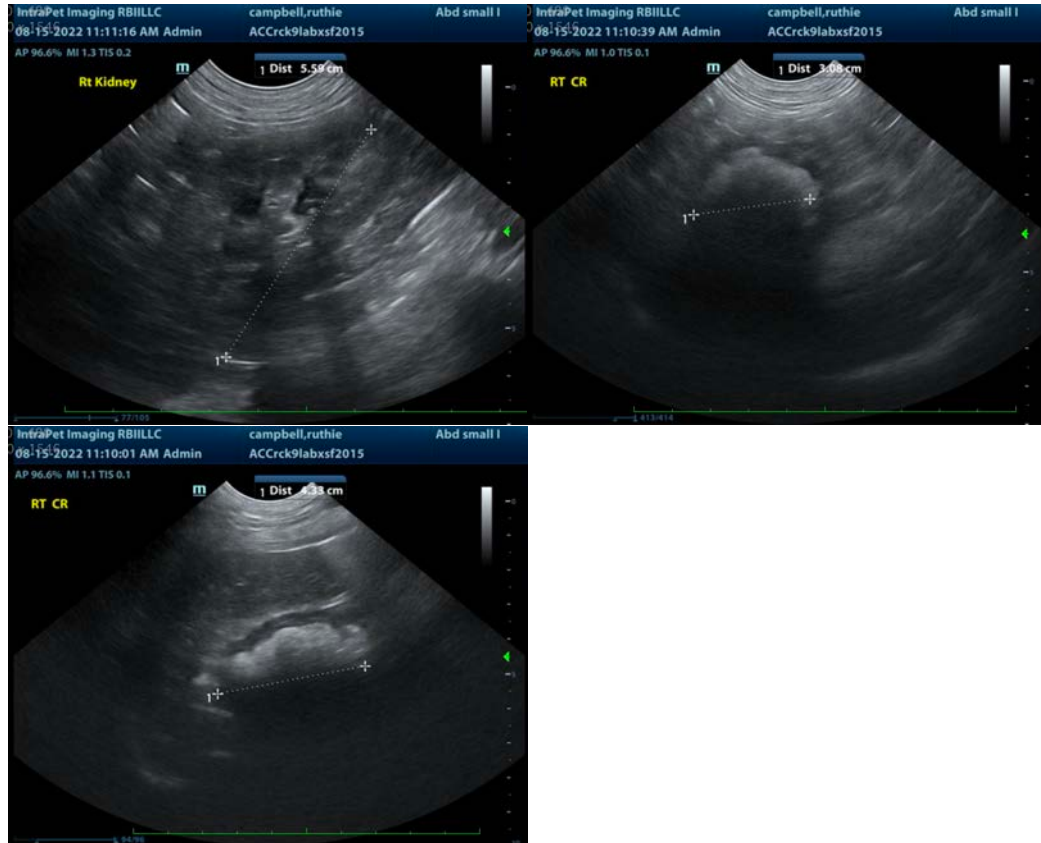
- Gastric contents with acoustic shadow – concerning for foreign material such as hair or other fluid absorbing soft foreign material. However, given this patient's history and recent foreign body removal, normal ingesta and gas, etc. can't be ruled out.

INTERPRETATION OF THE FINDINGS & FURTHER RECOMMENDATIONS

Unfortunately, the appearance of these images is concerning for more foreign material present in this dog's stomach again. However, given the recent exploratory and foreign body removal, delayed healing and post-op inflammation, gastritis, ileus, etc. could just potentially be resulting in delayed gastric emptying of normal ingesta and gas. Therefore, options include providing supportive/symptomatic medical management of this patient with fluids, gastroprotectants, antiemetics, and fasting for another 24 hours and reimaging the abdomen to see if the stomach has emptied, versus a barium swallow or potentially gastroscopy for further visualization of possible gastric foreign material, versus the most aggressive option, which would be re-exploring this patient.

Medical management and fasting for another 24 hours with recheck imaging, given the lack of gastric distention or obstruction pattern, is considered the reasonable approach, understanding the small risk of foreign material migration into the small bowel.





The information and recommendations provided are based on the images presented by the referring veterinarian/sonographer. No evaluation can be communicated regarding pathology that was not visible in the image/video clips provided.

Thank you for this referral. If the clinical or image interpretation does not parallel your findings or if I can be of any further assistance please contact me.

Beth Johnson, DVM, DACVIM
Beth.Johnson@sonopath.com