



PATIENT	PRESENTING CLINICAL SIGNS
Kenzie Lee	11 yo FS shih tzu presenting for elevated GGT, ALP, and calcium. Hepatomegaly History of urinary issues No reported PU/PD
SPECIES	ULTRASONOGRAPHIC EXAMINATION OF THE ABDOMEN
Canine	Urinary System
BREED	Urinary bladder is only mildly distended (empty). Visible contents are anechoic. Urinary bladder wall is unable to be fully assessed for pathology without further distension. No visible masses or cystoliths are observed. The trigone and visible pelvic urethra are normal thickness with a smooth mucosal surface. If there are urinary signs and/or concern for urinary bladder pathology, reassessment after complete filling is recommended.
Shih Tzu	
SEX	The right kidney is normal in size (4.3 cm), shape and echogenicity. It has smooth peripheral margination. There is a normal 1:3 cortex to medulla ratio with appropriate corticomedullary distinction. There is no evidence of pyelectasia or infarcts observed. Non-obstructive linear multifocal hyperechoic diverticular foci with acoustic shadowing are noted. A hyperechoic band parallel to the corticomedullary border is present.
Spayed Female	
AGE	The left kidney is normal in size (4.1 cm), shape and echogenicity. It has smooth peripheral margination. There is a normal 1:3 cortex to medulla ratio with appropriate corticomedullary distinction. There is no evidence of pyelectasia or infarcts observed. Non-obstructive linear multifocal hyperechoic diverticular foci with acoustic shadowing are noted. A hyperechoic band parallel to the corticomedullary border is present.
11 Years	
WEIGHT	
20 Pounds	
INTERPRETED BY	Adrenal Glands
Beth Johnson, DVM DACVIM	The right adrenal gland is normal in size (0.88 cm at the cranial pole and 0.50 cm at the caudal pole), shape and contour. Corticomedullary structure is unremarkable. Visible surrounding vasculature appears normal.
IMAGING PERFORMED BY	The left adrenal gland is normal in size (0.49 cm at the cranial pole and 0.59 cm at the caudal pole), shape and contour. Corticomedullary structure is unremarkable. Visible surrounding vasculature appears normal.
Dr. Elaina Petrone	
HOSPITAL NAME	Spleen
Long Branch AH	The spleen is subjectively normal in size with a normal smooth capsular contour. Parenchyma is appropriately finely textured and homogenous with normal echogenicity relative to surrounding tissue (hyperechoic to liver). No focal nodules or masses are observed. Splenic vasculature appears normal.
REFERRING VET	Liver
Dr. Elaina Petrone	Liver is subjectively enlarged with mildly irregular margins. Parenchyma is mottled by multifocal discrete hypoechoic nodules of varying sizes "moth-eaten". Visible vasculature and biliary tree appear normal without distension or congestion.
INVOICE	
40443	The gallbladder is non-distended in size. The wall is smooth without visible thickening. Luminal contents are primarily anechoic. There is no evidence of cystic or common bile duct dilation.
DATE	Gastrointestinal
8/15/22	The stomach wall is normal in thickness (canine < 0.5 cm and feline < 0.4 cm) and layering. The lumen of the stomach is empty with no evidence of obstruction, foreign material or infiltrative disease. Pyloric outflow tract appears patent.



PATIENT

Kenzie Lee

The visible small intestines are normal in wall thickness and layering (canine duodenum < 0.5 cm and feline duodenum < 0.4 cm; other < 0.3 cm). Small intestinal motility appears adequate (1-3 contractions per min). The lumen of the small intestine is empty with no evidence of obstruction, foreign material or infiltrative disease.

SPECIES

Canine

The visible colon is normal in wall thickness (< 0.2 cm) and layering. Contents are consistent with normal formed feces and gas.

Pancreas

BREED

Shih Tzu

The pancreatic parenchyma is appropriately isoechoic to surrounding tissue. Visible capsule is smooth and normal in contour. There is no visible pancreatic duct dilation. There is no evidence of active peripancreatic inflammation.

SEX

Spayed Female

Free Abdomen

There is no evidence of free peritoneal effusion noted in these images.

There is no apparent lymphadenopathy noted in these images.

AGE

11 Years

ULTRASONOGRAPHIC FINDINGS

- **Nodular Liver** - This finding is concerning for infiltrative disease such as round cell neoplasia or metastatic neoplasia. Benign disease (nodular hyperplasia) cannot be ruled out but is considered less likely.
- Bilateral non-obstructive dystrophic mineralization in the kidneys
- **Medullary rim sign** - This finding is of unknown clinical significance and can be a normal variant, often idiopathic. Medullary rim sign can be present with renal disease including FIP, lymphoma, hypercalcemic nephropathy, Leptospirosis, tubular disease, other and should be interpreted in combination with other more specific indications of kidney disease such as isosthenuria, proteinuria, azotemia, etc. This is a common incidental finding in patients with diabetes mellitus.

WEIGHT

20 Pounds

INTERPRETED BY

Beth Johnson, DVM
DACVIM

IMAGING PERFORMED BY

Dr. Elaina Petrone

HOSPITAL NAME

Long Branch AH

INTERPRETATION OF THE FINDINGS & FURTHER RECOMMENDATIONS

Given this patient's hypercalcemia and the appearance of the liver, infiltrative neoplasia and hypercalcemia of malignancy is of concern. Therefore, a fine needle aspirate of the liver, as is reportedly pending, is recommended if patient's coagulation status is appropriate. If a diagnosis of malignancy is not obtained cytology, a malignancy profile including PTH, PTHrP, and ionized calcium is recommended for further reevaluation of the hypercalcemia.

REFERRING VET

Dr. Elaina Petrone

Three view thoracic radiographs are recommended for further assessment of cardio-pulmonary status as well as to further evaluate for any evidence of metastatic disease, if not recently evaluated.

Given the reported urinary issues, a urinalysis and, if indicated based on urinalysis results, urine culture are recommended. If protein is present in an otherwise quiet sediment, protein quantification with a urine protein to creatinine ration is recommended.

INVOICE

40443

DATE

8/15/22



PATIENT

Kenzie Lee

SPECIES

Canine

BREED

Shih Tzu

SEX

Spayed Female

AGE

11 Years

WEIGHT

20 Pounds

INTERPRETED BY

Beth Johnson, DVM
DACVIM

IMAGING PERFORMED BY

Dr. Elaina Petrone

HOSPITAL NAME

Long Branch AH

REFERRING VET

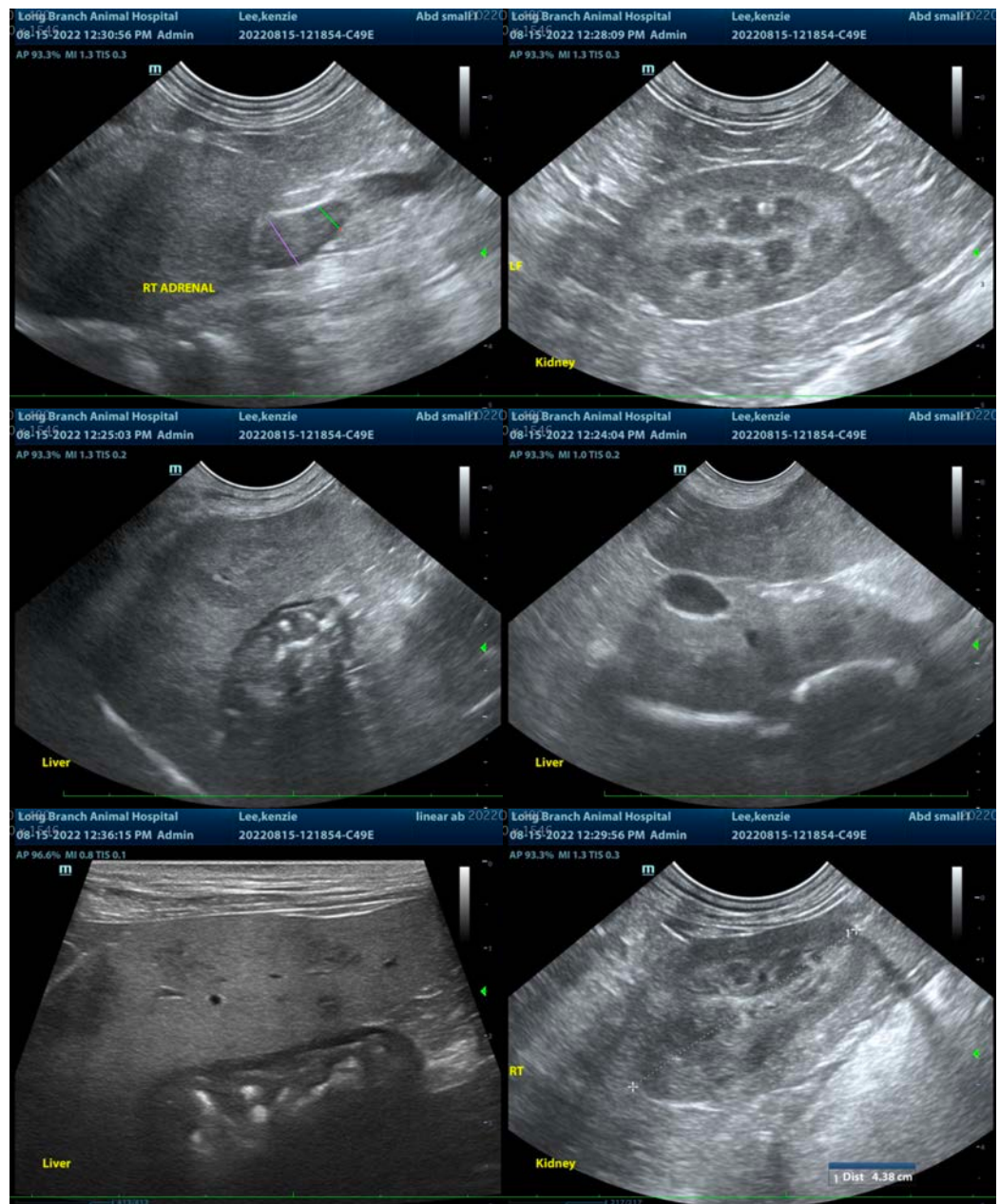
Dr. Elaina Petrone

INVOICE

40443

DATE

8/15/22





PATIENT

Kenzie Lee

SPECIES

Canine

BREED

Shih Tzu

SEX

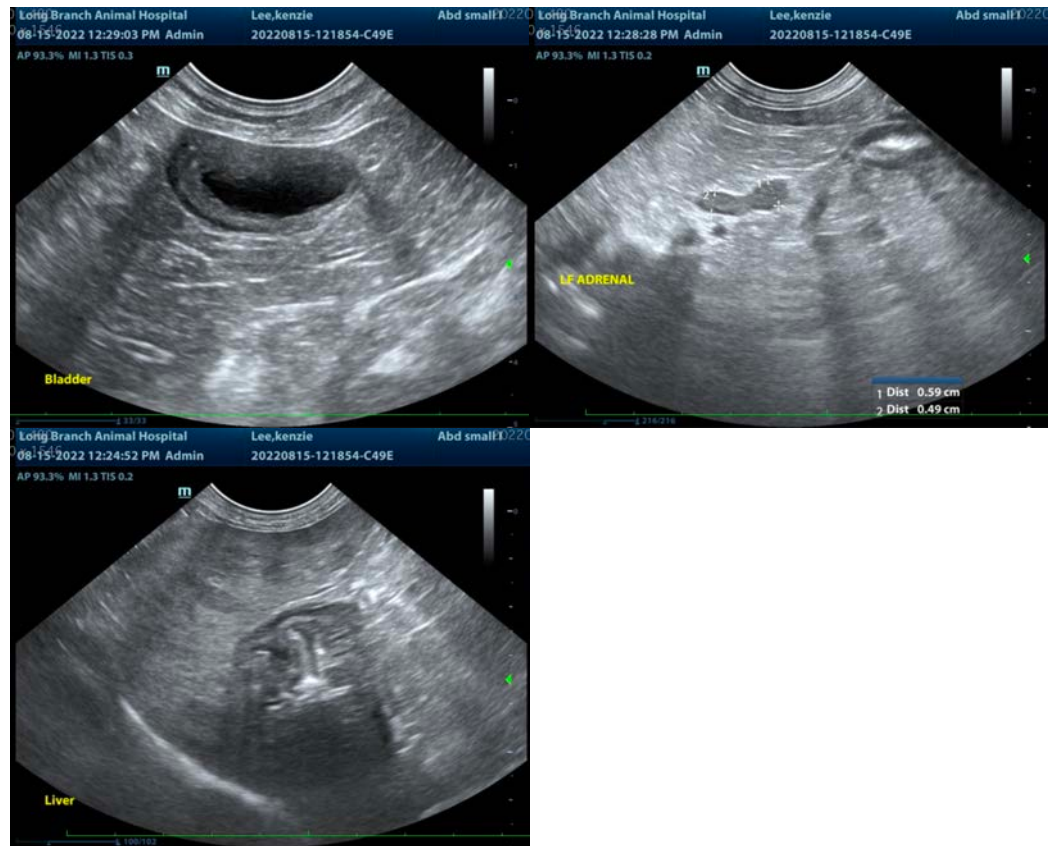
Spayed Female

AGE

11 Years

WEIGHT

20 Pounds



INTERPRETED BY

Beth Johnson, DVM
DACVIM

IMAGING PERFORMED BY

Dr. Elaina Petrone

HOSPITAL NAME

Long Branch AH

REFERRING VET

Dr. Elaina Petrone

INVOICE

40443

DATE

8/15/22

The information and recommendations provided are based on the images presented by the referring veterinarian/sonographer. No evaluation can be communicated regarding pathology that was not visible in the image/video clips provided.

Thank you for this referral. If the clinical or image interpretation does not parallel your findings or if I can be of any further assistance please contact me.

Beth Johnson, DVM, DACVIM
Beth.Johnson@sonopath.com