

**DATE PRESENTING CLINICAL SIGNS**

8/14/23

History: Presented for mammary mass removal. Pre-op BW revealed liver elevations and neutrophilia.
 *The age of this patient is unknown.

PATIENT

Roxy Carter

Current Medications: None listed.

Lab Results: ALT 509, ALP 175. Cholesterol and triglycerides increased.

Date of Previous IntraPet Ultrasound: No previous.

SPECIES

Sedation: Not required to complete full diagnostic ultrasound.

Canine

Stat Report: Not requested.

Imaging Performed By: Andi Parkinson, BS, RDMS.

BREED

Chihuahua Mix

ULTRASONOGRAPHIC EXAMINATION OF THE ABDOMEN**SEX****Urinary System**

Urinary bladder is adequately distended. It has a normal uniform wall thickness. Contents include primarily anechoic fluid with occasional echogenic non-shadowing debris, most consistent with exfoliated cells, mucous and/or small blood clots. Both sterile inflammation as well as urinary tract infection can also present with echogenic debris. No masses are observed. The trigone and visible pelvic urethra are normal in thickness with a smooth mucosal surface. A 1.37 cm shadowing cystolith is noted.

Spayed Female

AGE

N/A

Kidneys are overall normal in size and shape with smooth peripheral margination. A normal 1:3 cortex to medulla ratio is maintained. The medulla and cortices are uniform in texture with some mild increased cortical echogenicity and mild loss of corticomedullary distinction, expected in this age patient. There is no evidence of pyelectasia or infarcts observed. The left kidney measures 3.83 cm. The right kidney measures 4.03 cm. Small cortical cysts are noted bilaterally. Bilateral punctate nonobstructive nephroliths are noted.

WEIGHT

12.2 Pounds

Adrenal Glands

Left adrenal gland is normal in size (0.45 cm at cranial pole and 0.59 cm at caudal pole), shape and overall architecture, echogenicity and echotexture. Visible surrounding vasculature appears normal.

INTERPRETED BYBeth Johnson, DVM
DACVIM

Right adrenal gland is normal in size (0.65 cm at cranial pole and 0.79 cm at caudal pole), shape and overall architecture, echogenicity and echotexture. Visible surrounding vasculature appears normal.

HOSPITAL NAME

Eastern AH

Spleen

Spleen is subjectively normal in size with a normal smooth capsular contour. Parenchyma is appropriately finely textured and homogenous with normal echogenicity relative to surrounding tissue (hyperechoic to liver). No focal nodules or masses are observed. Splenic vasculature appears normal.

REFERRING VET

Dr. Parrish

Liver

Liver is subjectively enlarged with mildly irregular margins. Parenchyma is mottled by multifocal discrete hyperechoic nodules with hypoechoic rims of varying sizes "moth-eaten with target lesions". Visible vasculature and biliary tree appear normal without distension or congestion.

INVOICE

23935

Gallbladder is moderately distended with anechoic bile as well as suspended and gravity dependent echogenic debris. The wall is smooth without visible thickening. There is no evidence of cystic or CBD dilation. There is no evidence of effusion or inflammation.

Gastrointestinal

The visible stomach wall is normal in thickness and layering. The lumen of the stomach is empty with no evidence of obstruction, foreign material or infiltrative disease. Pyloric outflow tract appears patent.

The visible small intestines are normal in wall thickness and layering. Small intestinal motility appears adequate (1-3 contractions per min). The lumen of the small intestine is empty with no evidence of obstruction, foreign material or infiltrative disease.

The visible colon is normal in wall thickness and layering. Contents are consistent with normal formed feces and gas.

Pancreas

The area of the pancreas contains irregular hyperechoic pancreatic remodeling.

Free Abdomen

There is no evidence of peritoneal effusion. There is no apparent lymphadenopathy.

ULTRASONOGRAPHIC FINDINGS

Primary Findings

- The nodular liver could represent benign change, as is seen with nodular hyperplasia vs other, however, given the “target lesion” appearance of the nodules, the change is concerning for infiltrative neoplasia/metastatic neoplasia.
- Hyperechoic pancreas – This finding is suggestive of pancreatic fibrosis, possibly secondary to chronic pancreatitis. A TLI is recommended to rule out exocrine pancreatic insufficiency (EPI), especially if clinical signs (weight loss, diarrhea, etc.) are present.
- A urinary bladder cystolith, measuring 1.37 cm in diameter.

Secondary Findings

- Mild gallbladder debris - Cholecystic debris is of unknown clinical significance. It can be seen with biliary stasis from fasting or illness. Cholecystic debris is not necessarily related to hepatobiliary disease. Echogenic bile is most commonly an incidental finding in dogs and should be interpreted in combination with clinical signs such as nausea, inappetence, cranial abdominal discomfort and/or laboratory changes such as increased ALP and/or increased Tbili.
- Age-related kidney changes with bilateral cortical cysts and nonobstructive nephroliths

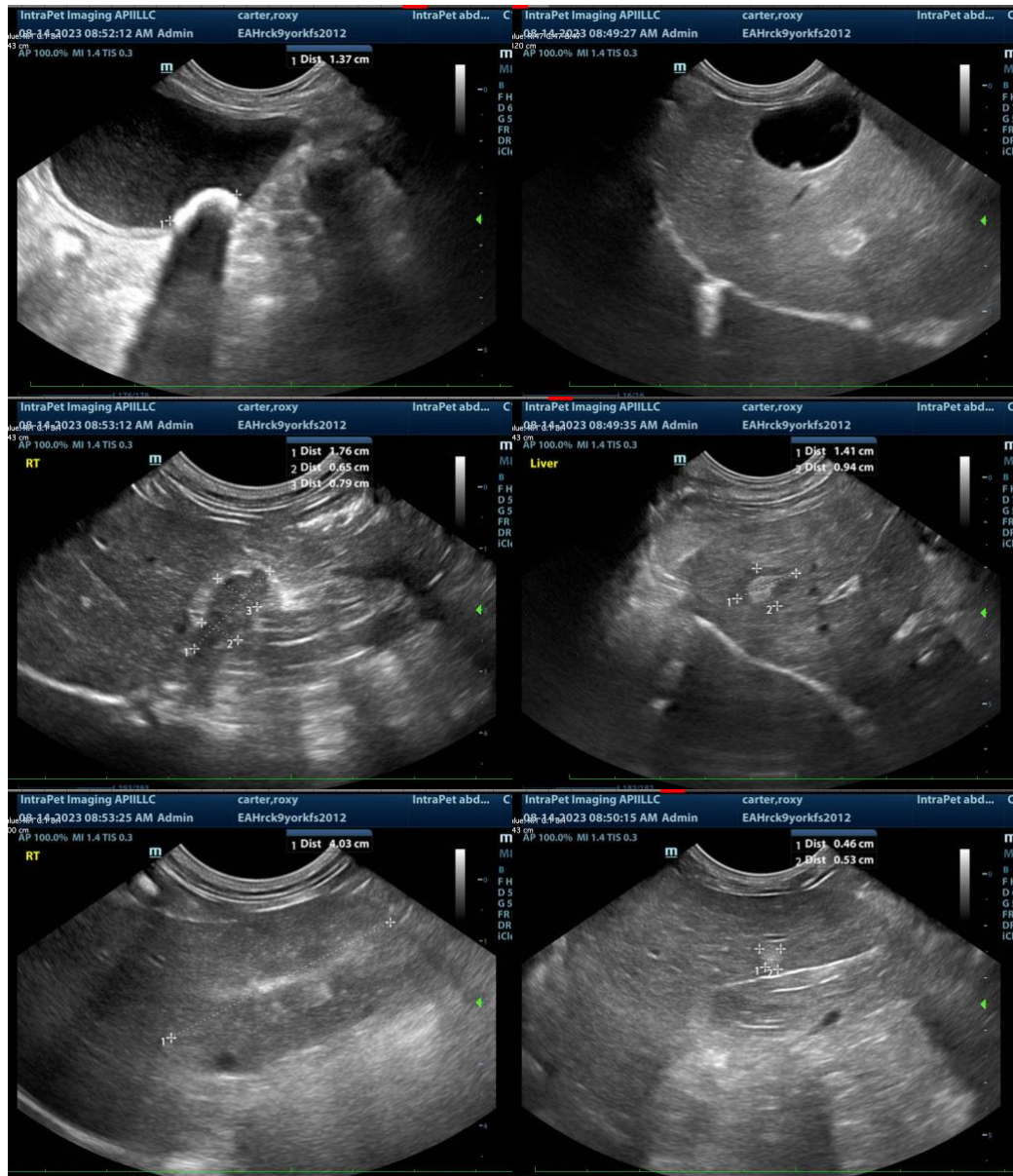
INTERPRETATION OF THE FINDINGS & FURTHER RECOMMENDATIONS

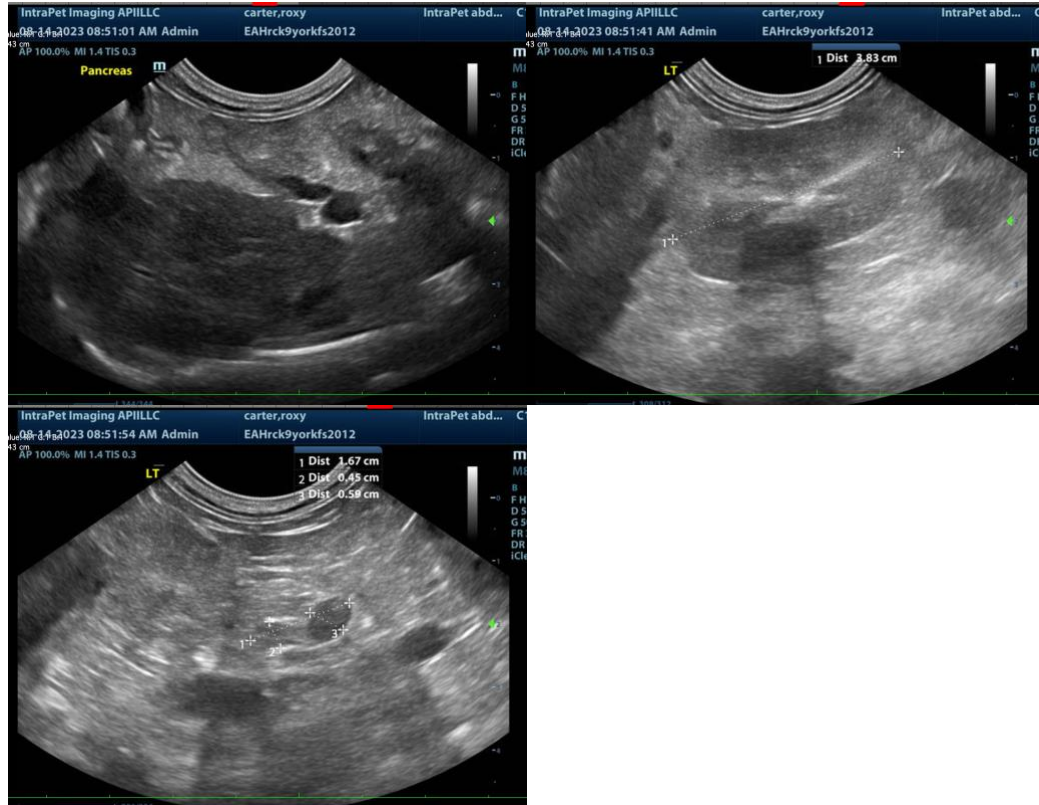
Prior to further evaluating/removing the reported mammary mass, if not recently evaluated, three view thoracic radiographs are recommended for further assessment of cardio-pulmonary status as well as to further evaluate for any evidence of metastatic disease, if not recently evaluated, as well as, as fine needle aspirate of the liver nodules, could be considered if patients coagulation status is appropriate.

Ultimately, consultation with a veterinary oncologist could be considered.

Additionally, if not recently evaluated, urinalysis and, if indicated based on urinalysis results, urine culture is recommended. If protein is present in an otherwise quiet sediment, protein quantification with a urine protein to creatinine ration is recommended.

Incidentally, given the hyperechoic pancreas, if there is any history of gastrointestinal disease, etc., further evaluation of digestion/absorption could be considered, beginning with a gastrointestinal malabsorption panel (including cobalamin, folate, TLI and PLI) to Texas A&M GI Laboratory is recommended for further evaluation of GI and pancreatic function.





The information and recommendations provided are based on the images presented by the referring veterinarian. No evaluation can be communicated regarding pathology that was not visible in the image/video clips provided.

Thank you for this referral. If the clinical or image interpretation does not parallel your findings or if I can be of any further assistance please contact me.

Beth Johnson, DVM DACVIM
info@sonopath.com