

**DATE PRESENTING CLINICAL SIGNS**

8/14/23

History: Treated for a UTI on 7/24/23- recheck U/A on 8/7/23 showed bacteria, rbc's, and wbc's; UTI symptoms at that time had resolved urine culture done w/no growth. On 8/10/23 O saw drops of blood in P's urine. Otherwise doing well, nsf on PE on 8/11/23.

PATIENT

Mila Welsch

Current Medications: None.

Lab Results: See attached.

SPECIES

Radiographs: No uroliths seen.

Canine

Date of Previous IntraPet Ultrasound: No previous.

Sedation: Not required to complete full diagnostic ultrasound.

BREED

Stat Report: Not requested.

Imaging Performed By: Andi Parkinson, BS, RDMS.

Mixed Breed

SEX**LIMITED ULTRASONOGRAPHIC EXAMINATION**

Spayed Female

Urinary bladder is adequately distended with primarily anechoic contents and occasional echogenic non-shadowing debris. Apical urinary bladder wall is mildly thick, measuring 0.28 cm thick. Mucosa is hyperechoic and irregular. No masses or cystoliths are observed. The trigone and visible pelvic urethra are normal thickness with a smooth mucosal surface.

AGE

5/19/16

Left kidney is normal is size (4.85 cm), shape and echogenicity. It has smooth peripheral margination. There is a normal 1:3 cortex to medulla ratio with appropriate corticomedullary distinction. There is no evidence of pyelectasia, mineral or infarcts observed.

WEIGHT

27 Pounds

Right kidney is normal is size (4.86 cm), shape and echogenicity. It has smooth peripheral margination. There is a normal 1:3 cortex to medulla ratio with appropriate corticomedullary distinction. There is no evidence of pyelectasia, mineral or infarcts observed.

INTERPRETED BYBeth Johnson, DVM
DACVIM**ULTRASONOGRAPHIC FINDINGS****HOSPITAL NAME**

Charm City Vet

- Mild chronic cystitis - Urinary bladder wall changes are most consistent with chronic cystitis. Infiltrative neoplasia cannot be ruled out but is considered less likely give the location and diffuse nature of the changes.

REFERRING VET

Dr. Karbonik

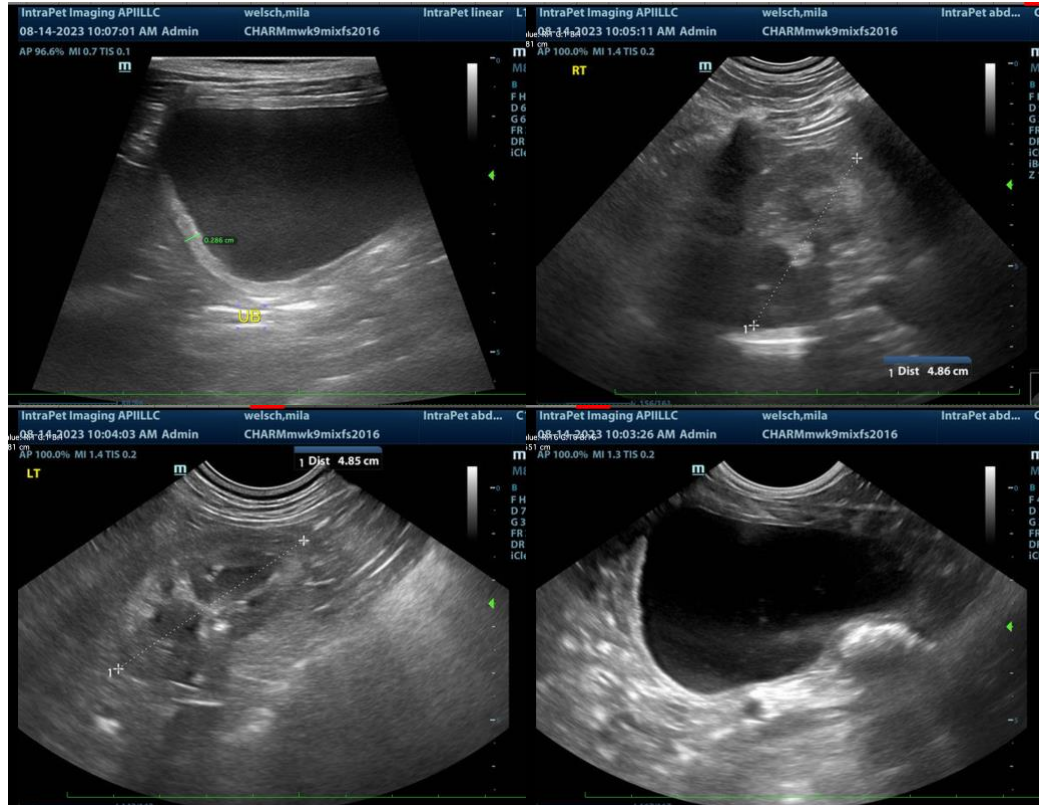
INTERPRETATION OF THE FINDINGS & FURTHER RECOMMENDATIONS

There is no ultrasonographically visible definitive explanation for this patients recurrent urinary tract infections. Given the patient history, one differential is a persistent, non-fully cleared urinary tract infection, potentially with a false negative follow up culture due to recent antibiotic results vs truly recurrent urinary tract infections.

INVOICE

23947

Ideally, recheck urinalysis, urine culture, etc., would be considered a week to 10 days after finishing antibiotics, however, if patient is still on antibiotics and needs to be to control clinical signs, recommendations include a longer course of treatment, i.e., 4+ weeks with a final follow up urinalysis and culture a week to 10 days after finishing the longer course of antibiotics.



The information and recommendations provided are based on the images presented by the referring veterinarian. No evaluation can be communicated regarding pathology that was not visible in the image/video clips provided.

Thank you for this referral. If the clinical or image interpretation does not parallel your findings or if I can be of any further assistance please contact me.

Beth Johnson, DVM DACVIM
info@SonoPath.com