



PATIENT	PRESENTING CLINICAL SIGNS
Sasha Bryant	Ruptured R CCL 1 week ago Ruptured L CCL in 2020 P is taking meloxicam daily since L CCL repair Abnormal PE/Chem/CBC/UA Results: 8/9 ALT 143 ALP 294
SPECIES	ULTRASONOGRAPHIC EXAMINATION OF THE ABDOMEN
Canine	Urinary System
BREED	The urinary bladder is moderately distended with anechoic contents. No masses, inflammatory changes, echogenic sediment or cystoliths are observed. The urinary bladder, trigone and visible pelvic urethra are normal in thickness with a smooth mucosal surface.
Lab X	Kidneys are overall normal in size and shape with smooth peripheral margination. A normal 1:3 cortex to medulla ratio is maintained. The medulla and cortices are uniform in texture with some mild increased cortical echogenicity and mild loss of corticomedullary distinction, expected in this age patient. There is no evidence of pyelectasia, mineral or infarcts observed. The left kidney measures 6.2 cm. The right kidney measures 5.6 cm.
SEX	Adrenal Glands
Spayed Female	The area of the right adrenal gland is examined without evident pathology.
AGE	The left adrenal gland is normal in size (0.60 cm at the cranial pole and 0.60 cm at the caudal pole), shape and contour. Corticomedullary structure is unremarkable. Visible surrounding vasculature appears normal.
8 Years	Spleen
WEIGHT	Spleen is subjectively large in size with a normal smooth capsular contour. Parenchyma is appropriately finely textured and homogenous with normal echogenicity relative to surrounding tissue (hyperechoic to liver). Multifocal well demarcated, hyperechoic, homogeneous nodules are present. Splenic vasculature appears normal. The spleen is folded upon itself, which is a positional non-pathologic variant.
79 Pounds	Liver
INTERPRETED BY	Liver is subjectively enlarged (swollen contour) without disruption of architecture. It has a normal homogenous echotexture. Parenchyma is diffusely hyperechoic characterized by less prominent than normal portal vein walls and increased echogenicity relative to the spleen and falciform fat. No focal lesions are observed. Visible vasculature and biliary tree appear normal without distension or congestion.
Beth Johnson, DVM DACVIM	The gallbladder is non-distended in size. The wall is smooth without visible thickening. Luminal contents are primarily anechoic. There is no evidence of cystic or common bile duct dilation.
IMAGING PERFORMED BY	Gastrointestinal
Dr. Kevin Moon	The stomach wall is normal in thickness (canine < 0.5 cm and feline < 0.4 cm) and layering. The lumen of the stomach is empty with no evidence of obstruction, foreign material or infiltrative disease. Pyloric outflow tract appears patent.
HOSPITAL NAME	The visible small intestines are normal in wall thickness and layering (canine duodenum < 0.5 cm and feline duodenum < 0.4 cm; other < 0.3 cm). Small intestinal motility appears adequate (1-3 contractions per min). The lumen of the small intestine is empty with no evidence of obstruction, foreign material or infiltrative disease.
Shiloh Vet Hospital	
REFERRING VET	
Dr. Kevin Moon	
INVOICE	
40398	
DATE	
8/12/22	



PATIENT

Sasha Bryant The visible colon is normal in wall thickness (< 0.2 cm) and layering. Contents are consistent with normal formed feces and gas.

SPECIES *Pancreas*

Canine The pancreatic parenchyma is appropriately isoechoic to surrounding tissue. Visible capsule is smooth and normal in contour. There is no visible pancreatic duct dilation. There is no evidence of active peripancreatic inflammation.

BREED *Free Abdomen*

Lab X There is no evidence of free peritoneal effusion noted in these images.

SEX The medial iliac lymph nodes are prominent in size with swollen capsular contour. Normal elongated shape (length to width ratio) is maintained. There is no loss of parenchymal detail.

Spayed Female

PRIMARY FINDINGS

- AGE** 8 Years
- **Hyperechoic hepatomegaly** - This appearance is non-specific and most consistent with a benign steroid (endocrine) or vacuolar hepatopathy or reactive or idiopathic hepatopathy. Inflammatory and/or infiltrative disease (such as round cell neoplasia) are also possible, but considered less likely.

WEIGHT **SECONDARY FINDINGS**

- 79 Pounds
- **Reactive medial iliac lymph nodes** - infiltrative neoplastic disease cannot be ruled out but is considered less likely.

INTERPRETED BY

Beth Johnson, DVM
DACVIM

- **Hyperechoic splenic nodules** - most consistent with benign myelolipomas. Other differentials such as fibrosis or calcification caused by old hematomas or infarcts, chronic inflammation, granulomatous disease or metastatic disease cannot be ruled out, but are considered less likely.

IMAGING PERFORMED BY

Dr. Kevin Moon

- Age related kidney changes

INTERPRETATION OF THE FINDINGS & FURTHER RECOMMENDATIONS

HOSPITAL NAME

Shiloh Vet Hospital

An obvious cause for the reported increased liver enzymes is not identified in these images. Microscopic disease such as Leptospirosis, bacterial cholangiohepatitis, chronic active hepatitis, copper-associated hepatotoxicity, other hepatotoxicity, infiltrative neoplasia (considered unlikely), etc. cannot be definitively ruled out.

REFERRING VET

Dr. Kevin Moon

Recommendations include an “antigen search” for sources of reactive hepatopathy (including testing for Leptospirosis), followed by a course of empirical antibiotics and hepatic nutraceuticals, with monitoring of ALT for improvement. If improvement is not noted and/or enzyme increase progresses, a liver biopsy may be warranted.

INVOICE

40398

Quality of life is the primary goal. However, is possible to maintain a food quality of life on less nonsteroidal, then that is recommended. Options could include other arthritis support such as fatty acids, Adequan, intraarticular injections, physical therapy, acupuncture, laser therapy, as well as oral pain management other than nonsteroidals. However, reducing the nonsteroidal likely isn't possible until after the recovery from the most recent cruciate tear.

DATE

8/12/22



PATIENT

Sasha Bryant

SPECIES

Canine

BREED

Lab X

SEX

Spayed Female

AGE

8 Years

WEIGHT

79 Pounds

INTERPRETED BY

Beth Johnson, DVM
DACVIM

IMAGING PERFORMED BY

Dr. Kevin Moon

HOSPITAL NAME

Shiloh Vet Hospital

REFERRING VET

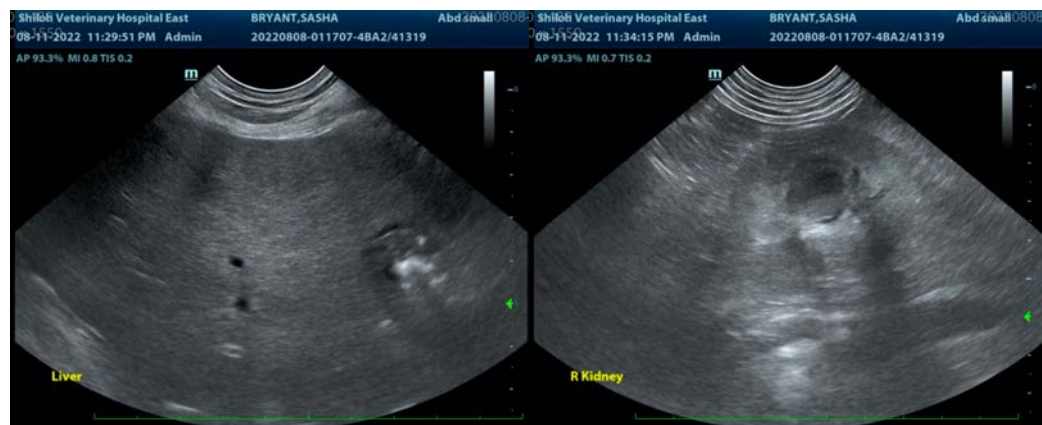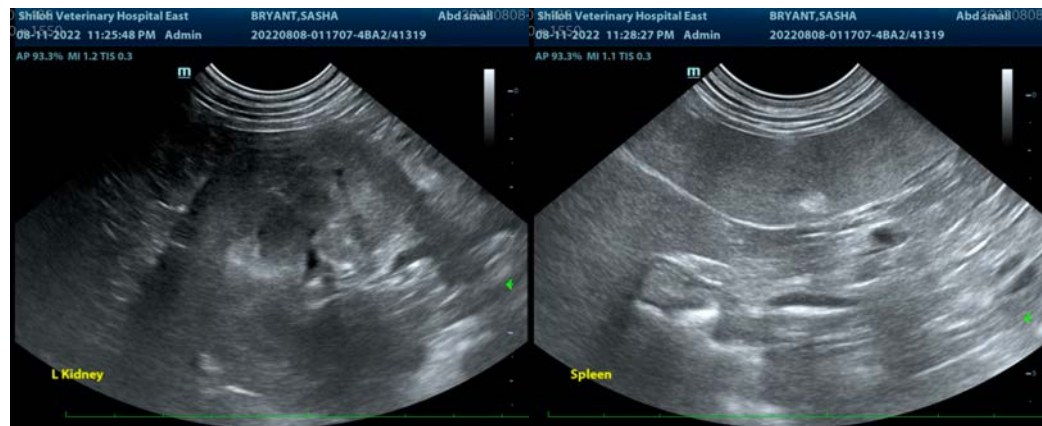
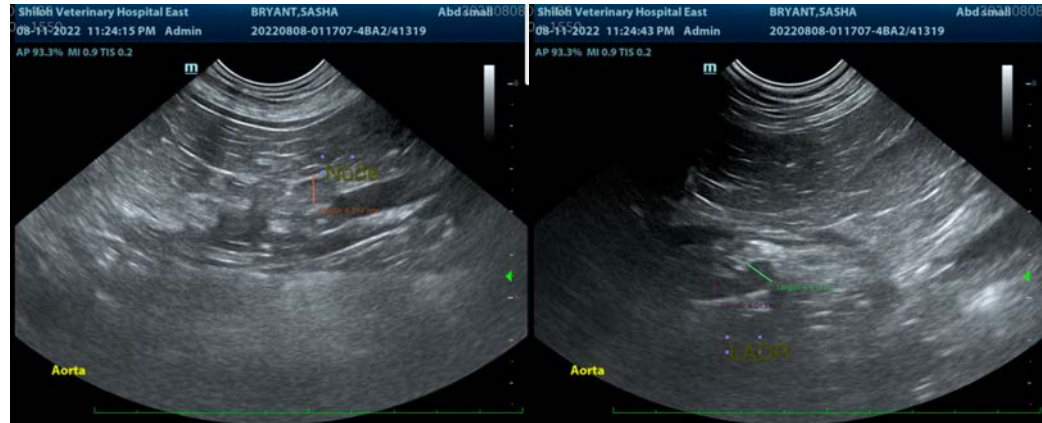
Dr. Kevin Moon

INVOICE

40398

DATE

8/12/22





PATIENT

Sasha Bryant

SPECIES

Canine

BREED

Lab X

SEX

Spayed Female

AGE

8 Years

WEIGHT

79 Pounds

INTERPRETED BY

Beth Johnson, DVM
DACVIM

**IMAGING
PERFORMED BY**

Dr. Kevin Moon

HOSPITAL NAME

Shiloh Vet Hospital

REFERRING VET

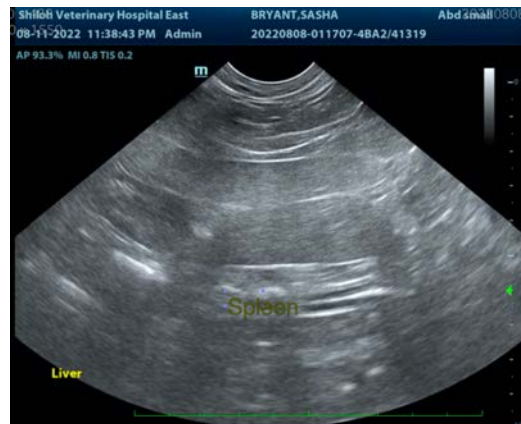Dr. Kevin Moon

INVOICE

40398

DATE

8/12/22



The information and recommendations provided are based on the images presented by the referring veterinarian/sonographer. No evaluation can be communicated regarding pathology that was not visible in the image/video clips provided.

Thank you for this referral. If the clinical or image interpretation does not parallel your findings or if I can be of any further assistance please contact me.

Beth Johnson, DVM, DACVIM
Beth.Johnson@sonopath.com