



PATIENT

Zaylia Sparks

SPECIES

Canine

BREED

Border Collie X

SEX

Spayed Female

AGE

5 Years

WEIGHT

23.1 kg

INTERPRETED BY

Beth Johnson, DVM
DACVIM

IMAGING PERFORMED BY

Dr. Nigel Gumley

HOSPITAL NAME

Cedarview AH

REFERRING VET

Dr. Nigel Gumley

INVOICE

40347

DATE

8/11/22

PRESENTING CLINICAL SIGNS

Diagnosed with Addison's disease (subnormal ACTH response, hyperkalemia, low Na/K ratio) when hyperkalemia discovered on routine bloodwork for anesthesia. Chronic gastroenteritis, previously presumed to be IBD. Currently on Florinef and prednisone and electrolytes have normalized but is losing muscle mass; it is suspected the prednisone dose is too high and is affecting her adversely. Abnormal PE/Chem/CBC/UA Results: Thin, muscle atrophy over shoulders, head. Thin skin. Current blood and urine results pending but June BW showed marked elevation in ALT (778) and ALP(548). Voracious appetite. Lipase > 6000.

ULTRASONOGRAPHIC EXAMINATION OF THE ABDOMEN

Urinary System

The urinary bladder is moderately distended with anechoic contents. No masses, inflammatory changes, echogenic sediment or cystoliths are observed. The urinary bladder, trigone and visible pelvic urethra are normal in thickness with a smooth mucosal surface.

The right kidney is normal in size 6.4 (cm), shape and echogenicity. It has smooth peripheral margination. There is a normal 1:3 cortex to medulla ratio with appropriate corticomedullary distinction. There is no evidence of pyelectasia or infarcts observed. Non-obstructive linear multifocal hyperechoic diverticular foci with acoustic shadowing are noted.

The left kidney is normal in size (6.52 cm), shape and echogenicity. It has smooth peripheral margination. There is a normal 1:3 cortex to medulla ratio with appropriate corticomedullary distinction. There is no evidence of pyelectasia or infarcts observed. Non-obstructive linear multifocal hyperechoic diverticular foci with acoustic shadowing are noted.

Adrenal Glands

Adrenal glands are small (flattened contour). Corticomedullary structure is unremarkable. Visible surrounding vasculature appears normal. The left adrenal gland measures 0.28 cm at the cranial pole and 0.36 cm at the caudal pole. The right adrenal gland measures 0.49 cm at the cranial pole and 0.54 cm at the caudal pole.

Spleen

The spleen is subjectively normal in size with a normal smooth capsular contour. Parenchyma is appropriately finely textured and homogenous with normal echogenicity relative to surrounding tissue (hyperechoic to liver). No focal nodules or masses are observed. Splenic vasculature appears normal.

Liver

Liver is subjectively enlarged (swollen contour) without disruption of architecture. It has a normal homogenous echotexture. Parenchyma is diffusely hyperechoic characterized by less prominent than normal portal vein walls and increased echogenicity relative to the spleen and falciform fat. No focal lesions are observed. Visible vasculature and biliary tree appear normal without distension or congestion.

The gallbladder is non-distended in size. The wall is smooth without visible thickening. Luminal contents are primarily anechoic. There is no evidence of cystic or common bile duct dilation.

Gastrointestinal

The visible stomach wall is normal in thickness and layering. The lumen of the stomach is moderately distended with echogenic non-shadowing luminal contents and gas consistent with normal ingesta.



PATIENT	There is no evidence of obstruction, foreign material or infiltrative disease. Pyloric outflow tract appears patent.
Zaylia Sparks	
SPECIES	The visible small intestines are normal in wall thickness and layering. Small intestinal motility appears adequate (1-3 contractions per min). The lumen of the small intestine is mildly distended with echogenic non-shadowing luminal contents and gas consistent with normal ingesta. There is no evidence of obstruction, foreign material or infiltrative disease.
Canine	
BREED	The visible colon is normal in wall thickness (< 0.2 cm) and layering. Contents are consistent with normal formed feces and gas.
Border Collie X	
SEX	Pancreas The pancreatic parenchyma is appropriately isoechoic to surrounding tissue. Visible capsule is smooth and normal in contour. There is no visible pancreatic duct dilation. There is no evidence of active peripancreatic inflammation.
Spayed Female	
AGE	Free Abdomen There is no evidence of free peritoneal effusion noted in these images.
5 Years	The medial iliac lymph nodes are prominent in size with swollen capsular contour. Normal elongated shape (length to width ratio) is maintained. There is no loss of parenchymal detail.
WEIGHT	ULTRASONOGRAPHIC FINDINGS
23.1 kg	<ul style="list-style-type: none"> • Bilateral flat adrenal glands – consistent with the previous diagnosis of hypoadrenocorticism. • Reactive medial iliac lymph nodes – infiltrative neoplastic disease cannot be ruled out but is considered less likely. • Hyperechoic hepatomegaly - This appearance is non-specific and most consistent with a benign steroid (endocrine) or vacuolar hepatopathy or reactive or idiopathic hepatopathy. Inflammatory and/or infiltrative disease (such as round cell neoplasia) are also possible, but considered less likely. • Non-obstructive dystrophic mineralization of the kidneys bilaterally.
INTERPRETED BY	INTERPRETATION OF THE FINDINGS & FURTHER RECOMMENDATIONS
Beth Johnson, DVM DACVIM	There is no new ultrasonographically visible explanation for this patient’s muscle wasting, etc., and based on history the cause of the muscle wasting being too much glucocorticoid seems plausible. Florinef contains both glucocorticoid as well as mineralocorticoid, and many animals after the initial crisis do not need additional glucocorticoid in the form of Prednisone on top of Florinef. In fact, many animals actually have glucocorticoid side effects just from the dose of Florinef alone needed to maintain normal electrolytes. In those animals, management of hypoadrenocorticism with Prednisone and Desoxycorticosterone pivalate (DOCP) often achieves better results.
IMAGING PERFORMED BY	
Dr. Nigel Gumley	
HOSPITAL NAME	
Cedarview AH	
REFERRING VET	
Dr. Nigel Gumley	
INVOICE	In this patient, recommendations are to start tapering Prednisone, eventually discontinuing Prednisone, and if the side effects of the glucocorticoid and the Florinef are still too high, discontinue Florinef and restart treatment with Prednisone and DOCP. As long as the patient is clinically stable, and laboratory changes such as azotemia, hypoalbuminemia, anemia, etc. are not present to indicate glucocorticoid deficiency, then glucocorticoid supplementation is considered adequate at that time.
40347	
DATE	
8/11/22	



PATIENT

Zaylia Sparks

SPECIES

Canine

BREED

Border Collie X

SEX

Spayed Female

AGE

5 Years

WEIGHT

23.1 kg

INTERPRETED BY

Beth Johnson, DVM
DACVIM

IMAGING PERFORMED BY

Dr. Nigel Gumley

HOSPITAL NAME

Cedarview AH

REFERRING VET

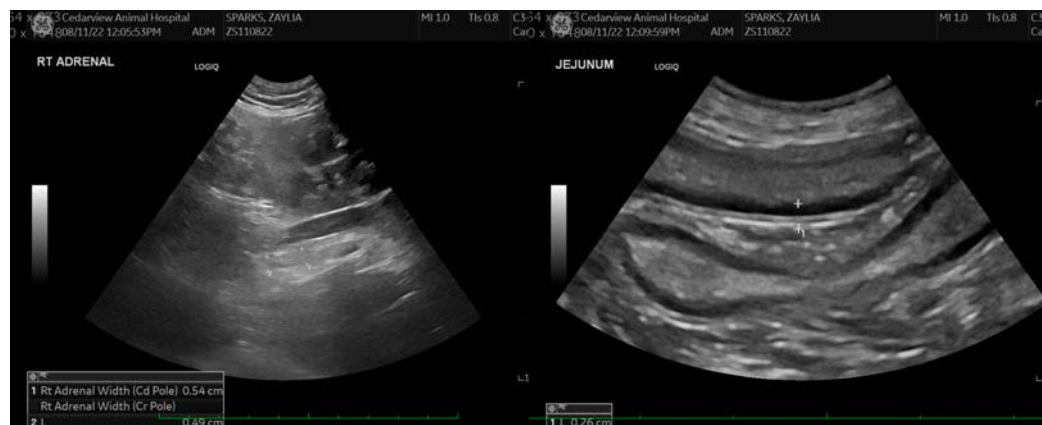
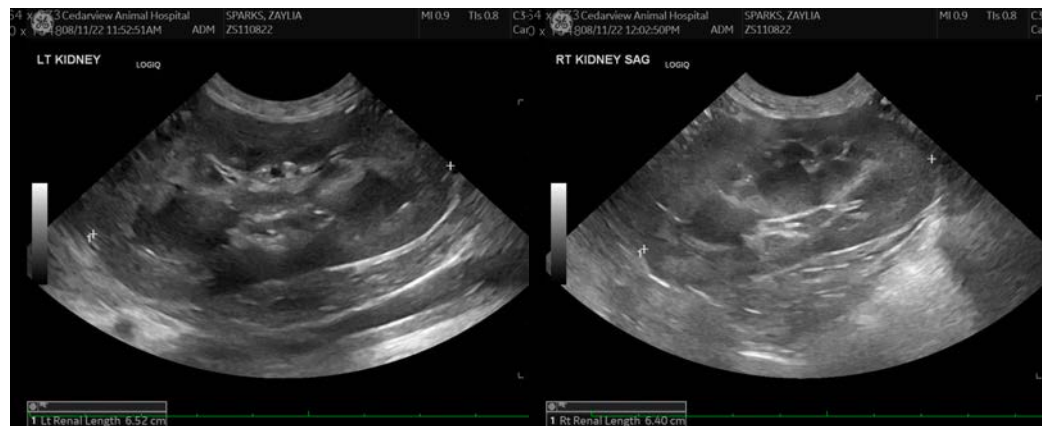
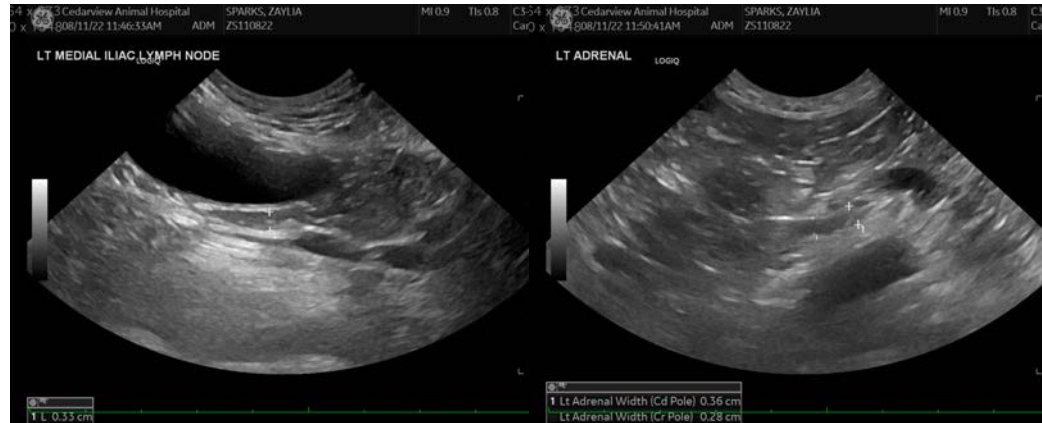
Dr. Nigel Gumley

INVOICE

40347

DATE

8/11/22





PATIENT

Zaylia Sparks

SPECIES

Canine

BREED

Border Collie X

SEX

Spayed Female

AGE

5 Years

WEIGHT

23.1 kg

INTERPRETED BY

Beth Johnson, DVM
DACVIM

**IMAGING
PERFORMED BY**

Dr. Nigel Gumley

HOSPITAL NAME

Cedarview AH

REFERRING VET

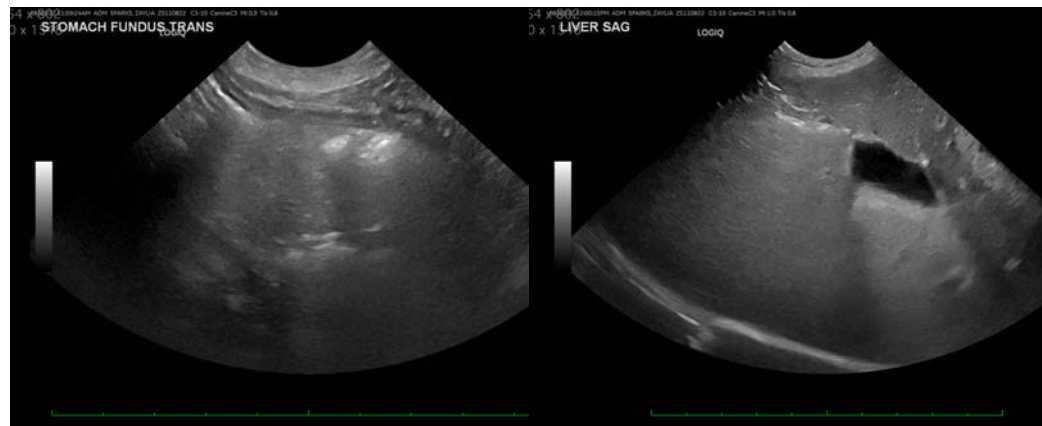
Dr. Nigel Gumley

INVOICE

40347

DATE

8/11/22



The information and recommendations provided are based on the images presented by the referring veterinarian/sonographer. No evaluation can be communicated regarding pathology that was not visible in the image/video clips provided.

Thank you for this referral. If the clinical or image interpretation does not parallel your findings or if I can be of any further assistance please contact me.

Beth Johnson, DVM, DACVIM
Beth.Johnson@sonopath.com