



<b>PATIENT</b>	<b>PRESENTING CLINICAL SIGNS</b>
Socks Sands	History: History of chronic vomiting, worsening in frequency recently. Concern for intestinal mass seen on u/s
<b>SPECIES</b>	<b>ULTRASONOGRAPHIC EXAMINATION OF THE ABDOMEN</b>
Feline	<b>Urinary System</b>
<b>BREED</b>	Urinary bladder is adequately distended. It has a normal uniform wall thickness. Contents include primarily anechoic fluid with occasional echogenic non-shadowing debris, most consistent with incidental suspended lipid in a cat, possibly combined with exfoliated cells, mucous and/or small blood clots. Both sterile inflammation as well as urinary tract infection can also present with echogenic debris. No masses or cystoliths are observed. The trigone and visible pelvic urethra are normal in thickness with a smooth mucosal surface.
Domestic Shorthair	Kidneys are overall normal in size and shape with smooth peripheral margination. A normal 1:3 cortex to medulla ratio is maintained. The medulla and cortices are uniform in texture with some mild increased cortical echogenicity and mild loss of corticomedullary distinction, expected in this age patient. There is no evidence of pyelectasia or infarcts observed. Non-obstructive areas of mineralization/nephroliths are noted bilaterally. The left kidney measured 3.8 cm and the right kidney measured 3.7 cm.
<b>SEX</b>	
Spayed female	
<b>AGE</b>	
11 years	
<b>WEIGHT</b>	<b>Adrenal Glands</b>
10 lbs	Left adrenal gland is normal in size (0.48 cm at cranial pole and 0.39 cm at caudal pole), shape and overall architecture, echogenicity and echotexture. Visible surrounding vasculature appears normal.
<b>INTERPRETED BY</b>	The area of the right adrenal gland is examined without evident pathology.
Beth Johnson, DVM DACVIM	
<b>IMAGING PERFORMED BY</b>	<b>Spleen</b>
Dr. Brady	Spleen is subjectively normal in size with a normal smooth capsular contour. Parenchyma is appropriately finely textured and homogenous with normal echogenicity relative to surrounding tissue (hyperechoic to liver). No focal nodules or masses are observed. Splenic vasculature appears normal.
<b>HOSPITAL NAME</b>	<b>Liver</b>
Shiloh VH	Liver is subjectively normal in size with normal smooth curvilinear peripheral contour. Parenchyma is appropriately hypoechoic to the spleen in echogenicity and appropriately mildly coarse and homogenous in echotexture. No focal lesions are observed. Visible vasculature and biliary tree appear normal without distension or congestion.
<b>REFERRING VET</b>	Gallbladder is non-distended in size. The wall is smooth without visible thickening. Luminal contents are primarily anechoic. There is no evidence of cystic or common bile duct dilation.
Dr. Brady	
<b>INVOICE</b>	
32313	
<b>DATE</b>	
8/11/22	



<b>PATIENT</b>	<b><i>Gastrointestinal</i></b>
Socks Sands	Fundic mucosal hypertrophy with hyperechoic mucosa and some mucosal remodeling is noted. The thickened, hyperechoic, irregular mucosa is most prominent at the level of the pylorus; however, there is no evidence of an obstructive pattern. There is no loss of mural detail. Layering is normal. There is mild luminal fluid accumulation. No evidence of masses/nodules or foreign material present.
<b>SPECIES</b>	
Feline	The visible small intestine demonstrates areas of thick muscularis layer relative to mucosa (disruption of the normal 1:3 muscularis:mucosa ratio). Small intestinal submucosa is slightly irregular, thick and hyperechoic, without evident loss of layering appreciated. The lumen of the small intestine is empty with no evidence of obstruction or foreign material.
<b>BREED</b>	
Domestic Shorthair	The visible colon is normal in wall thickness (< 0.2 cm) and layering. Contents are consistent with normal formed feces and gas.
<b>SEX</b>	
Spayed female	<b><i>Pancreas</i></b>
<b>AGE</b>	The observed pancreas appears appropriately isoechoic to surrounding omental fat. The capsule is mildly irregular in shape. Parenchyma is mildly heterogenous and coarse. There is no visible pancreatic duct dilation. There is no evidence of active peripancreatic inflammation.
11 years	
<b>WEIGHT</b>	<b><i>Free Abdomen</i></b>
10 lbs	There is no evidence of free peritoneal effusion noted in these images.
	There is no apparent lymphadenopathy noted in these images.
<b>INTERPRETED BY</b>	
Beth Johnson, DVM DACVIM	<b>ULTRASONOGRAPHIC FINDINGS</b>
<b>IMAGING PERFORMED BY</b>	<b>Primary Findings</b>
Dr. Brady	<ul style="list-style-type: none"> <li>• <b>Inflammatory bowel disease (IBD) pattern</b> – Thick muscularis has been reported with infiltrative bowel disease including both benign inflammatory disease as well as infiltrative neoplasia such as lymphoma. No aggressive lymphadenopathy, loss of layering, etc. is noted to make lymphoma more probable, but lymphoma cannot be definitively ruled out without tissue sampling.</li> <li>• <b>Gastritis</b> – Consistent with irritation secondary to dietary indiscretion or intolerance, infection (bacterial, viral, other), parasitic or protozoal disease, toxin, other metabolic disease such as pancreatitis, other. Microulceration cannot be ruled out.</li> <li>• <b>Pancreatic age-related remodeling</b> – Mild irregularities are consistent with benign age-related change. Low-grade smoldering chronic pancreatitis cannot be ruled out and should be suspected in the face of appropriate clinical signs. Chronic smoldering pancreatitis cannot be ruled out.</li> </ul>
<b>HOSPITAL NAME</b>	
Shiloh VH	
<b>REFERRING VET</b>	
Dr. Brady	
<b>INVOICE</b>	<b>Secondary Findings</b>
32313	<ul style="list-style-type: none"> <li>• <b>Urinary bladder debris.</b></li> <li>• <b>Age related renal changes with non-obstructive nephrolithiasis.</b></li> </ul>
<b>DATE</b>	
8/11/22	



**PATIENT**

Socks Sands

**SPECIES**

Feline

**BREED**

Domestic Shorthair

**SEX**

Spayed female

**AGE**

11 years

**WEIGHT**

10 lbs

**INTERPRETED BY**

Beth Johnson, DVM  
DACVIM

**IMAGING PERFORMED BY**

Dr. Brady

**HOSPITAL NAME**

Shiloh VH

**REFERRING VET**

Dr. Brady

**INVOICE**

32313

**DATE**

8/11/22

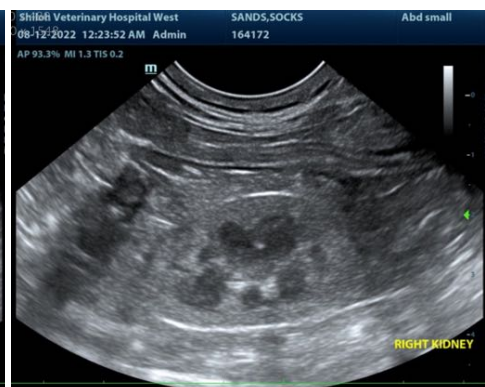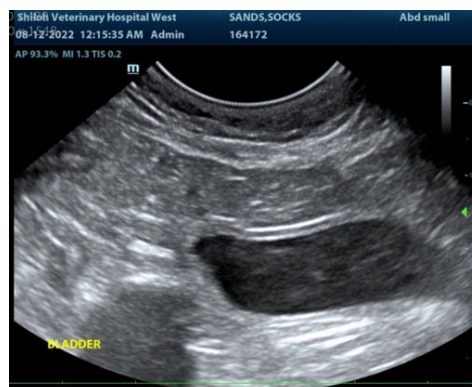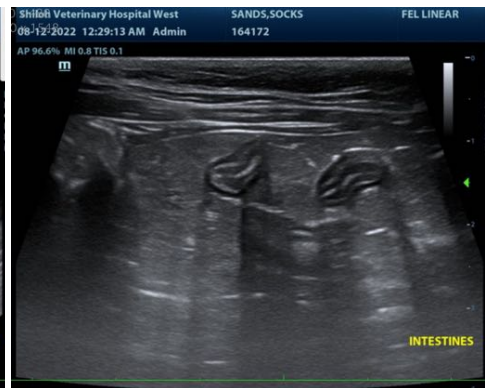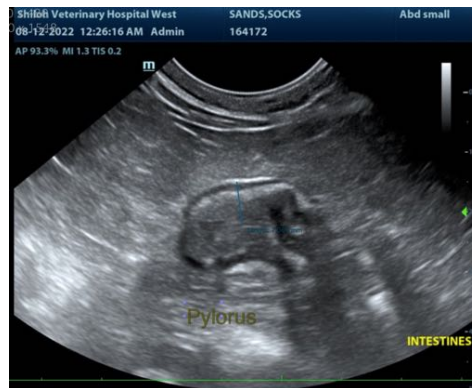**INTERPRETATION OF THE FINDINGS & FURTHER RECOMMENDATIONS**

A gastrointestinal malabsorption panel (including cobalamin, folate, TLI and PLI) to Texas A&M GI Laboratory is recommended for further evaluation of GI and pancreatic function.

Ideally, biopsies of the GI tract, being sure to include ileum if possible, are recommended to definitively diagnose and therefore manage the infiltrative bowel disease.

If biopsies cannot be obtained, empirical therapies could include diet change, empirical deworming with a 5 day course of Panacur, cobalamin supplementation (unless cobalamin level is evaluated and supplementation is not warranted) and prednisolone (if not contraindicated based on patient contraindications, co-morbidities, etc.).

Urinalysis and, if indicated based on urinalysis results, urine culture are recommended. If protein is present in an otherwise quiet sediment, protein quantification with a urine protein to creatinine ration is recommended.





**PATIENT**

Socks Sands

**SPECIES**

Feline

**BREED**

Domestic Shorthair

**SEX**

Spayed female

**AGE**

11 years

**WEIGHT**

10 lbs

**INTERPRETED BY**

Beth Johnson, DVM  
DACVIM

**IMAGING PERFORMED BY**

Dr. Brady

**HOSPITAL NAME**

Shiloh VH

**REFERRING VET**

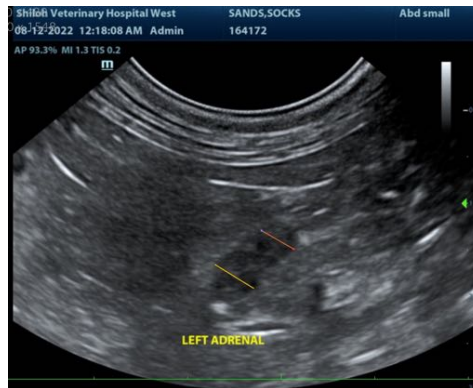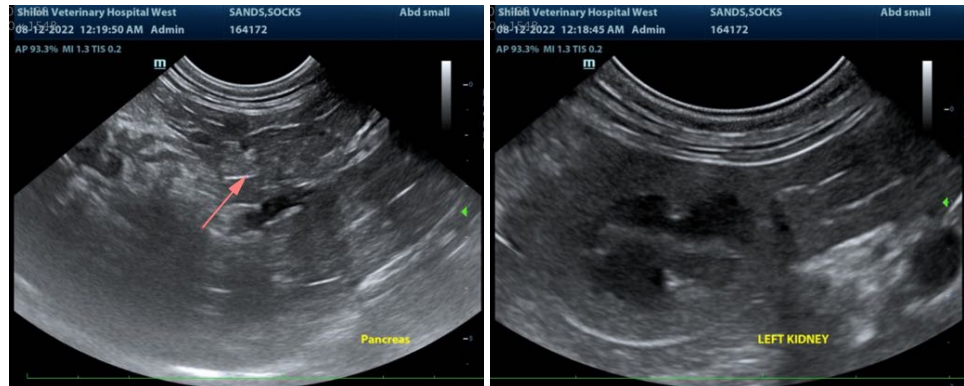
Dr. Brady

**INVOICE**

32313

**DATE**

8/11/22



The information and recommendations provided are based on the images presented by the referring veterinarian/sonographer. No evaluation can be communicated regarding pathology that was not visible in the image/video clips provided.

Thank you for this referral. If the clinical or image interpretation does not parallel your findings or if I can be of any further assistance please contact me.

**Beth Johnson, DVM DACVIM**

Beth.Johnson@SonoPath.com