**DATE**

8/10/2023

PRESENTING CLINICAL SIGNS**PATIENT**

Chronic intermittent diarrhea.

Paulanka
Brown**SPECIES**

Canine

BREEDLabrador
Retriever**SEX**

Spayed Female

AGE

3/22/2022

WEIGHT

58lbs

**INTERPRETED
BY**Beth Johnson,
DVM DACVIM**HOSPITAL
NAME**

Fullerton AH

**REFERRING
VET**

Dr. Unger

INVOICE

10408

Current Medications: Probiotic, Oral cobalamin
Lab Results: Campylobacter positive, slightly decreased cobalamin level, No ova or parasites in last fecal Aug 2022. No response to Panacur trial. On Purina HA, had one good month now back to diarrhea. Goes to doggy day care regularly. Last CBC/mini chem at time of spay in Oct 2022, mild leukocytosis due to lymphocytosis and mild monocytosis.
Date of Previous IntraPet Ultrasound: No previous.
Sedation: Torbugesic IV.
Stat Report: Not requested.
Imaging Performed By: Stephanie Warga RDCS, RVT.

ULTRASONOGRAPHIC EXAMINATION OF THE ABDOMEN**Urinary System**

The urinary bladder is moderately distended with anechoic contents. No masses, inflammatory changes, echogenic sediment or cystoliths are observed. The urinary bladder, trigone and visible pelvic urethra are normal in thickness with a smooth mucosal surface.

The right kidney is normal in size (5.74 cm), shape and echogenicity. It has smooth peripheral margination. There is a normal 1:3 cortex to medulla ratio with appropriate corticomedullary distinction. There is no evidence of pyelectasia, mineral or infarcts observed.

The left kidney is normal in size (5.53 cm), shape and echogenicity. It has smooth peripheral margination. There is a normal 1:3 cortex to medulla ratio with appropriate corticomedullary distinction. There is no evidence of pyelectasia, mineral or infarcts observed.

Adrenal Glands

The right adrenal gland is normal in size (cranial 0.68 cm, caudal 0.51 cm), shape and contour. Corticomedullary structure is unremarkable. Visible surrounding vasculature appears normal.

The left adrenal gland is normal in size (cranial 0.43 cm, caudal 0.46 cm), shape and contour. Corticomedullary structure is unremarkable. Visible surrounding vasculature appears normal.

Spleen

The spleen is subjectively normal in size with a normal smooth capsular contour. Parenchyma is appropriately finely textured and homogenous with normal echogenicity relative to surrounding tissue (hyperechoic to liver). No focal nodules or masses are observed. Splenic vasculature appears normal.

Liver

The liver is subjectively mildly small in size with normal smooth curvilinear peripheral contour. Parenchyma is appropriately hypoechoic to the spleen in echogenicity and appropriately mildly coarse and homogenous in echotexture. No focal lesions are observed. Visible vasculature and biliary tree appear normal without distension or congestion.

The gallbladder is non-distended in size. The wall is smooth without visible thickening. Luminal contents are primarily anechoic. There is no evidence of cystic or common bile duct dilation.

Gastrointestinal

The visible stomach wall is normal in thickness and layering. The lumen of the stomach is mildly distended with very echogenic reverberation artifact from intraluminal gas. There is no evidence of obstruction, foreign material, or infiltrative disease; however, complete visualization of far wall is partially inhibited by gas. Pyloric outflow tract appears patent.

The visible small intestines are normal in wall thickness and layering (canine duodenum < 0.5 cm and feline duodenum < 0.4 cm; other < 0.3 cm). Small intestinal motility appears adequate (1-3 contractions per min). The lumen of the small intestine is empty with no evidence of obstruction or foreign material.

The visible colon is normal in wall thickness (< 0.2 cm) and layering. Contents are consistent with normal formed feces and gas.

Pancreas

The pancreatic parenchyma is appropriately isoechoic to surrounding tissue. Visible capsule is smooth and normal in contour. There is no visible pancreatic duct dilation. There is no evidence of active peripancreatic inflammation.

Free Abdomen

There is no evidence of free peritoneal effusion noted in these images.

The medial iliac lymph nodes are prominent in size with swollen capsular contour. Normal elongated shape (length to width ratio) is maintained. There is no loss of parenchymal detail. Additionally, mesenteric lymph nodes are noted to be enlarged with swollen irregular capsular contour. Emerging rounded shape and are hypoechoic and possibly partially cystic.

ULTRASONOGRAPHIC FINDINGS

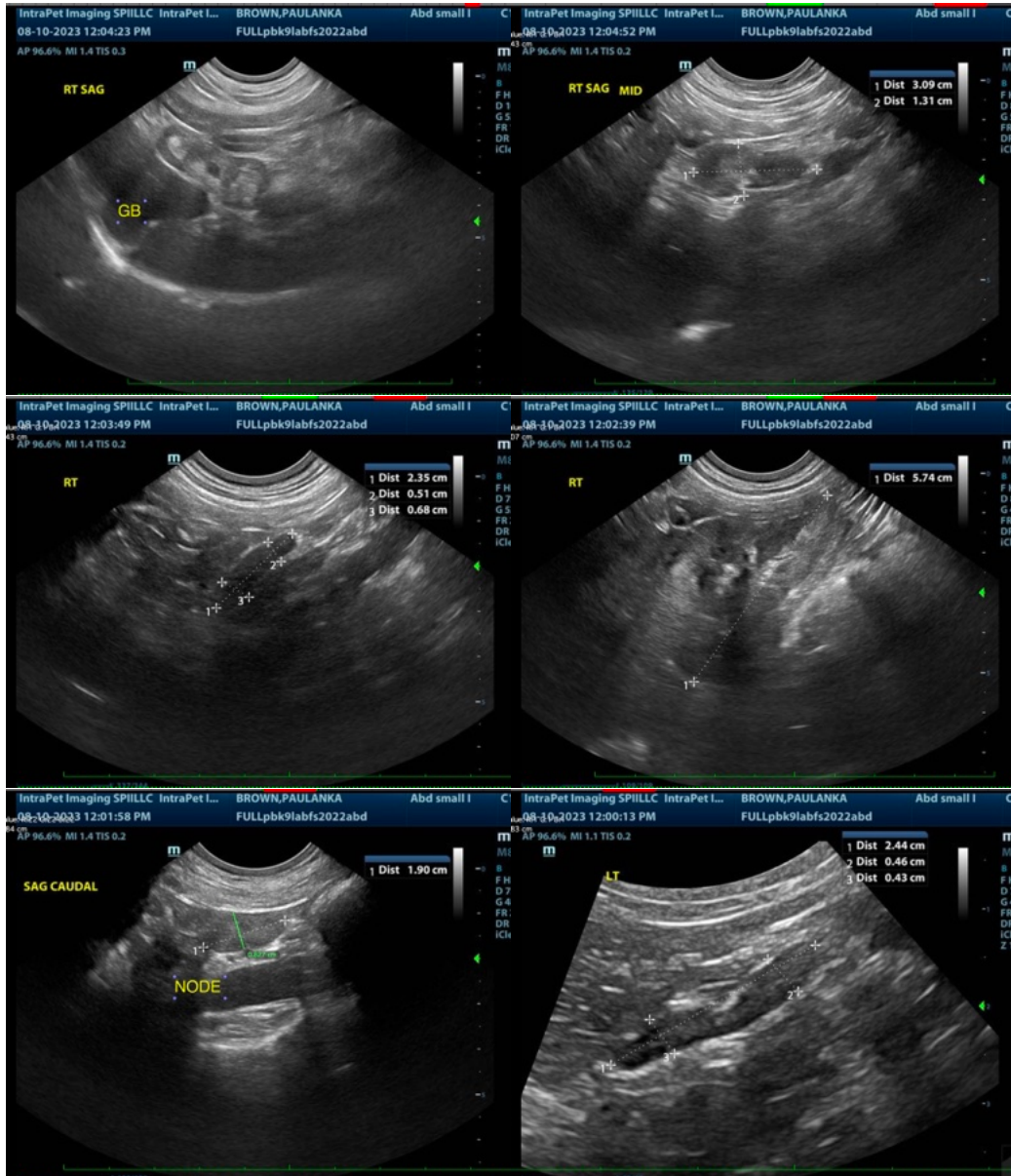
- Subjectively mild micro hepatica, most likely normal patient variant. However, liver disease and or even less likely vascular anomaly can't be definitively ruled out.
- Medial iliac and mesenteric lymphadenopathy is most likely reactive. However, especially given the more atypical appearance of the mesenteric lymph nodes and a benign aggressive inflammatory response secondary to infectious disease or even less likely infiltrative neoplasia while considered much less likely cannot be definitively ruled out.

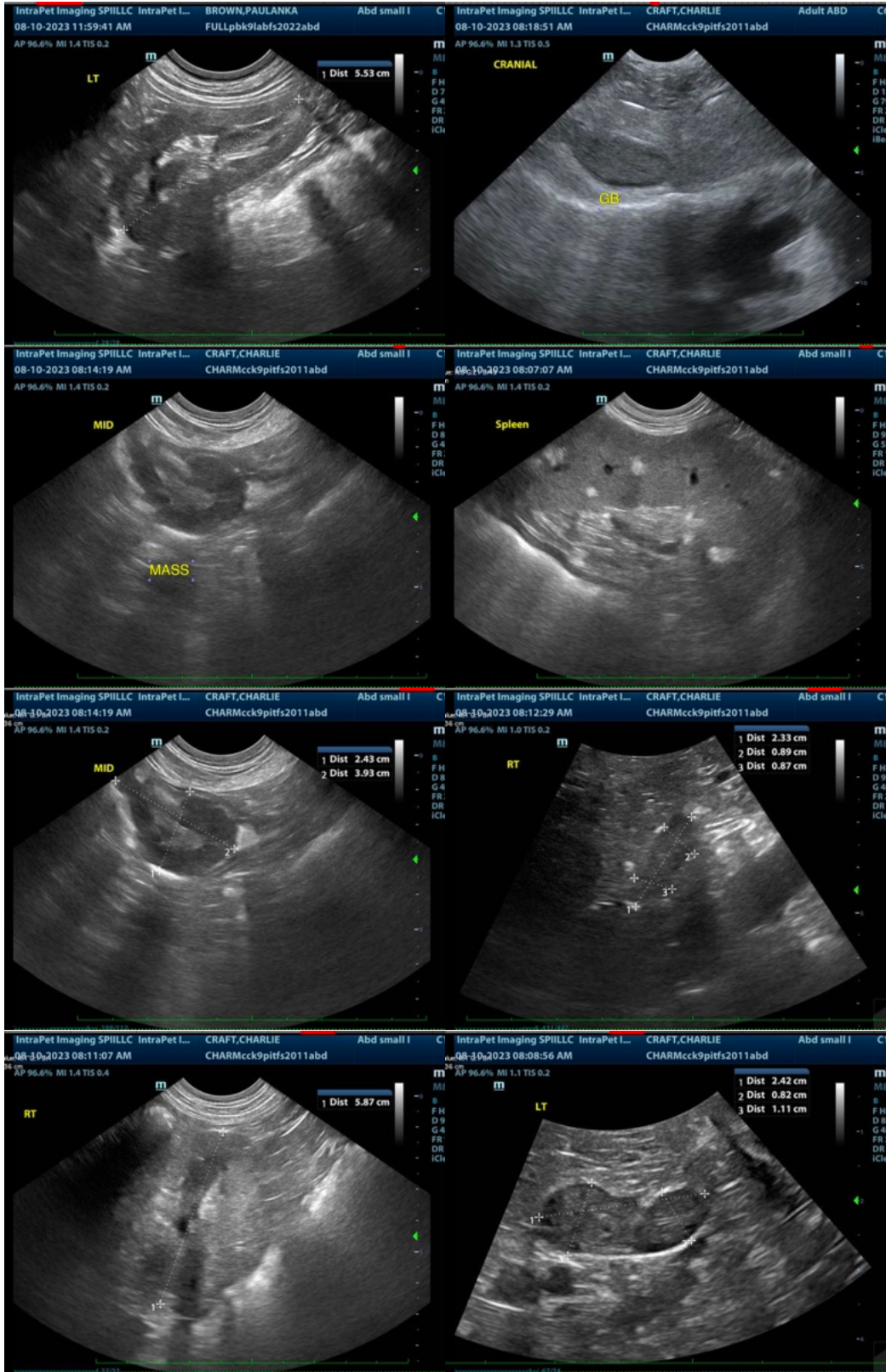
INTERPRETATION OF THE FINDINGS & FURTHER RECOMMENDATIONS

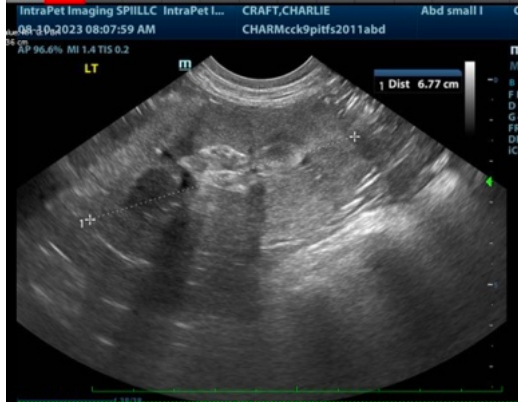Close history is recommended if not already evaluated to ensure that this is not consuming any variety of raw diet. Given patients regular to exposure to doggie daycare a recheck general metabolic health screen and fecal exam could be considered as well as redosing of a 5-day course of Panacur despite fecal results.

While many campylobacter infections are mild in self-limiting, given this patients on going diarrhea a therapeutic course of Tylosin could be considered while maintaining the hydrolyzed protein diet reportedly already in place as well as a probiotic such as Visbiome or Provable. Pending results of that however given the reported low cobalamin, underlying infiltrative possibly inflammatory bowel disease could be present and have helped contribute to the campylobacter infection and ultimately if patients clinical signs are ongoing gastrointestinal biopsies may be necessary. Prior to pursuing more invasive biopsies in some patients fecal transplant could be helpful.

Finally, while the appearance of the liver is most likely normal patient variant, bile acid testing could be considered to be safe.







The information and recommendations provided are based on the images presented by the referring veterinarian/sonographer. No evaluation can be communicated regarding pathology that was not visible in the image/video clips provided.

Thank you for this referral. If the clinical or image interpretation does not parallel your findings or if I can be of any further assistance, please contact me.

Beth Johnson, DVM, DACVIM
info@sonopath.com