

**DATE PRESENTING CLINICAL SIGNS**

8/10/22

P presented for not eating well on 8/2/22. During examination, effusion noted in the abdomen. Fluid cytology sent to Idexx :ADDITIONAL INFORMATION: Proteins: Less than 2.0 g/L., RBC: Less than 0.10 x 10<sup>12</sup> cells/L (less than 100,000 cells/μL), WBC: 1.43 x 10<sup>9</sup> cells/L (1,430 cells/μL). MICROSCOPIC DESCRIPTION: Cellularity is low, with similar numbers of small lymphocytes and non-degenerate neutrophils and much rarer macrophages and mesothelial cells. No infectious agents or atypical cells are seen. P still eating but not a lot, started the p on abx (convenia and entyce) on 8/5/22.

**SPECIES**

Feline

Current Medications: Convenia injection, Entyce

Lab Results: See attached.

Date of Previous IntraPet Ultrasound: No previous.

**BREED**

Sedation: Not required to complete full diagnostic ultrasound.

Stat Report: Not requested.

DLH

**ULTRASONOGRAPHIC EXAMINATION OF THE ABDOMEN****SEX**

Spayed Female

**Urinary System**

The urinary bladder is moderately distended with anechoic contents. No masses, inflammatory changes, echogenic sediment or cystoliths are observed. The urinary bladder, trigone and visible pelvic urethra are normal in thickness with a smooth mucosal surface.

**AGE**

5/12/16

The right kidney is normal in size (3.29 cm), shape and echogenicity. It has smooth peripheral margination. There is a normal 1:3 cortex to medulla ratio with appropriate corticomedullary distinction. There is no evidence of pyelectasia, mineral or infarcts observed.

**WEIGHT**

6.42 Pounds

The left kidney is normal in size (3.2 cm), shape and echogenicity. It has smooth peripheral margination. There is a normal 1:3 cortex to medulla ratio with appropriate corticomedullary distinction. There is no evidence of pyelectasia, mineral or infarcts observed.

**INTERPRETED BY**Beth Johnson, DVM  
DACVIM**Adrenal Glands**

The right adrenal gland is normal in size (0.31 cm), shape and contour. Corticomedullary structure is unremarkable. Visible surrounding vasculature appears normal.

**IMAGING PERFORMED BY**

Rachel Brilhart RDMS

The left adrenal gland is normal in size (0.41 cm), shape and contour. Corticomedullary structure is unremarkable. Visible surrounding vasculature appears normal.

**HOSPITAL NAME**

Northwind AH

**Spleen**

Spleen is subjectively large in size with subtly scalloped or undulating capsular contour. Parenchyma is normal in echogenicity with a mildly coarse/heterogenous echotexture. No focal nodules or masses are observed. Splenic vasculature appears normal.

**REFERRING VET**

Dr. Jones

**Liver**

The liver is subjectively normal in size with normal smooth curvilinear peripheral contour. Parenchyma is appropriately hypoechoic to the spleen in echogenicity and appropriately mildly coarse and homogenous in echotexture. No focal lesions are observed. Visible vasculature and biliary tree appear normal without distension or congestion.

**INVOICE**

40307

The gallbladder is non-distended in size. The wall is smooth without visible thickening. Luminal contents are primarily anechoic. There is no evidence of cystic or common bile duct dilation.

### ***Gastrointestinal***

The stomach reveals a diffuse loss of normal layering, characterized by hypoechoic 1.5 cm thick, irregular wall in the area of the pylorus/antrum. The remainder of the gastric wall, body, fundus, etc. appears more normal, and the stomach is empty.

The visible small intestine demonstrates areas of thick muscularis layer relative to mucosa (disruption of the normal 1:3 muscularis:mucosa ratio). Small intestinal submucosa is slightly irregular, thick and hyperechoic, without evident loss of layering appreciated. The lumen is empty with no evidence of obstruction or foreign material.

The visible colon is normal in wall thickness (< 0.2 cm) and layering. Contents are consistent with normal formed feces and gas.

### ***Pancreas***

The pancreatic parenchyma is appropriately isoechoic to surrounding tissue. Visible capsule is smooth and normal in contour. There is no visible pancreatic duct dilation. There is no evidence of active peripancreatic inflammation.

### ***Free Abdomen***

There is a large amount of anechoic free fluid present.

Mesenteric lymph nodes are enlarged.

## **ULTRASONOGRAPHIC FINDINGS**

- **Gastric mass in the area of the pyloric antrum** – most concerning for infiltrative neoplasia with round cell neoplasia being a top differential.
- **Concurrent gastrointestinal lymphoma (suspect) pattern in the remaining small bowel** – Thick muscularis has been reported with infiltrative bowel disease including both benign inflammatory disease as well as infiltrative neoplasia such as lymphoma. Given the concurrent pathology noted, infiltrative neoplasia is considered more likely, but benign IBD cannot be ruled out without tissue sampling.
- **Scalloped spleen** – can be associated with benign or malignant infiltrative disease. Common causes include a reactive spleen secondary to immune stimulus or early infiltrative round cell neoplasia such as lymphoma or mast cell tumor.
- Mesenteric lymphadenopathy and free fluid.

## **INTERPRETATION OF THE FINDINGS & FURTHER RECOMMENDATIONS**

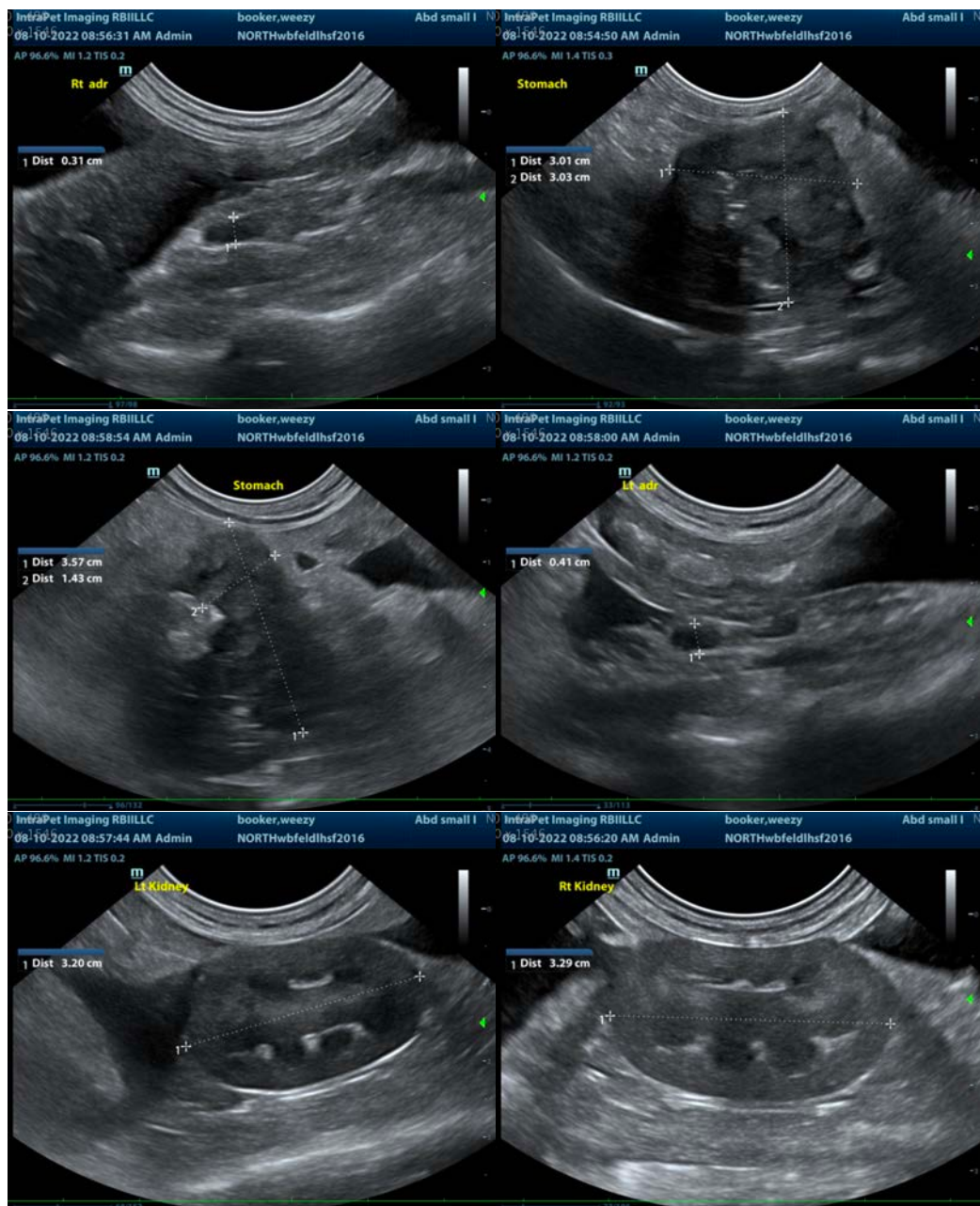
Recommendations include a fine needle aspirate of the gastric mass if patient's coagulation status is appropriate for further investigation of suspect round cell neoplasia.

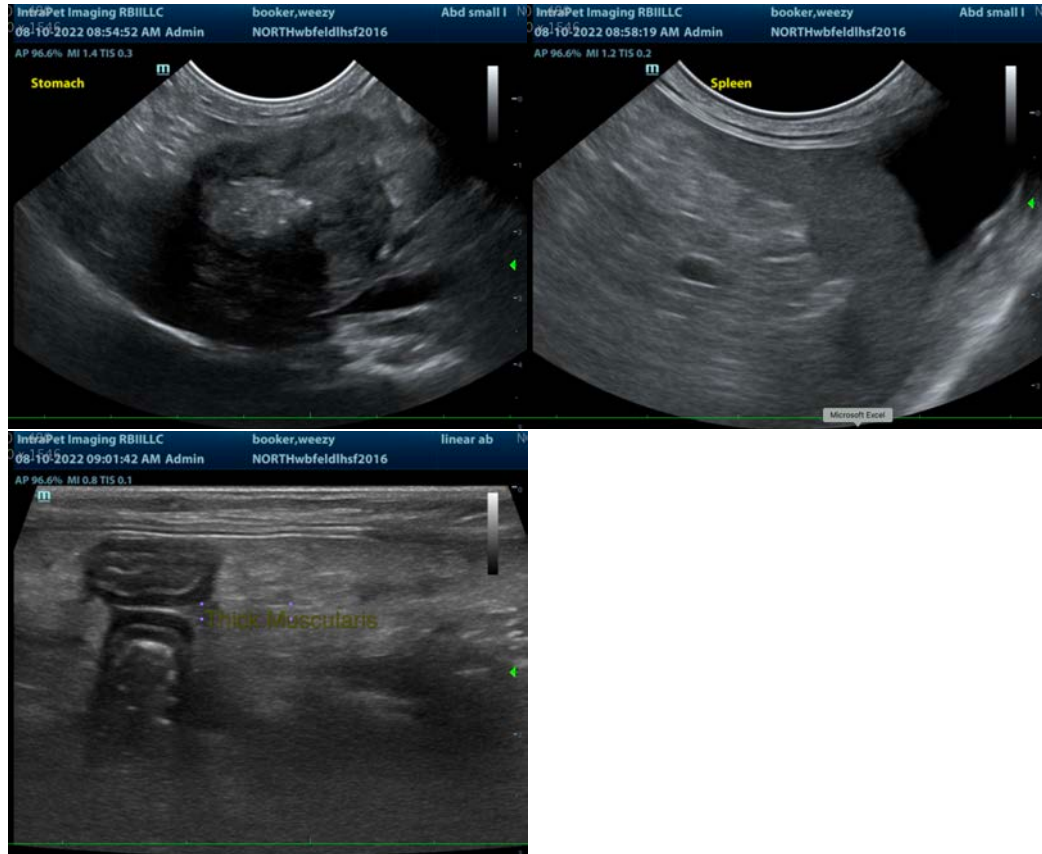
A gastrointestinal malabsorption panel (including cobalamin, folate, TLI and PLI) to Texas A&M GI Laboratory is recommended for further evaluation of GI and pancreatic function.

The resectability of the gastric mass is questionable based on these images, given the presumed location. However, if a cytologic diagnosis cannot be obtained, an exploratory laparotomy would be recommended for excisional biopsy of the gastric mass as well as full thickness of the bowel.

The reported hyperalbuminemia is likely secondary to gastrointestinal loss. However, evaluation of the urine is recommended with urinalysis and, if indicated based on urinalysis results, urine culture. If protein is present in an otherwise quiet sediment, protein quantification with a urine protein to creatinine ration is recommended.

Ultimately, if biopsies or further diagnostics cannot be obtained, empirical therapies could include empirical deworming with a 5-day course of Panacur, cobalamin supplementation (unless cobalamin level is evaluated and supplementation is not warranted), and Prednisolone (if not contraindicated based on patient contraindications, comorbidities, etc.).





The information and recommendations provided are based on the images presented by the referring veterinarian/sonographer. No evaluation can be communicated regarding pathology that was not visible in the image/video clips provided.

Thank you for this referral. If the clinical or image interpretation does not parallel your findings or if I can be of any further assistance please contact me.

**Beth Johnson, DVM, DACVIM**  
Beth.Johnson@sonopath.com