



PATIENT	PRESENTING CLINICAL SIGNS
Patch Chalker	History: Intermittent vomiting, weight loss 1y Abnormal PE/Chem/CBC/UA Results: Mild leukocytosis, elevated fpL, mid increase proBNP
SPECIES	ULTRASONOGRAPHIC EXAMINATION OF THE ABDOMEN
Feline	Urinary System
BREED	Urinary bladder is adequately distended. It has a normal uniform wall thickness. Contents include primarily anechoic fluid with occasional echogenic non-shadowing debris, most consistent with incidental suspended lipid in a cat, possibly combined with exfoliated cells, mucous and/or small blood clots. Both sterile inflammation as well as urinary tract infection can also present with echogenic debris. No masses or cystoliths are observed. The trigone and visible pelvic urethra are normal in thickness with a smooth mucosal surface.
Ragdoll	
SEX	
Spayed female	Left kidney is normal is size (4.0 cm), shape and echogenicity. It has smooth peripheral margination. There is a normal 1:3 cortex to medulla ratio with appropriate corticomedullary distinction. There is no evidence of pyelectasia, mineral or infarcts observed.
AGE	
10 years	Right kidney is normal is size (3.6 cm), shape and echogenicity. It has smooth peripheral margination. There is a normal 1:3 cortex to medulla ratio with appropriate corticomedullary distinction. There is no evidence of pyelectasia, mineral or infarcts observed.
WEIGHT	
7.8 lbs	Adrenal Glands
INTERPRETED BY	Left adrenal gland is normal in size (0.3 cm), shape and overall architecture, echogenicity and echotexture. Visible surrounding vasculature appears normal.
Beth Johnson, DVM DACVIM	Right adrenal gland is normal in size (0.27 cm), shape and overall architecture, echogenicity and echotexture. Visible surrounding vasculature appears normal.
IMAGING PERFORMED BY	Spleen
Dr. Wiley	Spleen is subjectively normal in size with a normal smooth capsular contour. Parenchyma is appropriately finely textured and homogenous with normal echogenicity relative to surrounding tissue (hyperechoic to liver). No focal nodules or masses are observed. Splenic vasculature appears normal.
HOSPITAL NAME	
Petvacx AH	Liver
REFERRING VET	Liver is subjectively normal in size with normal smooth curvilinear peripheral contour. Parenchyma is appropriately hypoechoic to the spleen in echogenicity and appropriately mildly coarse and homogenous in echotexture. No focal lesions are observed. Visible vasculature and biliary tree appear normal without distension or congestion.
Dr. Wiley	
INVOICE	Gallbladder is non-distended in size. The wall is smooth without visible thickening. Luminal contents are primarily anechoic. There is no evidence of cystic or common bile duct dilation.
32281	
DATE	
8/9/22	



PATIENT *Gastrointestinal*

Patch Chalker The visible stomach wall is normal in thickness and layering. The lumen of the stomach is empty with no evidence of obstruction, foreign material or infiltrative disease. Pyloric outflow tract appears patent.

SPECIES The visible small intestine demonstrates areas of thick muscularis layer relative to mucosa (disruption of the normal 1:3 muscularis:mucosa ratio). Small intestinal submucosa is slightly irregular, thick and hyperechoic, without evident loss of layering appreciated. The lumen of the small intestine is empty with no evidence of obstruction or foreign material.

Feline

BREED The visible colon is normal in wall thickness (< 0.2 cm) and layering. Contents are consistent with normal formed feces and gas.

Ragdoll

SEX *Pancreas*

Spayed female Pancreas is prominent (enlarged) in size, hypoechoic to surrounding tissue and has a mildly irregular undulating contour. Parenchyma is coarse with mixed echogenic remodeling noted. Pancreatic duct dilation is noted.

AGE

10 years

Free Abdomen

WEIGHT There is no evidence of free peritoneal effusion noted in these images.

7.8 lbs

There is no apparent lymphadenopathy noted in these images.

INTERPRETED BY

Beth Johnson, DVM
DACVIM

ULTRASONOGRAPHIC FINDINGS

Primary Findings

- **Inflammatory bowel disease (IBD) pattern** – Thick muscularis has been reported with infiltrative bowel disease including both benign inflammatory disease as well as infiltrative neoplasia such as lymphoma. No aggressive lymphadenopathy, loss of layering, etc. is noted to make lymphoma more probable, but lymphoma cannot be definitively ruled out without tissue sampling.
- **Chronic active pancreatitis.**

IMAGING PERFORMED BY

Dr. Wiley

Secondary Findings

- **Urinary bladder debris.**

HOSPITAL NAME

Petvacx AH

REFERRING VET

Dr. Wiley

INTERPRETATION OF THE FINDINGS & FURTHER RECOMMENDATIONS

INVOICE

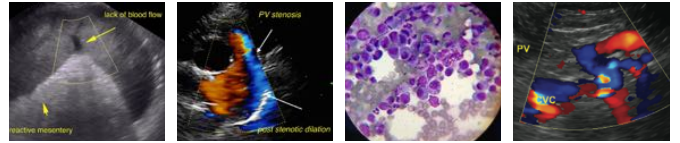
32281

1. A gastrointestinal malabsorption panel (including cobalamin, folate, TLI and PLI) to Texas A&M GI Laboratory is recommended for further evaluation of GI and pancreatic function.

DATE

8/9/22

Ideally, biopsies of the GI tract, being sure to include ileum if possible, are recommended to definitively diagnose and therefore manage the infiltrative bowel disease.



PATIENT

Patch Chalker

If biopsies cannot be obtained, empirical therapies could include diet change, empirical deworming with a 5 day course of Panacur, cobalamin supplementation (unless cobalamin level is evaluated and supplementation is not warranted) and prednisolone (if not contraindicated based on patient contraindications, co-morbidities, etc.).

SPECIES

Feline

- Urinalysis and, if indicated based on urinalysis results, urine culture are recommended. If protein is present in an otherwise quiet sediment, protein quantification with a urine protein to creatinine ration is recommended.

BREED

Ragdoll

SEX

Spayed female

AGE

10 years

WEIGHT

7.8 lbs

INTERPRETED BY

Beth Johnson, DVM
DACVIM

IMAGING PERFORMED BY

Dr. Wiley

HOSPITAL NAME

Petvacx AH

REFERRING VET

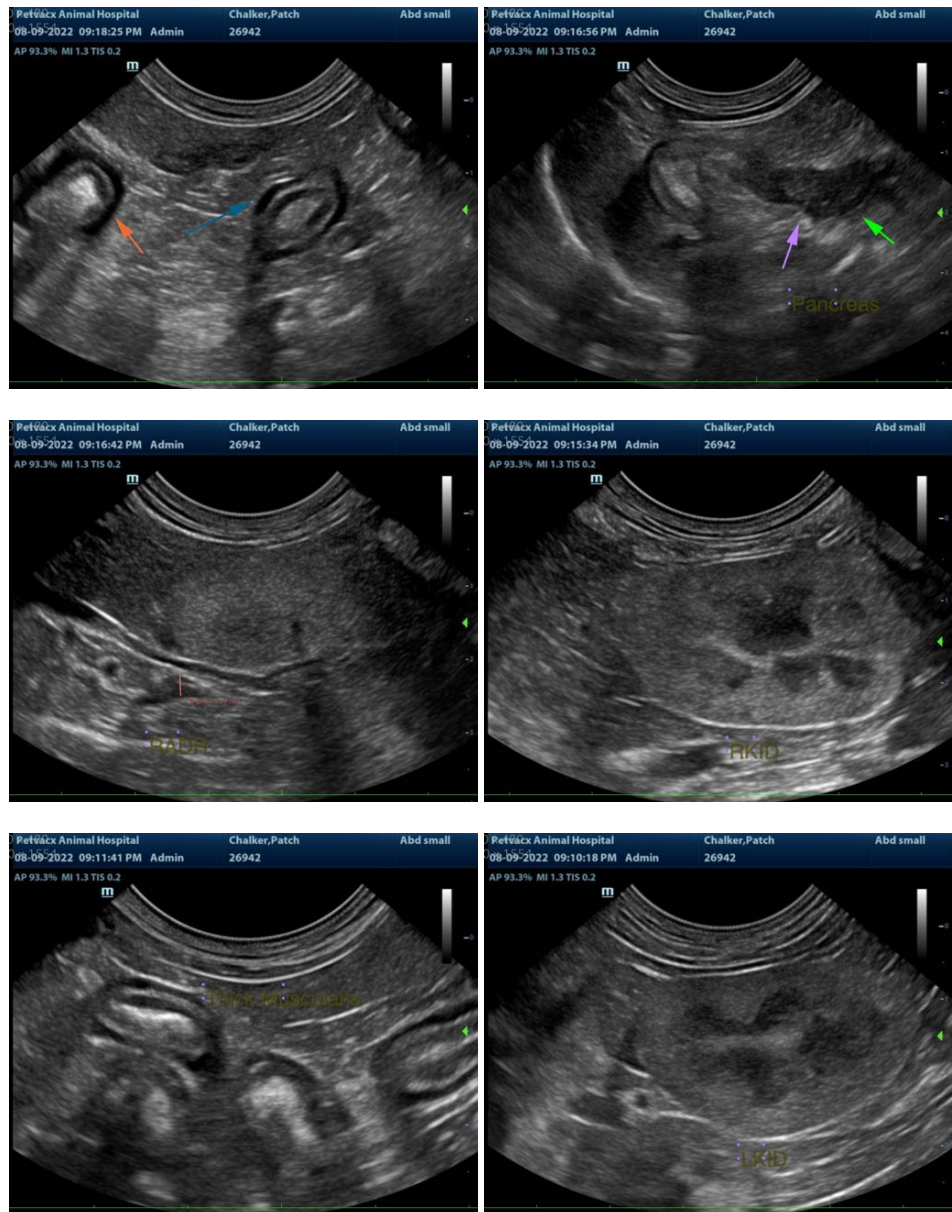
Dr. Wiley

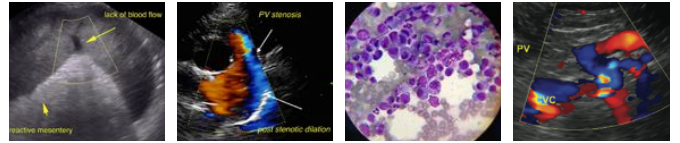
INVOICE

32281

DATE

8/9/22





PATIENT

Patch Chalker

SPECIES

Feline

BREED

Ragdoll

SEX

Spayed female

AGE

10 years

WEIGHT

7.8 lbs

INTERPRETED BY

Beth Johnson, DVM
DACVIM

IMAGING PERFORMED BY

Dr. Wiley

HOSPITAL NAME

Petvacx AH

REFERRING VET

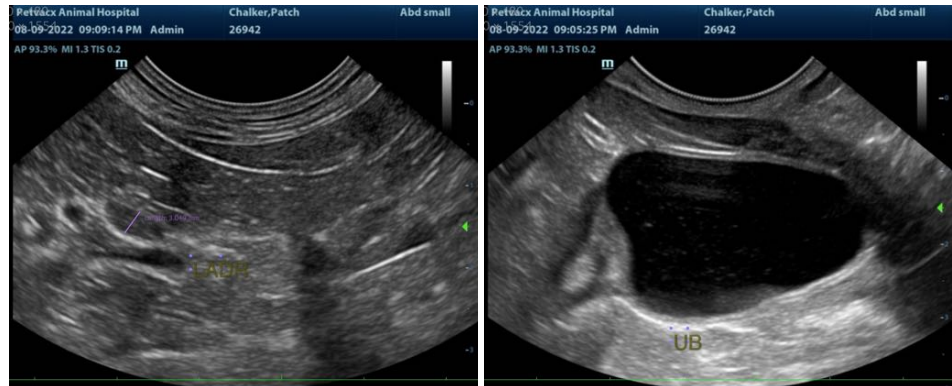Dr. Wiley

INVOICE

32281

DATE

8/9/22



The information and recommendations provided are based on the images presented by the referring veterinarian/sonographer. No evaluation can be communicated regarding pathology that was not visible in the image/video clips provided.

Thank you for this referral. If the clinical or image interpretation does not parallel your findings or if I can be of any further assistance please contact me.

Beth Johnson, DVM DACVIM

Beth.Johnson@SonoPath.com