



**PATIENT**

Nacho Velazquez-Naranjo

**SPECIES**

Canine

**BREED**

Boston Terrier

**SEX**

Neutered Male

**AGE**

7 Years

**WEIGHT**

32 Pounds

**INTERPRETED BY**

Beth Johnson, DVM  
DACVIM

**IMAGING PERFORMED BY**

Dr. Jack Reese

**HOSPITAL NAME**

Willow Run VC

**REFERRING VET**

Dr. Anna Leppian

**INVOICE**

40325

**DATE**

8/10/22

**PRESENTING CLINICAL SIGNS**

Chronic history of liver enzyme elevation. U/S 2 years ago revealed non-specific hepatopathy changes. P doing well, managed on Denamarin long-term.

Abnormal PE/Chem/CBC/UA Results: Chem: ALP - 1894 (5-160) \* was 1262

**ULTRASONOGRAPHIC EXAMINATION OF THE ABDOMEN**

**Urinary System**

The urinary bladder is moderately distended with anechoic contents. No masses, inflammatory changes, echogenic sediment or cystoliths are observed. The urinary bladder, trigone and visible pelvic urethra are normal in thickness with a smooth mucosal surface.

Prostate is normal in size, echotexture and echogenicity for a neutered male.

The right kidney is normal in size (5.47 cm), shape and echogenicity. It has smooth peripheral margination. There is a normal 1:3 cortex to medulla ratio with appropriate corticomedullary distinction. There is no evidence of pyelectasia, mineral or infarcts observed.

The left kidney is normal in size (5.36 cm), shape and echogenicity. It has smooth peripheral margination. There is a normal 1:3 cortex to medulla ratio with appropriate corticomedullary distinction. There is no evidence of pyelectasia, mineral or infarcts observed.

**Adrenal Glands**

The right adrenal gland is normal in size (0.90 cm at the cranial pole and 0.65 cm at the caudal pole), shape and contour. Corticomedullary structure is unremarkable. Visible surrounding vasculature appears normal.

The left adrenal gland is normal in size (0.59 cm at the cranial pole and 0.67 cm at the caudal pole), shape and contour. Corticomedullary structure is unremarkable. Visible surrounding vasculature appears normal.

**Spleen**

The spleen is subjectively normal in size with a normal smooth capsular contour. Parenchyma is appropriately finely textured and homogenous with normal echogenicity relative to surrounding tissue (hyperechoic to liver). No focal nodules or masses are observed. Splenic vasculature appears normal.

**Liver**

The liver is subjectively normal in size with normal smooth curvilinear peripheral contour. Parenchyma is appropriately hypoechoic to the spleen in echogenicity and appropriately mildly coarse and homogenous in echotexture. No focal lesions are observed. Visible vasculature and biliary tree appear normal without distension or congestion.

Gallbladder is moderately distended with anechoic bile as well as suspended and gravity dependent echogenic debris. The wall is smooth without visible thickening. There is no evidence of cystic or CBD dilation. There is no evidence of effusion or inflammation.

**Gastrointestinal**

The stomach wall is normal in thickness (canine < 0.5 cm and feline < 0.4 cm) and layering. The lumen of the stomach is empty with no evidence of obstruction, foreign material or infiltrative disease. Pyloric outflow tract appears patent.



**PATIENT**

Nacho Velazquez-Naranjo

The visible small intestines are normal in wall thickness and layering (canine duodenum < 0.5 cm and feline duodenum < 0.4 cm; other < 0.3 cm). Small intestinal motility appears adequate (1-3 contractions per min). The lumen of the small intestine is empty with no evidence of obstruction, foreign material or infiltrative disease.

**SPECIES**

Canine

The visible colon is normal in wall thickness (< 0.2 cm) and layering. Contents are consistent with normal formed feces and gas.

**Pancreas**

**BREED**

Boston Terrier

The pancreatic parenchyma is appropriately isoechoic to surrounding tissue. Visible capsule is smooth and normal in contour. There is no visible pancreatic duct dilation. There is no evidence of active peripancreatic inflammation.

**SEX**

Neutered Male

**Free Abdomen**

There is no evidence of free peritoneal effusion noted in these images.

There is no apparent lymphadenopathy noted in these images.

**AGE**

7 Years

**ULTRASONOGRAPHIC FINDINGS**

**WEIGHT**

32 Pounds

- **Gallbladder debris** - Cholecystic debris is of unknown clinical significance. It can be seen with biliary stasis from fasting or illness. Cholecystic debris is not necessarily related to hepatobiliary disease. Echogenic bile is most commonly an incidental finding in dogs and should be interpreted in combination with clinical signs such as nausea, inappetence, cranial abdominal discomfort and/or laboratory changes such as increased ALP and/or increased Tbili.
- Otherwise, normal/unremarkable abdomen

**INTERPRETED BY**

Beth Johnson, DVM  
DACVIM

**INTERPRETATION OF THE FINDINGS & FURTHER RECOMMENDATIONS**

Differentials are vast and non-specific. Differentials include, but are not limited to, benign nodular hyperplasia which occurs in 70% of older dogs and often does not result in an abnormal ultrasound, reactive or idiopathic/vacuolar hepatopathy, cholestasis and/or hyperadrenocorticism as well as many chronic non-hepatobiliary diseases such as chronic infections/inflammation from dental disease, IBD, neoplasia, hyperlipidemia, hypothyroidism, chronic pancreatitis, chronic stress, etc.

**IMAGING PERFORMED BY**

Dr. Jack Reese

There is no ultrasonographic evidence of cholestasis. Adrenocortical testing such as a low dose dexamethasone suppression test could be considered if clinical signs of hyperadrenocorticism are present. Ursodiol could be considered if gallbladder sludge is noted. A fine needle aspirate of the liver could be considered if patient's coagulation status is appropriate. Otherwise, recommendations include addressing any other concurrent disease and monitoring. If values are progressive, recheck imaging is recommended.

**HOSPITAL NAME**

Willow Run VC

**REFERRING VET**

Dr. Anna Leppian

**INVOICE**

40325

**DATE**

8/10/22



**PATIENT**

Nacho Velazquez-Naranjo

**SPECIES**

Canine

**BREED**

Boston Terrier

**SEX**

Neutered Male

**AGE**

7 Years

**WEIGHT**

32 Pounds

**INTERPRETED BY**

Beth Johnson, DVM  
DACVIM

**IMAGING PERFORMED BY**

Dr. Jack Reese

**HOSPITAL NAME**

Willow Run VC

**REFERRING VET**

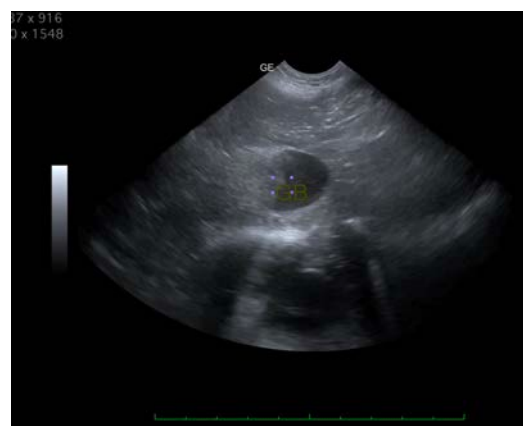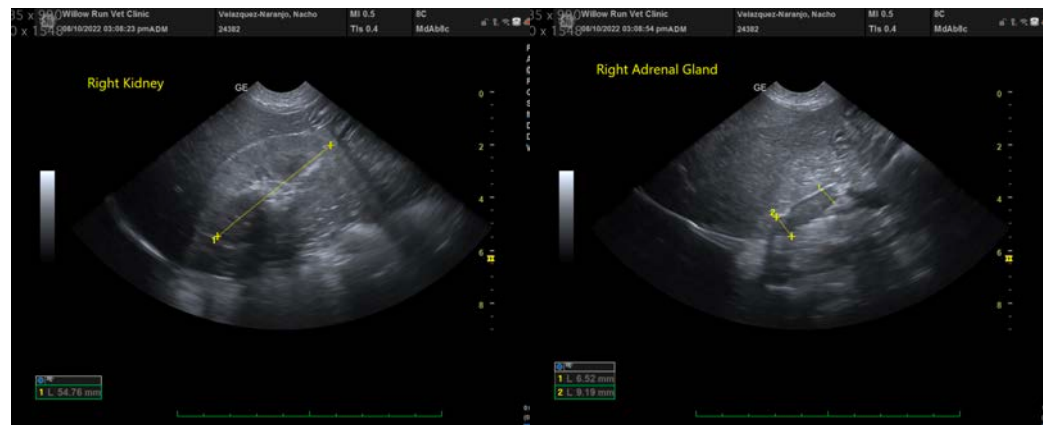
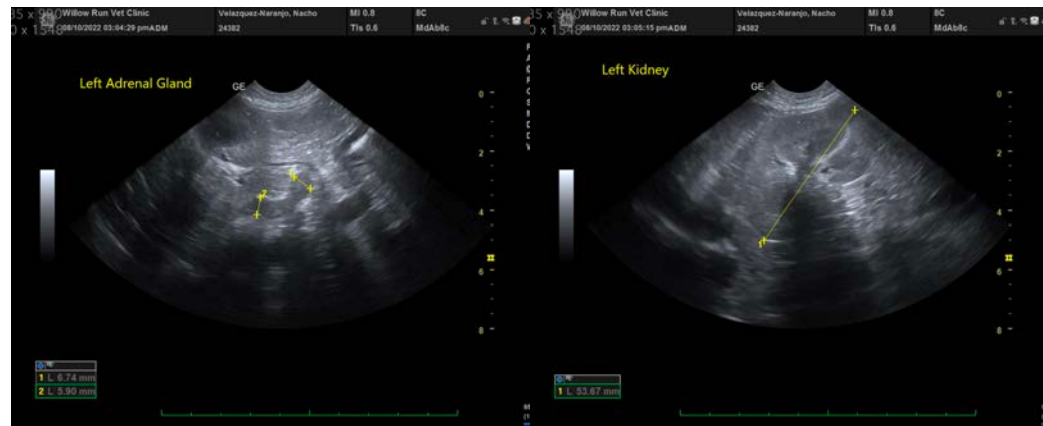
Dr. Anna Leppian

**INVOICE**

40325

**DATE**

8/10/22



The information and recommendations provided are based on the images presented by the referring veterinarian/sonographer. No evaluation can be communicated regarding pathology that was not visible in the image/video clips provided.

Thank you for this referral. If the clinical or image interpretation does not parallel your findings or if I can be of any further assistance please contact me.

**Beth Johnson, DVM, DACVIM**  
Beth.Johnson@sonopath.com