

**DATE PRESENTING CLINICAL SIGNS**

8/1/23 Decreased appetite past 5 months, wgt loss ~ 8lbs. PE: abd distension, mass palpable.

**PATIENT**

Current Medications: None.

Titan Barth

Lab Results: anemia. RBC: 3.4, HGB: 7.6, PCV: 26%, NRBC: 6. Urine Bilirubin: 2+ Blood: 1+

Date of Previous IntraPet Ultrasound: No previous.

Sedation: Not required to complete full diagnostic ultrasound.

Stat Report: Declined.

**SPECIES**

Imaging Performed By: Rachel Brillhart, RDMS.

Canine

**ULTRASONOGRAPHIC EXAMINATION OF THE ABDOMEN****BREED****Urinary System**

American Pit Bull

The urinary bladder is moderately distended with anechoic contents. No masses, inflammatory changes, echogenic sediment or cystoliths are observed. The urinary bladder, trigone and visible pelvic urethra are normal in thickness with a smooth mucosal surface.

**SEX**

Neutered Male

Prostate is normal in size, echotexture and echogenicity for a neutered male.

**AGE**

6/11/11

The right kidney is normal in size (6.33 cm), shape and echogenicity. It has smooth peripheral margination. There is a normal 1:3 cortex to medulla ratio with appropriate corticomedullary distinction. There is no evidence of pyelectasia, mineral or infarcts observed.

**WEIGHT**

72 Pounds

The left kidney is normal in size (7.46 cm), shape and echogenicity. It has smooth peripheral margination. There is a normal 1:3 cortex to medulla ratio with appropriate corticomedullary distinction. There is no evidence of pyelectasia, mineral or infarcts observed.

**INTERPRETED BY**

Beth Johnson, DVM  
DACVIM

**Adrenal Glands**

The right adrenal gland is normal in size (0.83 cm at the cranial pole and 0.80 cm at the caudal pole), shape and contour. Corticomedullary structure is unremarkable. Visible surrounding vasculature appears normal.

**HOSPITAL NAME**

Bel Air Vet

The left adrenal gland is normal in size (0.93 cm at the cranial pole and 0.94 cm at the caudal pole), shape and contour. Corticomedullary structure is unremarkable. Visible surrounding vasculature appears normal.

**REFERRING VET**

Dr. Schmidt

**Spleen**

The spleen is replaced by a 12+ cm markedly heterogeneous capsule disrupting mass with large cavitated areas. The mass is surrounded by free fluid as well as enhanced hyperechoic mesenteric fat.

**Liver**

Liver is subjectively enlarged with mildly irregular margins. Parenchyma is heterogenous characterized by multiple poorly defined hypoechoic nodules within otherwise hyperechoic liver parenchyma. Visible vasculature and biliary tree appear normal without distension or congestion.

**INVOICE**

44543

The gallbladder is non-distended in size. The wall is smooth without visible thickening. Luminal contents are primarily anechoic. There is no evidence of cystic or common bile duct dilation.

**Gastrointestinal**

The stomach wall is normal in thickness (canine < 0.5 cm and feline < 0.4 cm) and layering. The lumen of the stomach is empty with no evidence of obstruction, foreign material or infiltrative disease. Pyloric outflow tract appears patent.

The visible small intestines are normal in wall thickness and layering (canine duodenum < 0.5 cm and feline duodenum < 0.4 cm; other < 0.3 cm). Small intestinal motility appears adequate (1-3 contractions per min). The lumen of the small intestine is empty with no evidence of obstruction, foreign material or infiltrative disease.

The visible colon is normal in wall thickness (< 0.2 cm) and layering. Contents are consistent with normal formed feces and gas.

### ***Pancreas***

Pancreas is prominent (enlarged) in size and mildly irregular in shape with a slightly undulating contour. Parenchyma is coarse in echotexture and heterogenous to hypoechoic in echogenicity.

### ***Free Abdomen***

There is a moderate amount of free fluid adjacent to the splenic mass.

There is no apparent lymphadenopathy noted in these images.

There is no evidence of heart base or pericardial pathology noted in these images at this time. If cardiac function evaluation is desired a full echocardiogram is recommended.

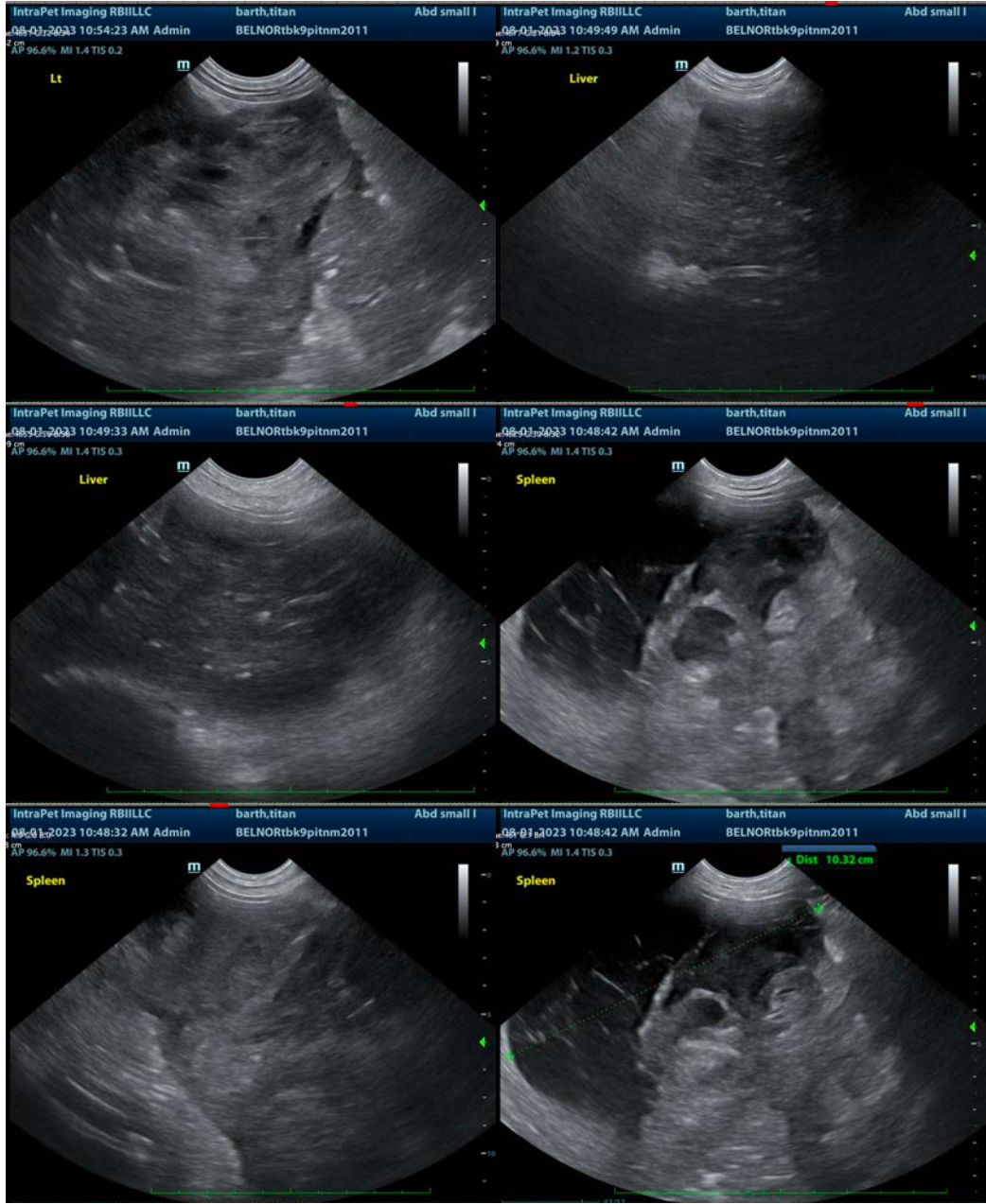
## **ULTRASONOGRAPHIC FINDINGS**

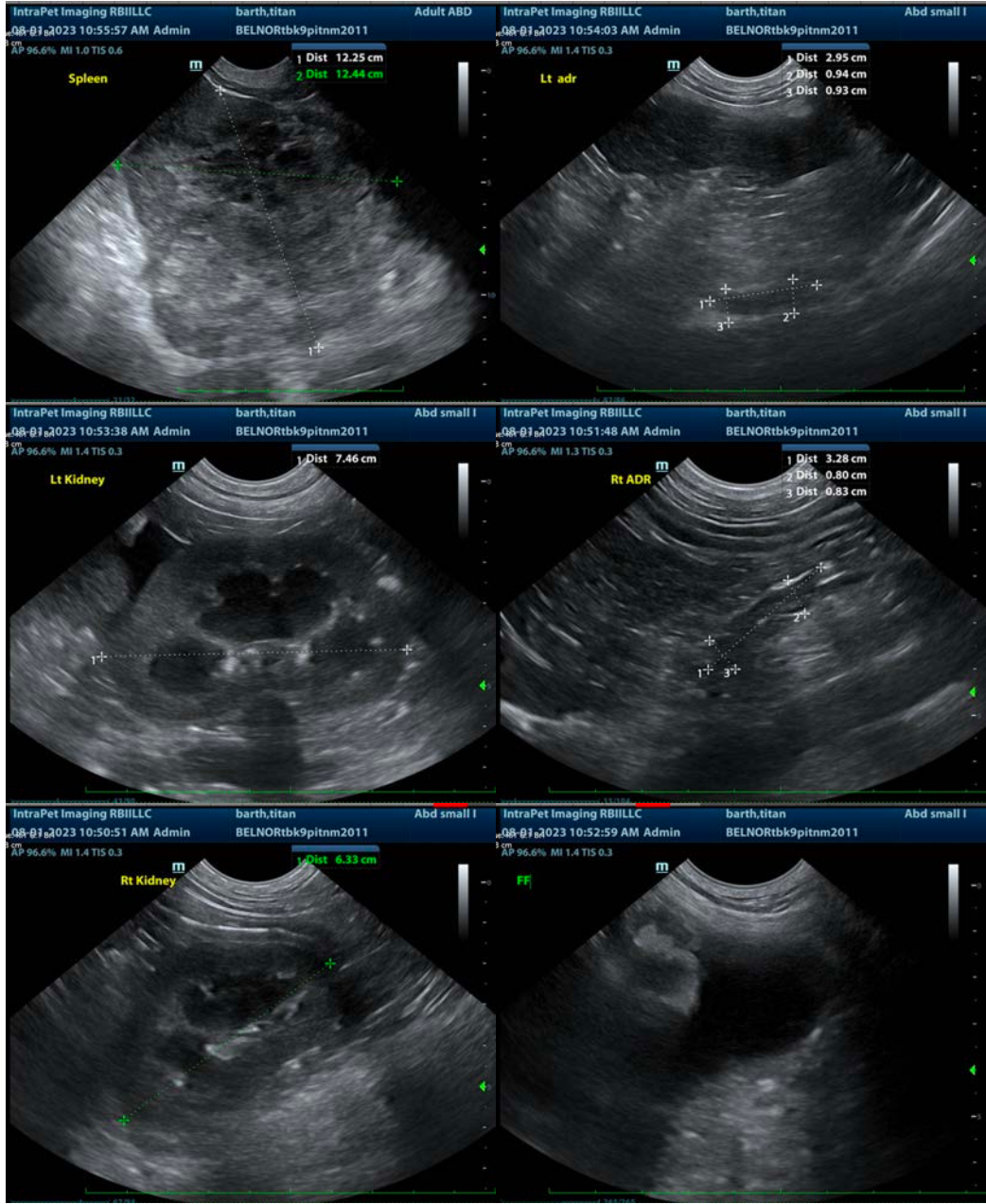
- Heterogeneous, cavitated splenic mass with free fluid – most concerning for infiltrative neoplasia such as sarcoma versus other. Having said that, benign cysts, hematomas, even extramedullary hematopoiesis can mimic neoplasia and cannot be differentiated without tissue sampling.
- Heterogenous Liver – These changes are most consistent with benign processes such as nodular hyperplasia, steroid (vacuolar) hepatopathy, extramedullary hematopoiesis or possibly chronic inflammatory disease and less commonly infiltrative round cell or metastatic neoplasia. The appearance of the liver trends toward benign with no definitive metastatic lesions. However, metastatic disease cannot be ruled out without tissue sampling.
- While less clinically significant in this patient, chronic smoldering pancreatitis should be suspected in the face of supporting clinical signs.

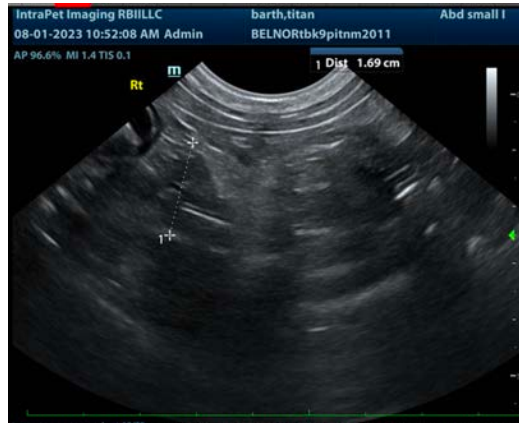## **INTERPRETATION OF THE FINDINGS & FURTHER RECOMMENDATIONS**

Three view thoracic radiographs are recommended for further assessment of cardio-pulmonary status as well as to further evaluate for any evidence of metastatic disease, if not recently evaluated.

Fine needle aspirates of the solid portion of the splenic mass and the liver could be considered if patient's coagulation status is appropriate. Alternatively, given the suspicion that this patient likely has a hemoabdomen and the risk for further hemorrhage, an exploratory laparotomy for planned splenectomy and liver biopsy could be considered.







The information and recommendations provided are based on the images presented by the referring veterinarian/sonographer. No evaluation can be communicated regarding pathology that was not visible in the image/video clips provided.

Thank you for this referral. If the clinical or image interpretation does not parallel your findings or if I can be of any further assistance please contact me.

**Beth Johnson, DVM, DACVIM**  
info@sonopath.com