



PATIENT PRESENTING CLINICAL SIGNS

Edmund Hooven Anorexia and lethargy 5 days duration, no vomiting or diarrhea observed, no known dietary indiscretion/ pica
SPECIES Abnormal PE/Chem/CBC/UA Results: PE: afebrile, possibly thickened segment of bowel
 CBC/CHEM: Lymphocyte =0.24 LOW (0.83- 9.1) 10⁹/l, NSF otherwise UA: usg>1.050, quiet sediment

Feline

ULTRASONOGRAPHIC EXAMINATION OF THE ABDOMEN

BREED *Urinary System*

DSH

Urinary bladder is adequately distended. It has a normal uniform wall thickness. Contents include primarily anechoic fluid with occasional echogenic non-shadowing debris, most consistent with incidental suspended lipid in a cat, possibly combined with exfoliated cells, mucous and/or small blood clots. Both sterile inflammation as well as urinary tract infection can also present with echogenic debris. No masses or cystoliths are observed. The trigone and visible pelvic urethra are normal in thickness with a smooth mucosal surface.

SEX

Neutered Male

AGE

4 Years 2 Months

The right kidney is normal in size (4.9 cm), shape and echogenicity. It has smooth peripheral margination. There is a normal 1:3 cortex to medulla ratio with appropriate corticomedullary distinction. There is no evidence of pyelectasia, mineral or infarcts observed.

The left kidney is normal in size (4.5 cm), shape and echogenicity. It has smooth peripheral margination. There is a normal 1:3 cortex to medulla ratio with appropriate corticomedullary distinction. There is no evidence of pyelectasia, mineral or infarcts observed.

WEIGHT

11.6 Pounds

Adrenal Glands

The area of the right adrenal gland is examined without evident pathology.

The left adrenal gland is normal in size (0.42 cm), shape and contour. Corticomedullary structure is unremarkable. Visible surrounding vasculature appears normal.

Spleen

The spleen is subjectively normal in size with a normal smooth capsular contour. Parenchyma is appropriately finely textured and homogenous with normal echogenicity relative to surrounding tissue (hyperechoic to liver). No focal nodules or masses are observed. Splenic vasculature appears normal.

INTERPRETED BY

Beth Johnson, DVM
DACVIM

IMAGING PERFORMED BY

Dr. Sarah Green

HOSPITAL NAME

Healing Spirit

Liver

The liver is subjectively normal in size with normal smooth curvilinear peripheral contour. Parenchyma is appropriately hypoechoic to the spleen in echogenicity and appropriately mildly coarse and homogenous in echotexture. No focal lesions are observed. Visible vasculature and biliary tree appear normal without distension or congestion.

REFERRING VET

Dr. Sarah Green

The gallbladder is non-distended in size. The wall is smooth without visible thickening. Luminal contents are primarily anechoic. There is no evidence of cystic or common bile duct dilation.

INVOICE

40026

Gastrointestinal

The stomach wall is normal in thickness (canine < 0.5 cm and feline < 0.4 cm) and layering. The lumen of the stomach is empty with no evidence of obstruction, foreign material or infiltrative disease. Pyloric outflow tract appears patent.

DATE

8/1/22

The visible small intestine demonstrates areas of thick muscularis layer relative to mucosa (disruption of the normal 1:3 muscularis:mucosa ratio). Small intestinal submucosa is slightly irregular, thick and



PATIENT	hyperechoic, without evident loss of layering appreciated. The lumen is empty with no evidence of obstruction or foreign material.
Edmund Hooven	
SPECIES	The visible colon is normal in wall thickness (< 0.2 cm) and layering. Contents are consistent with normal formed feces and gas.
Feline	Pancreas
BREED	The pancreatic parenchyma is appropriately isoechoic to surrounding tissue. Visible capsule is smooth and normal in contour. There is no visible pancreatic duct dilation. There is no evidence of active peripancreatic inflammation.
DSH	Free Abdomen
SEX	There is no evidence of free peritoneal effusion noted in these images.
Neutered Male	Cranial abdominal and possibly pancreaticoduodenal lymph nodes are prominent in size with swollen capsular contour. Normal elongated shape (length to width ratio) is maintained. There is no loss of parenchymal detail.
AGE	PRIMARY FINDINGS
4 Years 2 Months	<ul style="list-style-type: none"> Inflammatory bowel disease (IBD) pattern – Thick muscularis has been reported with infiltrative bowel disease including both benign inflammatory disease as well as infiltrative neoplasia such as lymphoma. No aggressive lymphadenopathy, loss of layering, etc. is noted to make lymphoma more probable, but lymphoma cannot be definitively ruled out without tissue sampling. Reactive cranial abdominal lymph nodes – infiltrative neoplastic disease cannot be ruled out but is considered less likely.
WEIGHT	SECONDARY FINDINGS
11.6 Pounds	<ul style="list-style-type: none"> Urinary bladder debris
INTERPRETED BY	INTERPRETATION OF THE FINDINGS & FURTHER RECOMMENDATIONS
Beth Johnson, DVM DACVIM	A gastrointestinal malabsorption panel (including cobalamin, folate, TLI and PLI) to Texas A&M GI Laboratory is recommended for further evaluation of GI and pancreatic function.
IMAGING PERFORMED BY	Ideally, biopsies of the GI tract, being sure to include ileum if possible, are recommended to definitively diagnose and therefore manage the infiltrative bowel disease.
Dr. Sarah Green	If biopsies cannot be obtained, empirical therapies could include diet change (to a novel or hydrolyzed protein diet), empirical deworming with a 5 day course of Panacur, cobalamin supplementation (unless cobalamin level is evaluated and supplementation is not warranted) and prednisolone (if not contraindicated based on patient contraindications, co-morbidities, etc.).
HOSPITAL NAME	
Healing Spirit	
REFERRING VET	
Dr. Sarah Green	
INVOICE	
40026	
DATE	
8/1/22	



PATIENT

Edmund Hooven

SPECIES

Feline

BREED

DSH

SEX

Neutered Male

AGE

4 Years 2 Months

WEIGHT

11.6 Pounds

INTERPRETED BY

Beth Johnson, DVM
DACVIM

IMAGING PERFORMED BY

Dr. Sarah Green

HOSPITAL NAME

Healing Spirit

REFERRING VET

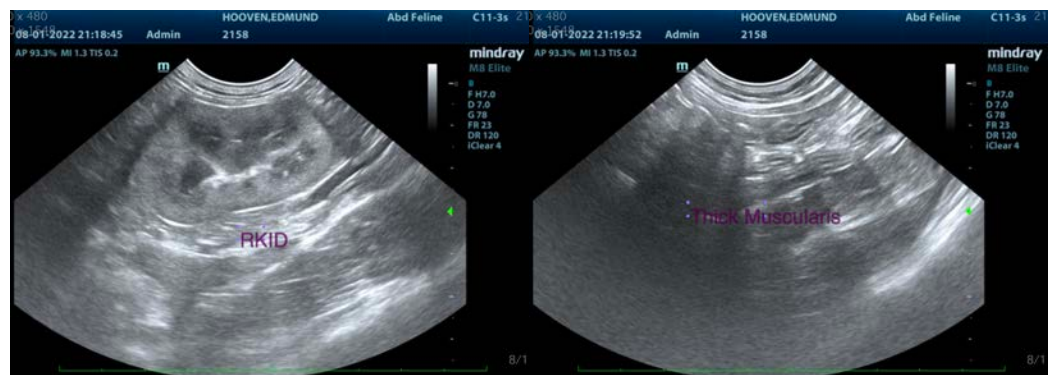
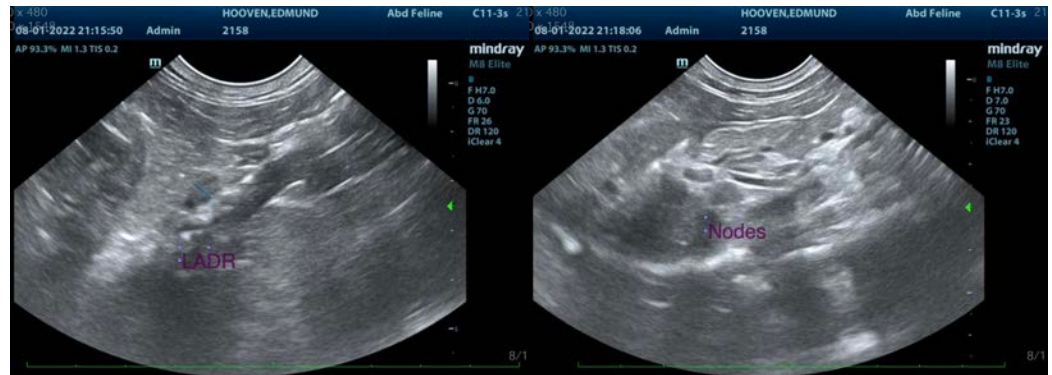
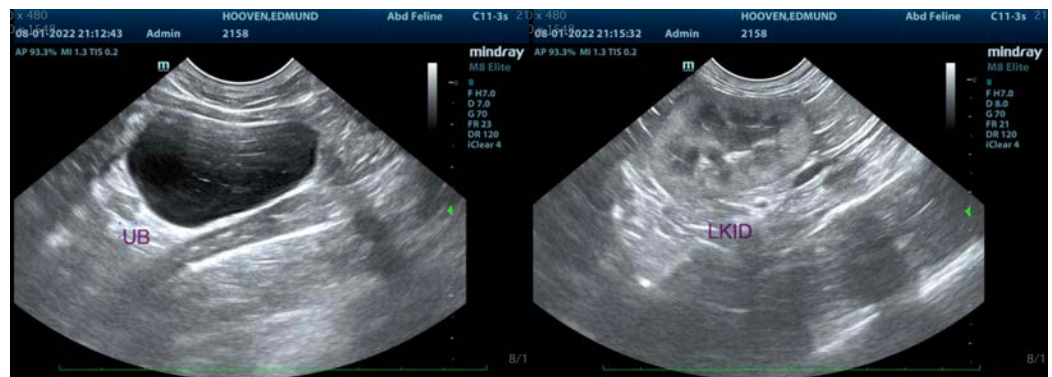
Dr. Sarah Green

INVOICE

40026

DATE

8/1/22



The information and recommendations provided are based on the images presented by the referring veterinarian/sonographer. No evaluation can be communicated regarding pathology that was not visible in the image/video clips provided.

Thank you for this referral. If the clinical or image interpretation does not parallel your findings or if I can be of any further assistance please contact me.

Beth Johnson, DVM, DACVIM
Beth.Johnson@sonopath.com