

**DATE PRESENTING CLINICAL SIGNS**

8/1/22 Not eating for 6 days. excessive drinking and urination. Panting. Lethargic.

PATIENT Current Medications: simplcef 100mg 1/2 sid, SQ inj cerenia adm in clinic

Bailey Heard Lab Results: BUN-60, Creatinine-2.1, ALP-623, Amylase-1728
Lipase-4379.

SPECIES Radiographs: Hx 2021 from aavec-Ventral midline celiotomy performed. Hemostasis maintained using monopolar electrosurgery. Removed falciform fat using monopolar electrosurgery. The omentum was adhered to the gallbladder. Removed omental adhesions using electrosurgery. The gallbladder was diffusely thickened and very firm. The cystic duct, hepatic ducts, and common bile duct were all dilated. The liver was diffusely coarse, micronodular and rounded

Canine

BREED

Bichon X

Date of Previous IntraPet Ultrasound: No previous.

SEX

Sedation: Not required to complete full diagnostic ultrasound.

Neutered Male

Stat Report: Not requested.

AGE

4/16/06

ULTRASONOGRAPHIC EXAMINATION OF THE ABDOMEN**Urinary System**

The urinary bladder is moderately distended with anechoic contents. No masses or inflammatory changes. The urinary bladder, trigone and visible pelvic urethra are normal in thickness with a smooth mucosal surface. Mineral foci are noted within the intraprostatic urethral lumen.

WEIGHT

22.8 Pounds

Prostate is normal in size, echotexture and echogenicity for a neutered male.

INTERPRETED BY

Beth Johnson, DVM
DACVIM

The right kidney is normal in size (5.24 cm), shape and echogenicity. It has smooth peripheral margination. There is a normal 1:3 cortex to medulla ratio with appropriate corticomedullary distinction. There is no evidence of pyelectasia or infarcts observed. Multiple non-obstructive nephroliths noted.

IMAGING PERFORMED BY

Rachel Brillhart RDMS

The left kidney is normal in size (5.0 cm), shape and echogenicity. It has smooth peripheral margination. There is a normal 1:3 cortex to medulla ratio with appropriate corticomedullary distinction. There is no evidence of pyelectasia or infarcts observed. Multiple non-obstructive nephroliths noted.

HOSPITAL NAME

AC of Southgate

Adrenal Glands

The right adrenal gland is normal in size (1.69 cm long x 0.64 cm at the cranial pole and 0.68 cm at the caudal pole), shape and contour. Corticomedullary structure is unremarkable. Visible surrounding vasculature appears normal.

REFERRING VET

Dr. Jones

The left adrenal gland is normal in size (2.76 cm long x 0.84 cm at the cranial pole and 1.1 cm at the caudal pole), shape and contour. Corticomedullary structure is unremarkable. Visible surrounding vasculature appears normal.

INVOICE

39996

Spleen

Spleen is generally normal in size and shape with a smooth capsular contour. Parenchyma is diffusely nodular in appearance characterized by small discrete hypoechoic nodules. Splenic vasculature appears normal.

Liver

Liver is subjectively enlarged with mildly irregular margins. Parenchyma is heterogenous characterized by multiple poorly defined hypoechoic nodules within otherwise hyperechoic liver parenchyma. The left caudal liver has a rounded appearance, suggestive for an early or emerging homogeneous, hypoechoic mass, measuring 3.5 cm x 4.5 cm. Multifocal intrahepatic biliary mineral present. Visible vasculature and biliary tree appear normal without distension or congestion.

Gallbladder is moderately overdistended with organized, aggregated and centralized non-gravity dependent sludge. Striations of sludge separated by anechoic areas are noted extending from the lumen to the luminal wall. The wall is mildly thick, irregular and hyperechoic. There is no evidence of CBD dilation.

Gastrointestinal

The stomach wall is normal in thickness (canine < 0.5 cm and feline < 0.4 cm) and layering. The lumen of the stomach is empty with no evidence of obstruction, foreign material or infiltrative disease. Pyloric outflow tract appears patent.

The visible small intestines are normal in wall thickness and layering (canine duodenum < 0.5 cm and feline duodenum < 0.4 cm; other < 0.3 cm). Small intestinal motility appears adequate (1-3 contractions per min). The lumen of the small intestine is empty with no evidence of obstruction, foreign material or infiltrative disease.

The visible colon is normal in wall thickness (< 0.2 cm) and layering. Contents are consistent with normal formed feces and gas.

Pancreas

The observed pancreas appears appropriately isoechoic to surrounding omental fat. The capsule is mildly irregular in shape. Parenchyma is mildly heterogenous and coarse. There is no visible pancreatic duct dilation. There is no evidence of active peripancreatic inflammation.

Free Abdomen

There is no evidence of free peritoneal effusion noted in these images.

A portal lymph node is notably enlarged and hypoechoic in appearance.

PRIMARY FINDINGS

- Gallbladder mucocele
- **Heterogenous Liver** – These changes are most consistent with benign processes such as nodular hyperplasia, steroid (vacuolar) hepatopathy, extramedullary hematopoiesis or possibly chronic inflammatory disease and less commonly infiltrative round cell or metastatic neoplasia. An emerging left caudal liver mass suspected. Differentials include well differentiated primary hepatic neoplasia such as hepatocellular carcinoma versus infiltrative round cell neoplasia. Benign nodular hyperplasia is also a differential. The concurrent intrahepatic biliary mineral combined with portal lymphadenomegaly is concerning for concurrent chronic cholangitis or cholangiohepatitis as well.

SECONDARY FINDINGS

- **Pancreatic age-related remodeling** – Mild irregularities are consistent with benign age-related change. Low-grade smoldering chronic pancreatitis cannot be ruled out and should be suspected in the face of appropriate clinical signs.

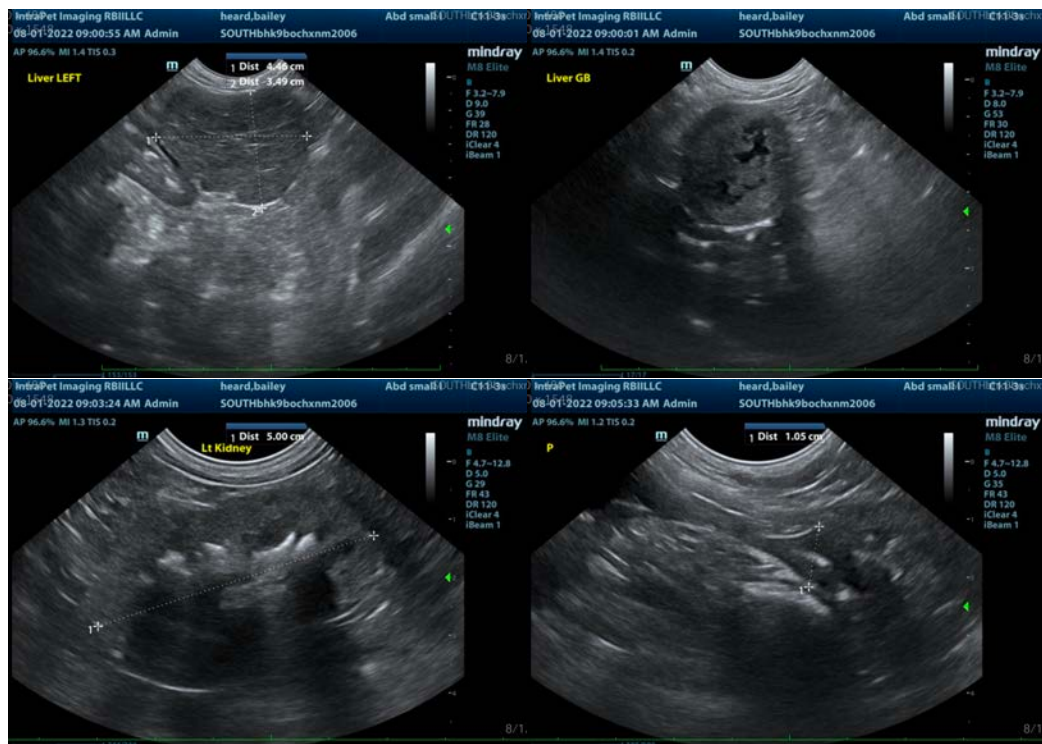
- **Splenic micronodular hyperplasia pattern** – This nodular change is often associated with benign aging nodular hyperplasia. Infiltrative neoplasia, however, including both early hemangiosarcoma as well as round cell neoplasia cannot be ruled out.
- Non-obstructive nephrolithiasis bilaterally.
- Mineral within the lumen of the urethra at the level of the prostate.

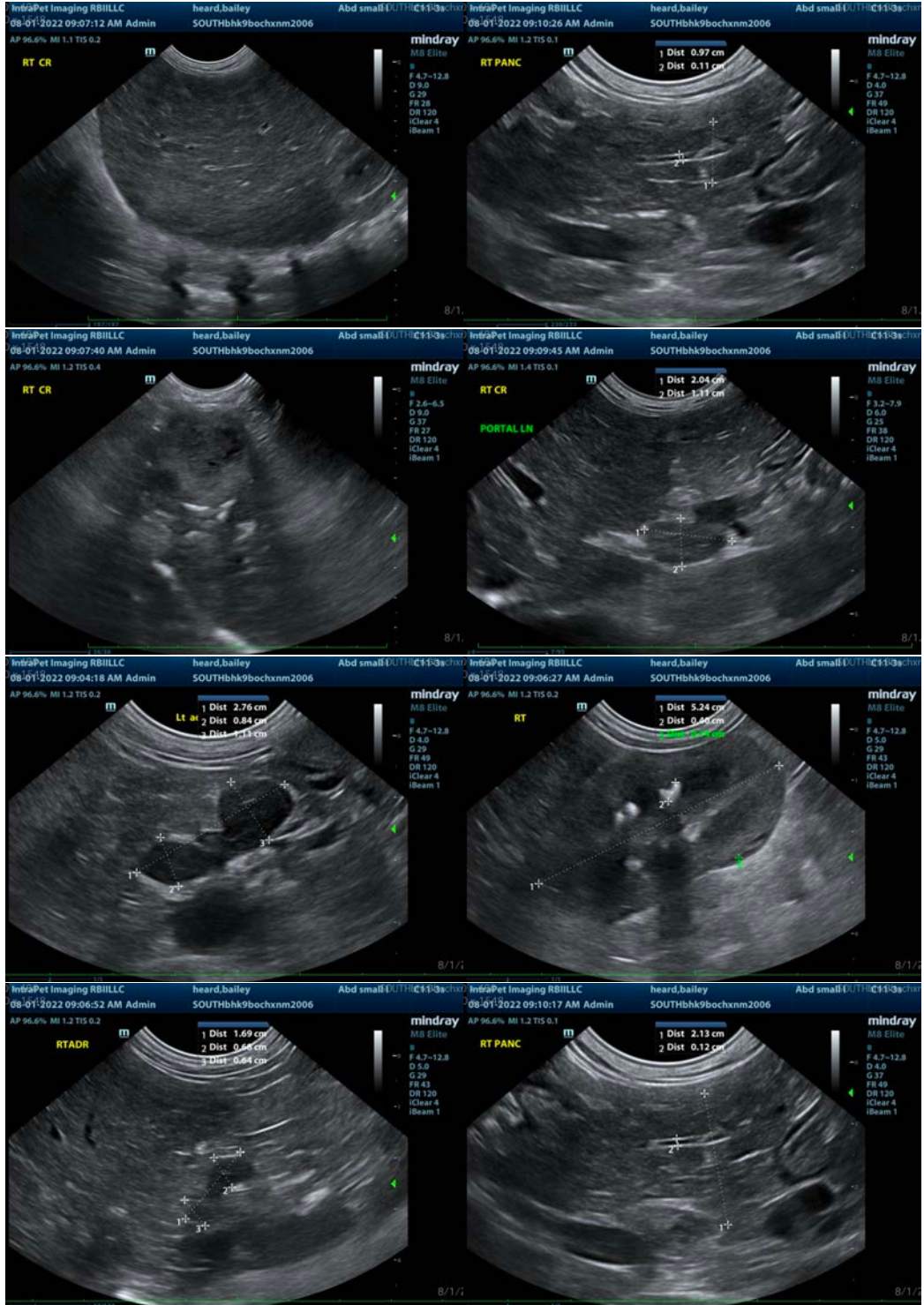
INTERPRETATION OF THE FINDINGS & FURTHER RECOMMENDATIONS

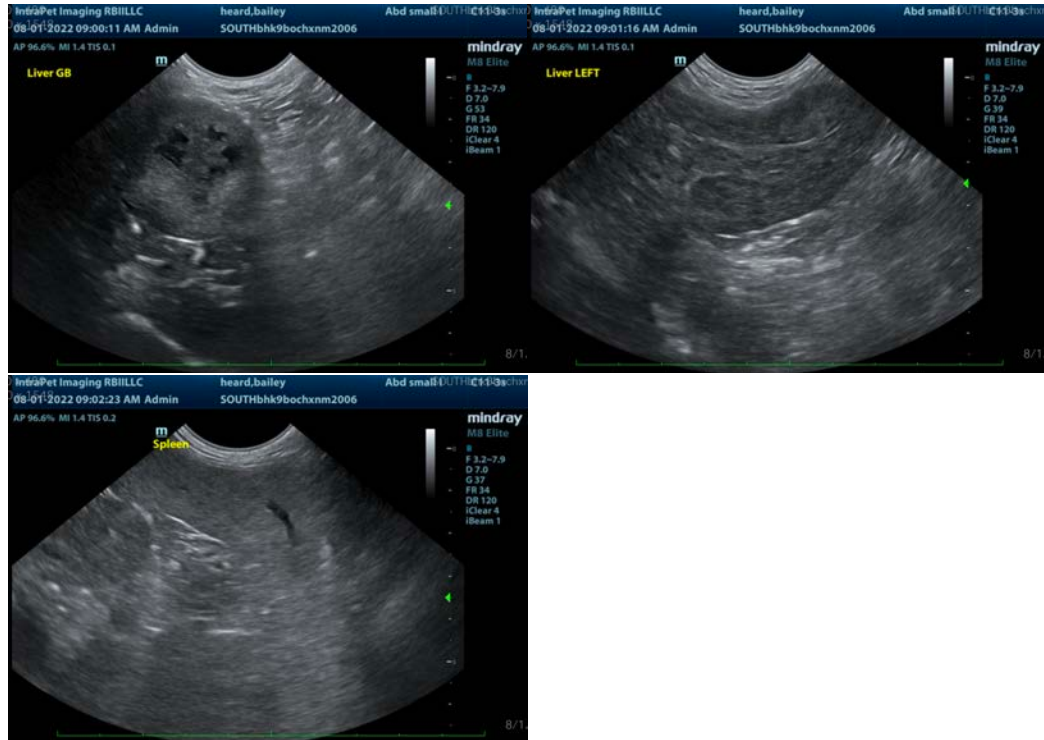
To help determine whether this patient's azotemia is renal or prerenal, Urinalysis and, if indicated based on urinalysis results, urine culture are recommended. If protein is present in an otherwise quiet sediment, protein quantification with a urine protein to creatinine ration is recommended.

Three view thoracic radiographs are recommended for further assessment of cardio-pulmonary status as well as to further evaluate for any evidence of metastatic disease, if not recently evaluated.

A fine needle aspirate of the diffuse liver changes as well as the left caudal liver mass could be considered if patient's coagulation status is appropriate. However, given the concurrent mucocele, an exploratory laparotomy may be considered instead for further evaluation of the gallbladder/cholecystectomy and liver mass removal/liver lobectomy, and excisional biopsy instead, especially if this patient's decreased appetite cannot be attributed to something else such as a urinary tract infection or kidney disease, etc., in which case the inappetence very well could be secondary to the gallbladder mucocele.







The information and recommendations provided are based on the images presented by the referring veterinarian/sonographer. No evaluation can be communicated regarding pathology that was not visible in the image/video clips provided.

Thank you for this referral. If the clinical or image interpretation does not parallel your findings or if I can be of any further assistance please contact me.

Beth Johnson, DVM, DACVIM
Beth.Johnson@sonopath.com