



**PATIENT PRESENTING CLINICAL SIGNS**

Butch Ng Slowly elevating ALP over the last 2 years. No clinical signs.

**SPECIES ULTRASONOGRAPHIC EXAMINATION OF THE ABDOMEN**

**Canine Urinary System**

The urinary bladder is moderately distended with anechoic contents. No masses, inflammatory changes, echogenic sediment or cystoliths are observed. The urinary bladder, trigone and visible pelvic urethra are normal in thickness with a smooth mucosal surface.

**BREED**

Bichon Frise Prostate (neutered) is normal in size, echotexture and echogenicity for a neutered male.

**SEX**

Neutered Male The right kidney is normal in size (4.4 cm), shape and echogenicity. It has smooth peripheral margination. There is a normal 1:3 cortex to medulla ratio with appropriate corticomedullary distinction. There is no evidence of pyelectasia, mineral or infarcts observed.

**AGE**

11 Years 5 Months The left kidney is normal in size (4.5 cm), shape and echogenicity. It has smooth peripheral margination. There is a normal 1:3 cortex to medulla ratio with appropriate corticomedullary distinction. There is no evidence of pyelectasia, mineral or infarcts observed.

**Adrenal Glands**

**WEIGHT**

22.3 Pounds The right adrenal gland is normal in size (0.60 cm at the caudal pole), shape and contour. Corticomedullary structure is unremarkable. Visible surrounding vasculature appears normal.

The left adrenal gland is normal in size (0.50 cm at the caudal pole), shape and contour. Corticomedullary structure is unremarkable. Visible surrounding vasculature appears normal.

**INTERPRETED BY**

**Spleen**

Beth Johnson, DVM DACVIM Spleen is subjectively normal in size with a normal smooth capsular contour. Parenchyma is appropriately finely textured and homogenous with normal echogenicity relative to surrounding tissue (hyperechoic to liver). Multifocal well-demarcated hyperechoic homogenous nodules are present. Splenic vasculature appears normal.

**IMAGING PERFORMED BY**

**Liver**

Dr. Katie Buss The liver is subjectively normal in size with normal smooth curvilinear peripheral contour. Parenchyma is appropriately hypoechoic to the spleen in echogenicity and appropriately mildly coarse and homogenous in echotexture. No focal lesions are observed. Visible vasculature and biliary tree appear normal without distension or congestion.

**HOSPITAL NAME**

Kings Vet Hospital

**REFERRING VET**

Dr. Katie Buss

**Gastrointestinal**

**INVOICE**

39340 The stomach wall is normal in thickness (canine < 0.5 cm and feline < 0.4 cm) and layering. The lumen of the stomach is empty with no evidence of obstruction, foreign material or infiltrative disease. Pyloric outflow tract appears patent.

**DATE**

7/8/22 The visible small intestines are normal in wall thickness and layering (canine duodenum < 0.5 cm and feline duodenum < 0.4 cm; other < 0.3 cm). Small intestinal motility appears adequate (1-3 contractions



**PATIENT**

Butch Ng

per min). The lumen of the small intestine is empty with no evidence of obstruction, foreign material or infiltrative disease.

The visible colon is normal in wall thickness (< 0.2 cm) and layering. Contents are consistent with normal formed feces and gas.

**SPECIES**

Canine

**Pancreas**

The pancreatic parenchyma is appropriately isoechoic to surrounding tissue. Visible capsule is smooth and normal in contour. There is no visible pancreatic duct dilation. There is no evidence of active peripancreatic inflammation.

**BREED**

Bichon Frise

**Free Abdomen**

There is no evidence of free peritoneal effusion noted in these images.

**SEX**

Neutered Male

There is no apparent lymphadenopathy noted in these images.

**ULTRASONOGRAPHIC FINDINGS**

**AGE**

11 Years 5 Months

- Cholecystic debris is of unknown clinical significance. It can be seen with biliary stasis from fasting or illness. Cholecystic debris is not necessarily related to hepatobiliary disease. Echogenic bile is most commonly an incidental finding in dogs and should be interpreted in combination with clinical signs such as nausea, inappetence, cranial abdominal discomfort and/or laboratory changes such as increased ALP and/or increased Tbili.

**WEIGHT**

22.3 Pounds

- Hyperechoic splenic nodules – most consistent with benign myelolipomas. Other differentials such as fibrosis or calcification caused by old hematomas or infarcts, chronic inflammation, granulomatous disease or metastatic disease cannot be ruled out, but are less likely.

**INTERPRETED BY**

Beth Johnson, DVM  
DACVIM

**INTERPRETATION OF THE FINDINGS & FURTHER RECOMMENDATIONS**

**ALP** – Differentials are vast and non-specific. Differentials include, but are not limited to, benign nodular hyperplasia which occurs in 70% of older dogs and often does not result in an abnormal ultrasound, reactive or idiopathic/vacuolar hepatopathy, cholestasis and/or hyperadrenocorticism as well as many chronic non-hepatobiliary diseases such as chronic infections/inflammation from dental disease, IBD, neoplasia, hyperlipidemia, hypothyroidism, chronic pancreatitis, chronic stress, etc.

**IMAGING PERFORMED BY**

Dr. Katie Buss

There is no ultrasonographic evidence of cholestasis. Adrenocortical testing such as a low dose dexamethasone suppression test could be considered if clinical signs of hyperadrenocorticism are present. Ursodiol could be considered if gallbladder sludge is noted. A fine needle aspirate of the liver could be considered if patient's coagulation status is appropriate. Otherwise, recommendations include addressing any other concurrent disease and monitoring. If values are progressive, recheck imaging is recommended.

**HOSPITAL NAME**

Kings Vet Hospital

**REFERRING VET**

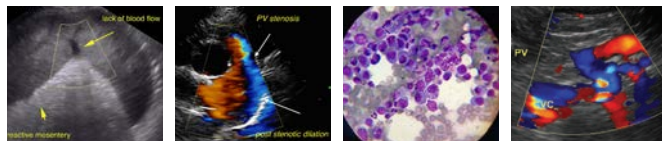
Dr. Katie Buss

**INVOICE**

39340

**DATE**

7/8/22



**PATIENT**

Butch Ng

**SPECIES**

Canine

**BREED**

Bichon Frise

**SEX**

Neutered Male

**AGE**

11 Years 5 Months

**WEIGHT**

22.3 Pounds

**INTERPRETED BY**

Beth Johnson, DVM  
DACVIM

**IMAGING PERFORMED BY**

Dr. Katie Buss

**HOSPITAL NAME**

Kings Vet Hospital

**REFERRING VET**

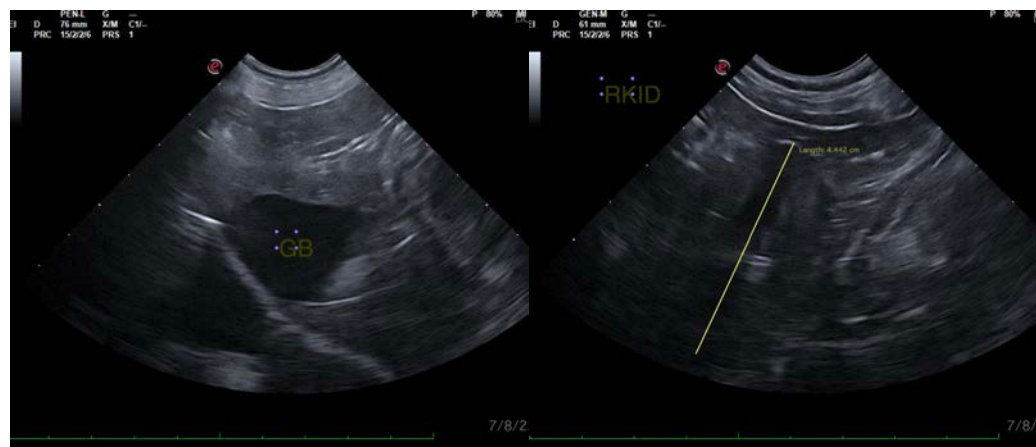
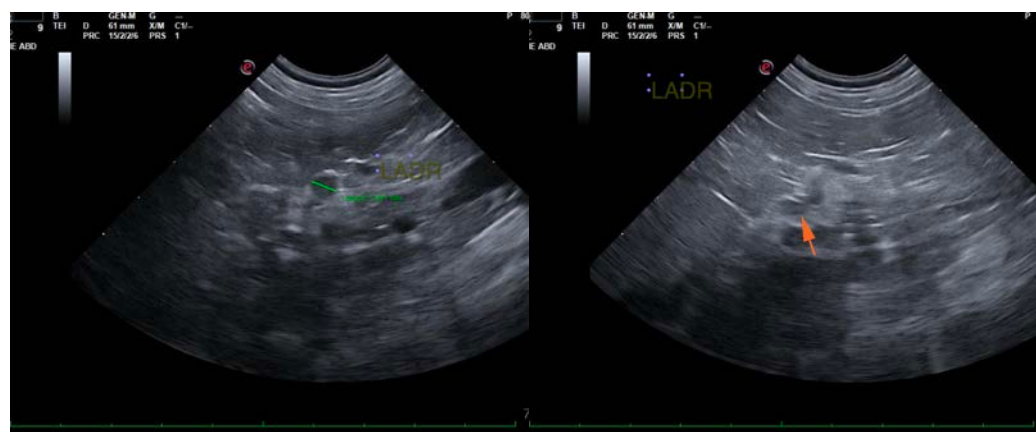
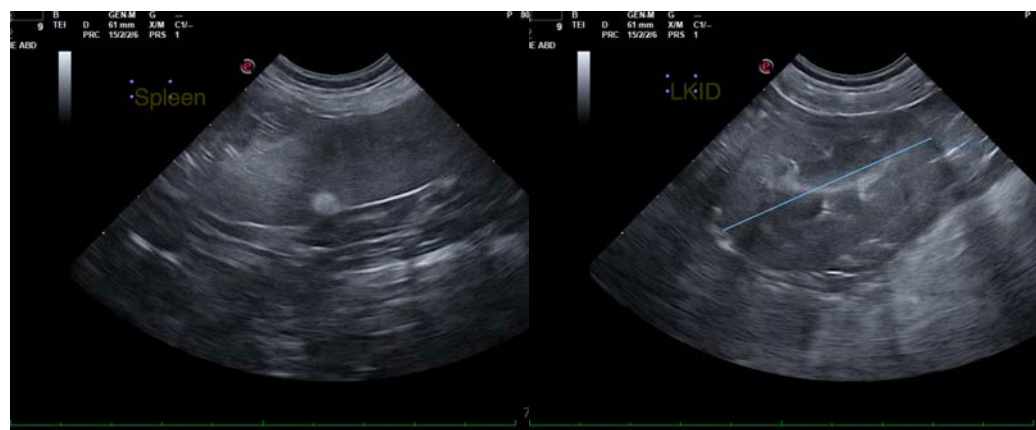
Dr. Katie Buss

**INVOICE**

39340

**DATE**

7/8/22





**PATIENT**

Butch Ng

**SPECIES**

Canine

**BREED**

Bichon Frise

**SEX**

Neutered Male

**AGE**

11 Years 5 Months

**WEIGHT**

22.3 Pounds

**INTERPRETED BY**

Beth Johnson, DVM  
DACVIM

**IMAGING  
PERFORMED BY**

Dr. Katie Buss

**HOSPITAL NAME**

Kings Vet Hospital

**REFERRING VET**

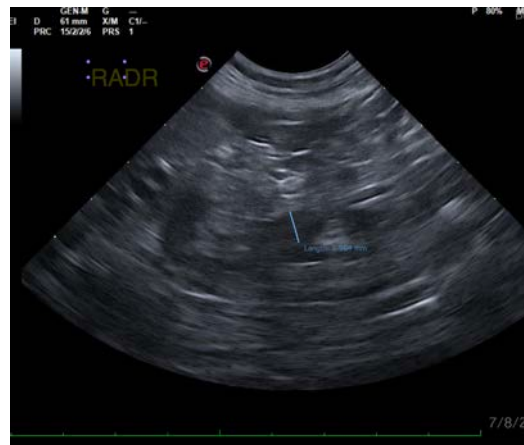Dr. Katie Buss

**INVOICE**

39340

**DATE**

7/8/22



The information and recommendations provided are based on the images presented by the referring veterinarian/sonographer. No evaluation can be communicated regarding pathology that was not visible in the image/video clips provided.

Thank you for this referral. If the clinical or image interpretation does not parallel your findings or if I can be of any further assistance please contact me.

**Beth Johnson, DVM, DACVIM**  
Beth.Johnson@sonopath.com