



**PATIENT PRESENTING CLINICAL SIGNS**

**PATIENT** Salsa Long  
Hx of anorexia and vomiting. 2 lbs of weight loss in 6 weeks. owner noticed her hiding 10 days ago. Was eating till 3 days ago.

**SPECIES**

Feline

Abnormal PE/Chem/CBC/UA Results: Jaundice CBC - unremarkable Chem: ALT- 141 ALP- 499 TBIL- 5.5 K+ - 3.2

**BREED**

DSH

**ULTRASONOGRAPHIC EXAMINATION OF THE ABDOMEN**

**Urinary System**

**SEX**

Spayed Female

Urinary bladder is adequately distended. It has a normal uniform wall thickness. Contents include primarily anechoic fluid with occasional echogenic non-shadowing debris, most consistent with incidental suspended lipid in a cat, possibly combined with exfoliated cells, mucous and/or small blood clots. Both sterile inflammation as well as urinary tract infection can also present with echogenic debris. No masses or cystoliths are observed. The trigone and visible pelvic urethra are normal in thickness with a smooth mucosal surface.

**AGE**

9

The right kidney is normal in size (3.64 cm), shape and echogenicity. It has smooth peripheral margination. There is a normal 1:3 cortex to medulla ratio with appropriate corticomedullary distinction. There is no evidence of pyelectasia, mineral or infarcts observed.

**WEIGHT**

9

The left kidney is normal in size (3.85 cm), shape and echogenicity. It has smooth peripheral margination. There is a normal 1:3 cortex to medulla ratio with appropriate corticomedullary distinction. There is no evidence of pyelectasia, mineral or infarcts observed.

**INTERPRETED BY**

Beth Johnson, DVM  
DACVIM

**Adrenal Glands**

The right adrenal gland is normal in size (0.29 cm), shape and contour. Corticomedullary structure is unremarkable. Visible surrounding vasculature appears normal.

**IMAGING PERFORMED BY**

Dr. Adrienne Waffle

The left adrenal gland is normal in size (0.39 cm), shape and contour. Corticomedullary structure is unremarkable. Visible surrounding vasculature appears normal.

**HOSPITAL NAME**

Torch Lake VC

**Spleen**

Spleen is subjectively large in size with a mildly swollen but smooth capsule. Parenchyma is normal and homogenous in echogenicity and echotexture. No focal nodules or masses are observed. Splenic vasculature appears normal.

**REFERRING VET**

Dr. Adrienne Waffle

**Liver**

Liver is subjectively enlarged (swollen contour) without disruption of architecture. It has a normal homogenous echotexture. Parenchyma is diffusely hyperechoic characterized by less prominent than normal portal vein walls and increased echogenicity relative to the spleen and falciform fat. No focal lesions are observed. Visible vasculature and biliary tree appear normal without distension or congestion.

**INVOICE**

43841

**DATE**

7/7/23

The gallbladder is non-distended in size. The wall is smooth without visible thickening. Luminal contents are primarily anechoic. There is no evidence of cystic or common bile duct dilation.



**PATIENT** *Gastrointestinal*

Salsa Long Fundic mucosal hypertrophy with hyperechoic mucosa and some mucosal remodeling is noted. There is no loss of mural detail. Layering is normal. There is mild luminal fluid accumulation. No evidence of masses/nodules or foreign material present.

**SPECIES**

Feline

The visible small intestines are normal in wall thickness and layering (canine duodenum < 0.5 cm and feline duodenum < 0.4 cm; other < 0.3 cm). Small intestinal motility appears adequate (1-3 contractions per min). The lumen of the small intestine is empty with no evidence of obstruction, foreign material or infiltrative disease.

**BREED**

DSH

The visible colon is normal in wall thickness (< 0.2 cm) and layering. Contents are consistent with normal formed feces and gas.

**SEX**

Spayed Female

**Pancreas**

The pancreatic parenchyma is appropriately isoechoic to surrounding tissue. Visible capsule is smooth and normal in contour. There is no visible pancreatic duct dilation. There is no evidence of active peripancreatic inflammation.

**AGE**

9

**Free Abdomen**

A trace amount of anechoic free fluid is noted between liver lobes.

**WEIGHT**

9

There is no apparent lymphadenopathy noted in these images.

**INTERPRETED BY**

Beth Johnson, DVM  
DACVIM

**ULTRASONOGRAPHIC FINDINGS**

- Hyperechoic hepatomegaly – This appearance is most consistent with benign hepatic lipidosis. Infiltrative disease such as amyloidosis or round cell neoplasia, such as mast cell tumor or less likely, lymphoma, is also possible.
- Trace amount of anechoic free fluid between liver lobes
- Hypersplenism – can be associated with congestion caused by sedation (if sedated) but can also be associated with diffuse infiltrative disease. Both benign conditions such as extramedullary hematopoiesis, lymphoid hyperplasia, amyloidosis as well as infiltrative neoplastic diseases such as round cell neoplasia should be considered.
- Gastritis – Consistent with irritation secondary to dietary indiscretion or intolerance, infection (bacterial, viral, other), parasitic or protozoal disease, toxin, other metabolic disease such as pancreatitis, other. Microulceration cannot be ruled out.
- Urinary bladder debris

**IMAGING PERFORMED BY**

Dr. Adrienne Waffle

**HOSPITAL NAME**

Torch Lake VC

**REFERRING VET**

Dr. Adrienne Waffle

**INVOICE**

43841

**DATE**

7/7/23

**INTERPRETATION OF THE FINDINGS & FURTHER RECOMMENDATIONS**

There is no ultrasonographically visible evidence of post-hepatic cholestasis present in these images. Therefore, intrahepatic cholestasis is considered the most likely cause of this patient's reported icterus.

Recommendations include fine needle aspirates of both the liver and spleen if patient's coagulation status is appropriate.

Additionally, if not recently evaluated, a urinalysis and, if indicated based on urinalysis results, urine culture are recommended. If protein is present in an otherwise quiet sediment, protein quantification with a urine protein to creatinine ratio is recommended.



**PATIENT**

Salsa Long

In the meantime, treatment recommendations include fluid therapy, anti-emetics, gastroprotectants, hepatic nutraceuticals such as ursodiol and/or Denamarin, and broad spectrum antibiotics. Nutritional support is critical to prevent/manage concurrent hepatic lipidosis, so appetite stimulants and/or, if indicated, feeding tube placement is also recommended.

**SPECIES**

Feline

**BREED**

DSH

**SEX**

Spayed Female

**AGE**

9

**WEIGHT**

9

**INTERPRETED BY**

Beth Johnson, DVM  
DACVIM

**IMAGING PERFORMED BY**

Dr. Adrienne Waffle

**HOSPITAL NAME**

Torch Lake VC

**REFERRING VET**

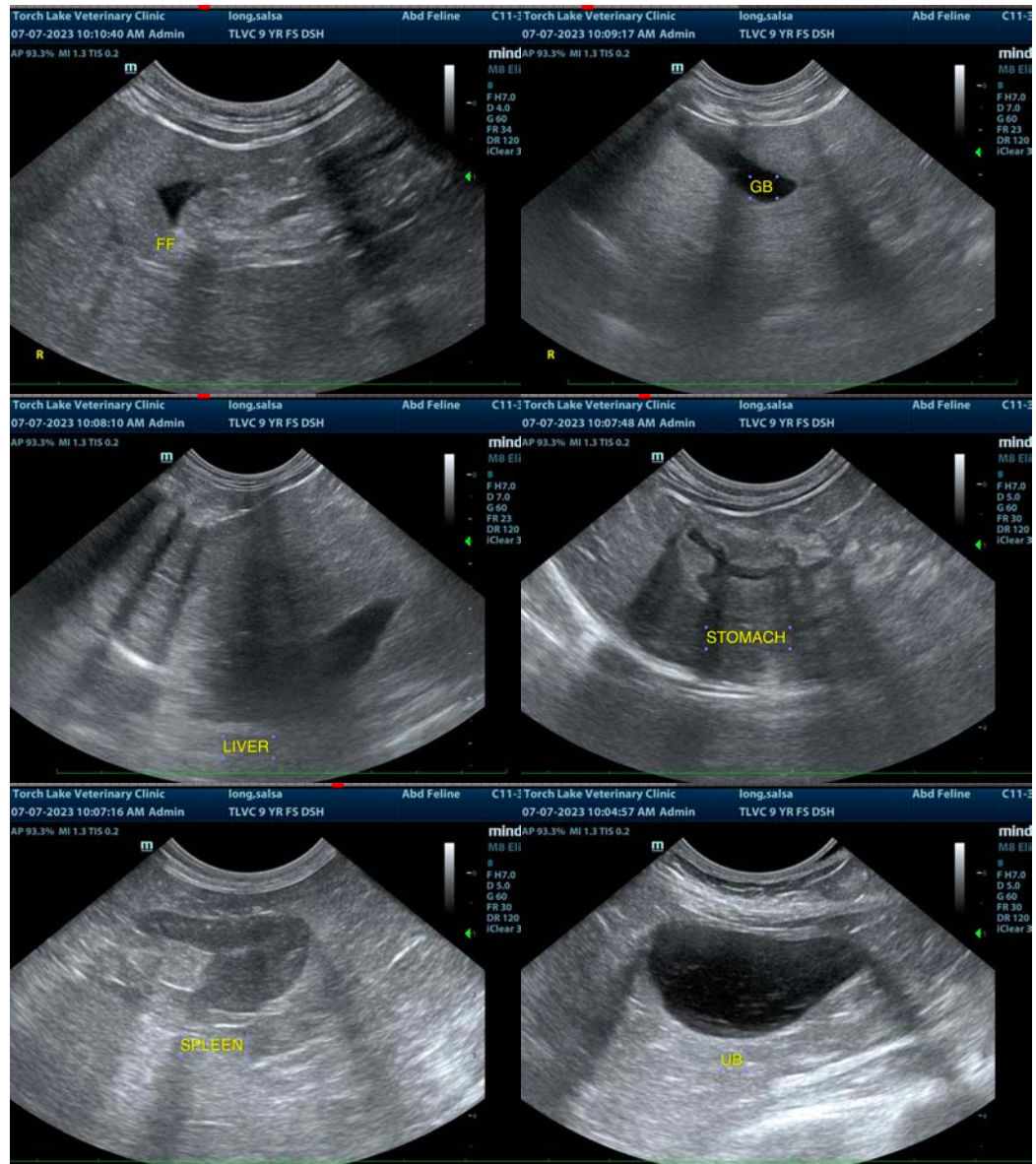
Dr. Adrienne Waffle

**INVOICE**

43841

**DATE**

7/7/23





**PATIENT**

Salsa Long

**SPECIES**

Feline

**BREED**

DSH

**SEX**

Spayed Female

**AGE**

9

**WEIGHT**

9

**INTERPRETED BY**

Beth Johnson, DVM  
DACVIM

**IMAGING PERFORMED BY**

Dr. Adrienne Waffle

**HOSPITAL NAME**

Torch Lake VC

**REFERRING VET**

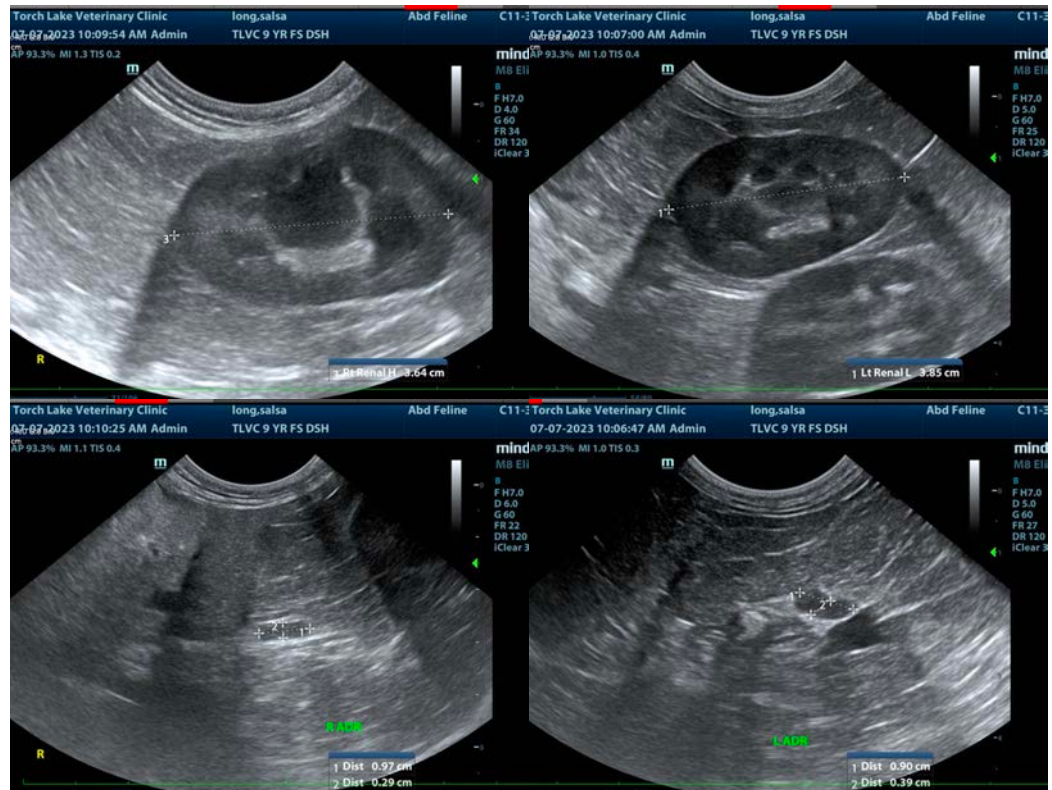
Dr. Adrienne Waffle

**INVOICE**

43841

**DATE**

7/7/23



The information and recommendations provided are based on the images presented by the referring veterinarian/sonographer. No evaluation can be communicated regarding pathology that was not visible in the image/video clips provided.

Thank you for this referral. If the clinical or image interpretation does not parallel your findings or if I can be of any further assistance please contact me.

**Beth Johnson, DVM, DACVIM**  
info@sonopath.com