

**DATE**

7/7/22

PRESENTING CLINICAL SIGNS

6/20/22 - Weight loss. Occasional vomiting and diarrhea. Normal appetite. New client. Lost 2.4 lbs. in 4 months. Exam otherwise unremarkable

Current Medications: Gabapentin for ultrasound.

Lab Results: 6/20/22 - CBC/Chem 11 - TP - 6.2, Glob-2.5; Spec FPL - 2.8 (normal); T4 - 2.3 (normal).

Date of Previous IntraPet Ultrasound: No previous.

Sedation: Not required to complete full diagnostic ultrasound.

Stat Report: Not requested.

Imaging Performed By: Stephanie Pearce RDCS, RVT.

PATIENT

Winston Musacchio

SPECIES

Feline

BREED

Domestic Shorthair

SEX

Neutered male

AGE

6/22/12

WEIGHT

11.2 lbs

INTERPRETED BY

Beth Johnson, DVM
DACVIM

HOSPITAL NAME

Parkville AH

REFERRING VET

Dr. Suter

INVOICE

31510

ULTRASONOGRAPHIC EXAMINATION OF THE ABDOMEN**Urinary System**

Urinary bladder is adequately distended. It has a normal uniform wall thickness. Contents include primarily anechoic fluid with occasional echogenic non-shadowing debris, most consistent with incidental suspended lipid in a cat, possibly combined with exfoliated cells, mucous and/or small blood clots. Both sterile inflammation as well as urinary tract infection can also present with echogenic debris. No masses or cystoliths are observed. The trigone and visible pelvic urethra are normal in thickness with a smooth mucosal surface.

Kidneys are normal in size (left kidney 4.7 cm, right kidney measured 4.46 cm) with increased cortical echogenicity. Normal smooth peripheral margination and shape are maintained. There is a normal 1:3 cortex to medulla ratio with appropriate corticomedullary distinction. There is no evidence of pyelectasia, mineral or infarcts observed. Infiltrative disease (infectious, neoplastic, etc.) or nephritis cannot be ruled out but is considered less likely.

Adrenal Glands

Left adrenal gland is normal in size (0.35 cm), shape and overall architecture, echogenicity and echotexture. Visible surrounding vasculature appears normal.

Right adrenal gland is normal in size (0.44 cm), shape and overall architecture, echogenicity and echotexture. Visible surrounding vasculature appears normal.

Spleen

Spleen is subjectively normal in size with a normal smooth capsular contour. Parenchyma is appropriately finely textured and homogenous with normal echogenicity relative to surrounding tissue (hyperechoic to liver). No focal nodules or masses are observed. Splenic vasculature appears normal.

Liver

Liver is subjectively normal in size with normal smooth curvilinear peripheral contour. Parenchyma is appropriately hypoechoic to the spleen in echogenicity and appropriately mildly coarse and homogenous in echotexture. No focal lesions are observed. Visible vasculature and biliary tree appear normal without distension or congestion.

Gallbladder is non-distended in size. The wall is smooth without visible thickening. Luminal contents are primarily anechoic. There is no evidence of cystic or common bile duct dilation.

Gastrointestinal

The visible stomach wall is normal in thickness and layering. The lumen of the stomach is mildly distended with echogenic non-shadowing luminal contents and gas consistent with normal ingesta. There is no evidence of obstruction, foreign material or infiltrative disease. Pyloric outflow tract appears patent.

The visible small intestine demonstrates areas of thick muscularis layer relative to mucosa (disruption of the normal 1:3 muscularis:mucosa ratio). Small intestinal submucosa is slightly irregular, thick and hyperechoic, without evident loss of layering appreciated. The lumen of the small intestine is empty with no evidence of obstruction or foreign material.

The visible colon is normal in wall thickness (< 0.2 cm) and layering. Contents are consistent with normal formed feces and gas.

Pancreas

The observed pancreas appears appropriately isoechoic to surrounding omental fat. Visible capsule is smooth and normal in contour. Visible pancreatic parenchyma is homogenous and unremarkable. There is no visible pancreatic duct dilation. There is no evidence of active peripancreatic inflammation.

Free Abdomen

There is no evidence of peritoneal effusion or apparent lymphadenopathy noted in these images.

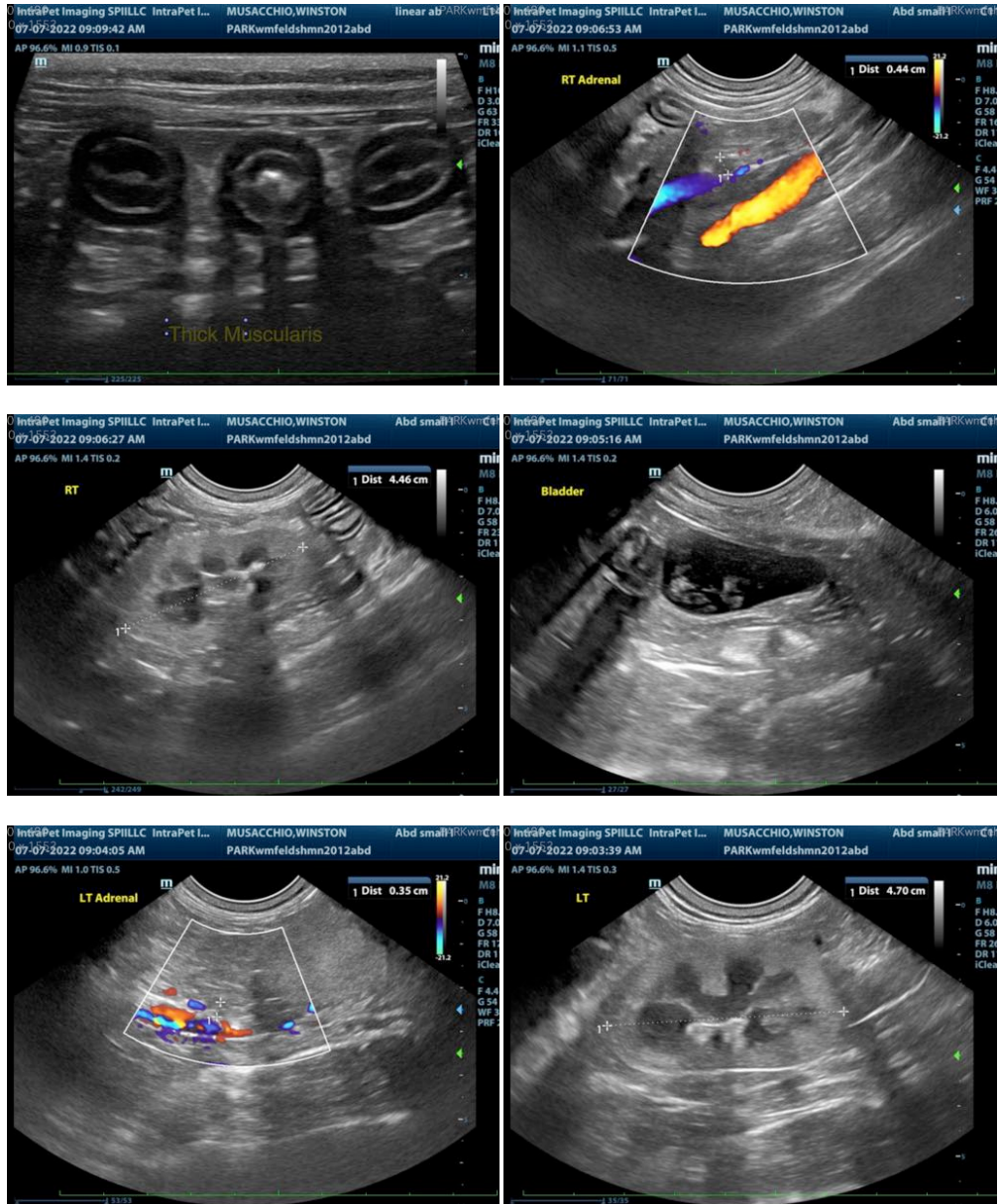
ULTRASONOGRAPHIC FINDINGS

PRIMARY FINDINGS:

- **Inflammatory bowel disease (IBD) pattern** – Thick muscularis has been reported with infiltrative bowel disease including both benign inflammatory disease as well as infiltrative neoplasia such as lymphoma. No aggressive lymphadenopathy, loss of layering, etc. is noted to make lymphoma more probable, but lymphoma cannot be definitively ruled out without tissue sampling.
- **Urinary bladder debris.**

INTERPRETATION OF THE FINDINGS & FURTHER RECOMMENDATIONS

1. Urinalysis and, if indicated based on urinalysis results, urine culture are recommended. If protein is present in an otherwise quiet sediment, protein quantification with a urine protein to creatinine ration is recommended.
2. A gastrointestinal malabsorption panel (including cobalamin, folate, TLI and PLI) to Texas A&M GI Laboratory is recommended for further evaluation of GI and pancreatic function.



The information and recommendations provided are based on the images presented by the referring veterinarian. No evaluation can be communicated regarding pathology that was not visible in the image/video clips provided.

Thank you for this referral. If the clinical or image interpretation does not parallel your findings or if I can be of any further assistance please contact me.

Beth Johnson, DVM DACVIM

Beth.Johnson@SonoPath.com