



**PATIENT**

Layla Kite

**SPECIES**

Canine

**BREED**

Kelpie

**SEX**

Spayed Female

**AGE**

12 Years

**WEIGHT**

20.5 kg

**INTERPRETED BY**

Beth Johnson, DVM  
DACVIM

**IMAGING PERFORMED BY**

Dr. Jolee Stegemoller

**HOSPITAL NAME**

North Idaho AH

**REFERRING VET**

Dr. Jolee Stegemoller

**INVOICE**

39308

**DATE**

7/7/22

**PRESENTING CLINICAL SIGNS**

Work up performed at previous hospital for elevated liver enzymes in Jan/Feb 2022. Patient has really slowed down in the last few months, seems to have polyuria/polydipsia, urinary incontinence and owner was considering euthanasia. Other hospital had recommended ultrasound, so elected to perform to look for possible underlying disease that would support other treatment options or euthanasia. Patient received 1 dose of Proin and 1 dose of Carprofen yesterday and owner reports drastic improvement in attitude and no urinary leakage while sleeping.

Abnormal PE/Chem/CBC/UA Results: Lab Results 1/2022 - ALP 474, ALT 451 2/2022 - ALP 399, ALT 436 7/2022 - UA - USG 1.010, unremarkable otherwise Exam findings: slow to rise, very tense and anxious on examination, no pain on abdominal palpation. Based on interpretation, owner will consider rechecking lab values with coag panel in preparation for FNA of liver and spleen if recommended.

**ULTRASONOGRAPHIC EXAMINATION OF THE ABDOMEN**

**Urinary System**

The urinary bladder is moderately distended with anechoic contents. No masses, inflammatory changes, echogenic sediment or cystoliths are observed. The urinary bladder, trigone and visible pelvic urethra are normal in thickness with a smooth mucosal surface.

The right kidney is normal in size (5.8 cm) and shape with smooth peripheral margination. A normal 1:3 cortex to medulla ratio is maintained. The medulla and cortices are uniform in texture with some mild increased echogenicity and mild loss of corticomedullary distinction. There is no evidence of pyelectasia, mineral or infarcts observed.

The left kidney is normal in size (6.1 cm) and shape with smooth peripheral margination. A normal 1:3 cortex to medulla ratio is maintained. The medulla and cortices are uniform in texture with some mild increased echogenicity and mild loss of corticomedullary distinction. There is no evidence of pyelectasia, mineral or infarcts observed.

**Adrenal Glands**

The right adrenal gland is normal in size (2.7 cm long x 0.83 cm at the cranial pole and 0.50 cm at the caudal pole), shape and contour. Corticomedullary structure is unremarkable. Visible surrounding vasculature appears normal.

The left adrenal gland is normal in size (1.7 cm long x 0.50 cm at the cranial pole and 0.47 cm at the caudal pole), shape and contour. Corticomedullary structure is unremarkable. Visible surrounding vasculature appears normal.

**Spleen**

The spleen is subjectively large in size with subtly scalloped or undulating capsular contour. The head of the spleen is especially round with an emerging homogeneous, isoechoic mass like appearance. Parenchyma is normal in echogenicity with a mildly coarse/heterogenous echotexture. Splenic vasculature appears normal.

**Liver**

Liver is normal to subjectively small in size with slightly undulating or scalloped capsular contour or margins. Patchy ill-defined areas of increased echogenicity are present with reduced visualization of vessels. No overt nodules or masses are observed. Visible vasculature and biliary tree appear normal without distension or congestion.



**PATIENT**

Layla Kite

The gallbladder is moderately distended with anechoic bile as well as suspended and gravity dependent echogenic debris. The wall is smooth without visible thickening. There is no evidence of cystic or CBD dilation. There is no evidence of effusion or inflammation.

**SPECIES**

Canine

**Gastrointestinal**

The stomach wall is normal in thickness (canine < 0.5 cm and feline < 0.4 cm) and layering. The lumen of the stomach is mildly distended with echogenic non-shadowing luminal contents and gas consistent with normal ingesta. There is no evidence of obstruction, foreign material or infiltrative disease. Pyloric outflow tract appears patent.

**BREED**

Kelpie

The visible small intestines are normal in wall thickness and layering (canine duodenum < 0.5 cm and feline duodenum < 0.4 cm; other < 0.3 cm). Small intestinal motility appears adequate (1-3 contractions per min). The lumen of the small intestine is empty with no evidence of obstruction, foreign material or infiltrative disease.

**SEX**

Spayed Female

The visible colon is normal in wall thickness (< 0.2 cm) and layering. Contents are consistent with normal formed feces and gas.

**AGE**

12 Years

**Pancreas**

The pancreatic parenchyma is appropriately isoechoic to surrounding tissue. Visible capsule is smooth and normal in contour. There is no visible pancreatic duct dilation. There is no evidence of active peripancreatic inflammation.

**WEIGHT**

20.5 kg

**Free Abdomen**

There is a scant amount of free fluid between the spleen and the liver.

**INTERPRETED BY**

Beth Johnson, DVM  
DACVIM

There is no apparent lymphadenopathy noted in these images.

**PRIMARY FINDINGS**

- Scalloped spleen – can be associated with benign or malignant infiltrative disease. Common causes include a reactive spleen secondary to immune stimulus or early infiltrative round cell neoplasia such as lymphoma or mast cell tumor.
- Hepatic Fibrosis Pattern – This appearance is most consistent with chronic hepatitis with fibrosis and/or early cirrhosis. These changes can occasionally be seen with resolved past inflammatory episodes and should therefore be interpreted in combination with clinical signs and/or associated laboratory changes (including bile acids).

**IMAGING PERFORMED BY**

Dr. Jolee Stegemoller

**HOSPITAL NAME**

North Idaho AH

**SECONDARY FINDINGS**

- Age related kidney change – This finding is expected/consistent with age-related mild degenerative disease and should be interpreted clinically in combination with laboratory changes.
- Gallbladder debris - Cholecystic debris is of unknown clinical significance. It can be seen with biliary stasis from fasting or illness. Cholecystic debris is not necessarily related to hepatobiliary disease. Echogenic bile is most commonly an incidental finding in dogs and should be interpreted in combination with clinical signs such as nausea, inappetence, cranial abdominal discomfort and/or laboratory changes such as increased ALP and/or increased Tbili.

**REFERRING VET**

Dr. Jolee Stegemoller

**INVOICE**

39308

**DATE**

7/7/22



**PATIENT**

Layla Kite

**SPECIES**

Canine

**BREED**

Kelpie

**SEX**

Spayed Female

**AGE**

12 Years

**WEIGHT**

20.5 kg

**INTERPRETED BY**

Beth Johnson, DVM  
DACVIM

**IMAGING PERFORMED BY**

Dr. Jolee Stegemoller

**HOSPITAL NAME**

North Idaho AH

**REFERRING VET**

Dr. Jolee Stegemoller

**INVOICE**

39308

**DATE**

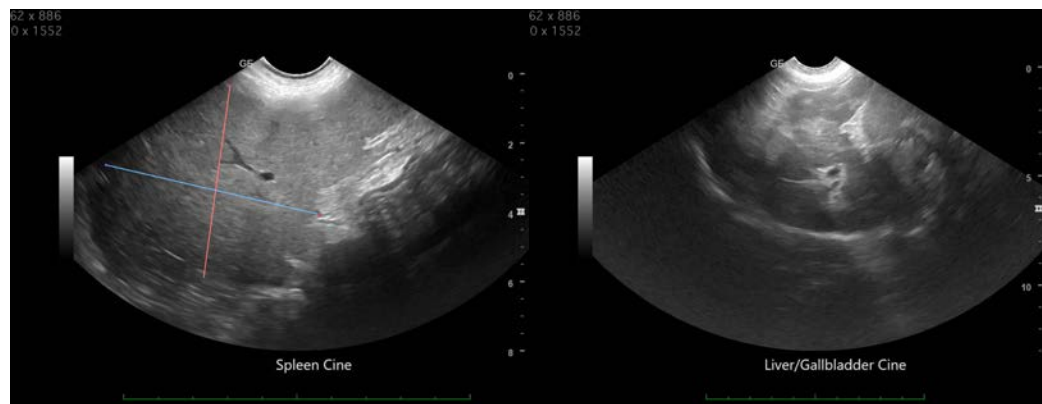
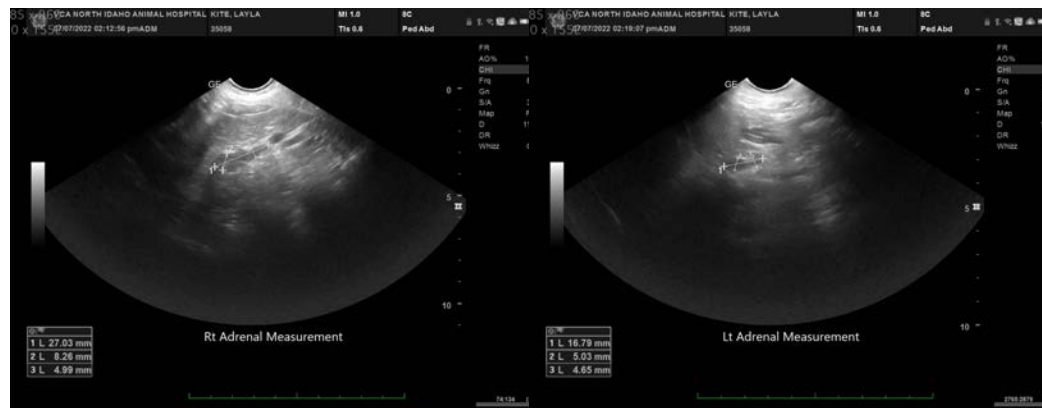
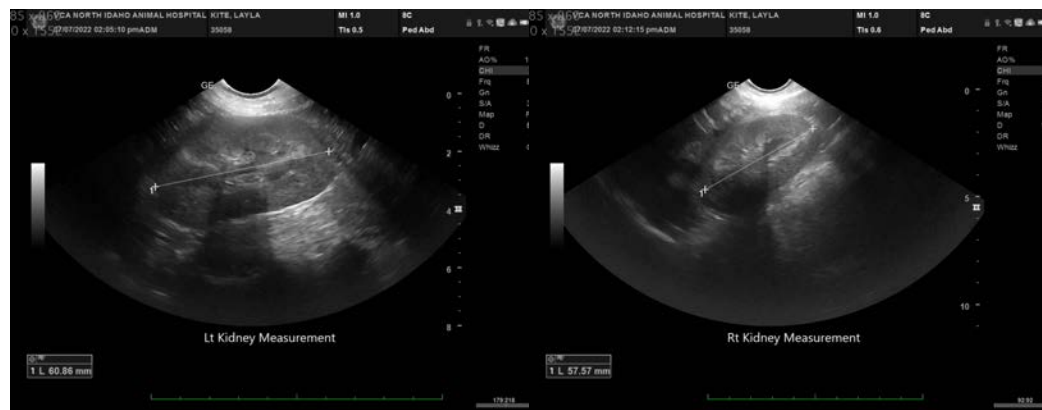
7/7/22

**INTERPRETATION OF THE FINDINGS & FURTHER RECOMMENDATIONS**

The appearance of the liver is concerning for a chronic inflammatory hepatopathy and potentially some early fibrosis/cirrhosis. Therefore, bile acids and a coagulation panel are recommended.

If coagulation status is appropriate, a fine needle aspirate of the spleen +/- the liver is recommended to rule out infiltrative round cell neoplasia.

The reported PU/PD may be related to decreased liver function. Pending bile acid results, if indicated based on previous urinalysis results, urine culture is recommended. If protein is present in an otherwise quiet sediment, protein quantification with a urine protein to creatinine ration is recommended.





**PATIENT**

Layla Kite

**SPECIES**

Canine

**BREED**

Kelpie

**SEX**

Spayed Female

**AGE**

12 Years

**WEIGHT**

20.5 kg

**INTERPRETED BY**

Beth Johnson, DVM  
DACVIM

**IMAGING  
PERFORMED BY**

Dr. Jolee Stegemoller

**HOSPITAL NAME**

North Idaho AH

**REFERRING VET**

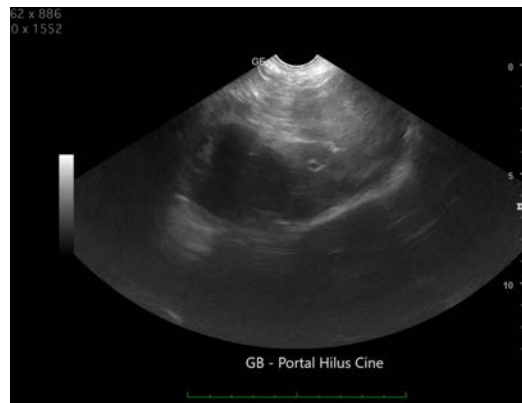Dr. Jolee Stegemoller

**INVOICE**

39308

**DATE**

7/7/22



The information and recommendations provided are based on the images presented by the referring veterinarian/sonographer. No evaluation can be communicated regarding pathology that was not visible in the image/video clips provided.

Thank you for this referral. If the clinical or image interpretation does not parallel your findings or if I can be of any further assistance please contact me.

**Beth Johnson, DVM, DACVIM**  
Beth.Johnson@sonopath.com